https://africanjournalofbiomedicalresearch.com/index.php/AJBR
Afr. J. Biomed. Res. Vol. 27(December 2024); 1761-1768
Research Article

Protective Effect of *Ficus Benghalensis* on Cyclophosphamide Induced Neurotoxicity and Hepatotoxicity in Rats

Kajal [1], Manjula SD[1*], Mohandas Rao KG[2], Shobha Kamath[3], Rucha Dafale[1], Suchetha P Kumar[1], Vasanthalaxmi K Rao[1*]

[1]*Department of Physiology, Kasturba Medical College, Manipal, Manipal Academy of Higher Education, Manipal, Karnataka-576104, India.*
[2] *Department of Anatomy, Department of Basic Sciences, Manipal Academy of Higher Education, Manipal, 576104, Inida*
[3]*Department of Biochemistry, Kasturba Medical College, Manipal, Manipal Academy of Higher Education, Manipal, Karnataka-576104, India.*

Abstract
Cyclophosphamide (CPA) is a medication primarily used in the management and treatment of neoplasms, including multiple myeloma, sarcoma, and breast cancer. This cytotoxic attack of CPA not only targets cancer cells but also affects healthy organ cells, resulting in side effects and toxicity. This systemic toxicity impacts critical organs such as the brain, liver, testis, bladder, heart, kidney, and immune cells. *Ficus benghalensis*, a member of the Moraceae family, consists of flavonoids such as rutin, benghalenosides, delphinidin-3-o-α-L rhamnoside, quercetine-3-galactoside etc. This study aims to investigate whether *Ficus benghalensis* can mitigate the toxicity induced by cyclophosphamide. To assess the protective effects of aqueous extract of *Ficus* benghalensis on cyclophosphamide induced Neurotoxicity and Hepatotoxicity, four experimental groups, consisting of six rats each, were randomly assigned from the total of twenty-four rats. Group I , standard control group, Group II received 100 mg/kg of aqueous leaf extract of *Ficus benghalensis*, Group III received 100 mg/kg of cyclophosphamide, Group IV received 100 mg/kg of aqueous leaf extract of *Ficus benghalensis* and 100 mg/kg of cyclophosphamide. The animals were weighed and sacrificed. The brain and liver were removed 24 hours after the last treatment, stored in 10% formalin at room temperature for histopathological analysis. In the *Ficus benghalensis* and cyclophosphamide treated group, both liver and brain sections exhibited histological characteristics comparable to the control group, indicating a significant preservation of tissue integrity. This improvement may be attributed to the antioxidant properties of *Ficus benghalensis*, which could counteract oxidative stress and cellular damage induced by CPA.

Key words: Cyclophosphamide, *Ficus benghalensis*, Hepatotoxicity, Brain toxicity, Rats

***Author for correspondence: Email:** *vl.upadhya@manipal.edu* , *manjula.sd@manipal.edu*

Received: 25/11/2024 Acceptance: 01/12/2024

DOI: https://doi.org/10.53555/AJBR.v27i3.4527

© 2024 The Author(s).
This article has been published under the terms of Creative Commons Attribution-Noncommercial 4.0 International License (CC BY-NC 4.0), which permits noncommercial unrestricted use, distribution, and reproduction in any medium, provided that the following statement is provided. "This article has been published in the African Journal of Biomedical Research"

Introduction

Cyclophosphamide (CPA) is a drug predominantly employed in the management and treatment of cancers. First synthesized in 1958, it is an oxazaphosphorine alkylating antineoplastic drug (Dabbish et al., 2023). CPA is effective against a broad range of malignancies, including leukemia, lymphoma, breast, lung, prostate, and ovarian tumors (Olayinka et al., 2015). The hepatic microsomal cytochrome P450 mixed-function oxidase system's metabolic activation is a critical component for both the therapeutic and harmful effects of CPA. The products of this metabolism include acrolein and phosphoramide mustard. Phosphoramide mustard is linked to the anti-neoplastic and immunosuppressive actions of CPA. whereas acrolein is linked to its harmful side effects (Alam et al.,2023). CPA induces

cytotoxicity primarily by forming cross-links between DNA strands, which disrupts replication and transcription processes. This damage triggers cell cycle arrest and activates apoptotic pathways, particularly in rapidly dividing cells (Jiang et al.,2020). This cytotoxic attack of CPA not only targets cancer cells but also affects healthy organ cells (Olowe et al., 2024), resulting in side effects and toxicity. Acrolein can alkylate proteins and DNA, leading to cellular damage and dysfunction through cross-linking, which can trigger cell death. The non-selective toxicity of acrolein affects not only cancer cells but also healthy tissues, causing widespread organ damage. This systemic toxicity impacts critical organs such as the brain, liver, testis, bladder, heart, kidney, and immune cells (Famurewa et al., 2023).

Ficus benghalensis, a member of the Moraceae family, is widely cultivated and has numerous religious, cultural, and therapeutic applications, making it one of the most significant species in the *Ficus* genus. This tree is huge, with a canopy that spreads widely. It is abundant throughout South Asia and has many aerial roots that resemble pillars, supporting multiple long transverse branches. All over Nepal, Bangladesh, Bhutan, India, and Pakistan, it is disseminated (Logesh et al., 2023). The genus *Ficus* contains plant parts (roots, bark, leaves, latex, and seeds) that have anti-helminthic (Aswar et al,. 2008), anti-diabetic (Pandit et al., 2010), anti-inflammatory, immunomodulatory (Patil et., 2009), anti-allergic (Taur et al., 2007), anti-cancer, anti-diarrheal (Mukherjee et al., 1998), and antioxidant properties.

The flavonoids such as rutin, benghalenosides, delphinidin-3-o-α-L rhamnoside, quercetine-3-galactoside etc. are present in leaves of *Ficus benghalensis* (Tahir et al., 2024). Flavonoids are clearly established as antioxidants due to their ability to scavenge reactive oxygen species (ROS), a property stemming from their chemical structure. Furthermore, flavonoids can help regulate redox balance by modulating the expression of genes associated with antioxidant enzymes (Kim et al., 2020). The study aims to investigate whether *Ficus benghalensis* can mitigate the toxicity induced by cyclophosphamide. While previous research has explored the protective qualities of *Ficus benghalensis* against other toxins like isoniazid-rifampicin (Parameswari et al.,2012) and streptozotocin (Gayathri & Kannabiran, 2008) and its efficacy in counteracting CPA-induced toxicity remains unclear. Understanding how Ficus *benghalensis* could alleviate CPA-related damage involves examining its antioxidant and anti-inflammatory properties, which might neutralize free radicals and reduce inflammation, thus protecting vital organs and tissues from CPA's harmful effects. The study will assess whether the plant's biochemical mechanisms, such as enhancing oxidative stress responses and preserving organ function, can effectively undo the adverse impacts of CPA, thereby potentially offering a new therapeutic avenue for managing CPA toxicity. To evaluate the effect of aqueous extract of *Ficus benghalensis* on cyclophosphamide induced neurotoxicity by evaluation of brain histology *and* hepatotoxicity *by* analysis of liver histology *in rats.*



MATERIALS AND METHODOLOGY

PREPARATION OF LEAF EXTRACT

Leaves of *Ficus benghalensis* were collected, dried and powdered. The Soxhlet extraction method was used to prepare the aqueous leaf extract of *Ficus benghalensis*. Powdered leaves were weighed in filter paper. Fiter paper was closed and kept in siphon tube. The siphon tube and flask were filled with distilled water and the apparatus was adjusted. The contents were heated at 35 degrees Celsius. The extract was recovered and made a paste by heating in water bath. After that, the paste was kept in a desiccator until needed again. To achieve the required concentration, distilled water was added to the *F. benghalensis* aqueous leaf extract just prior to administration to animals

ANIMALS AND ETHICAL COMMITTEE CLEARANCE

Prior to the experiment commencing, Institutional Animal Ethical Committee clearance IAEC/KMC/57/2023 was acquired. Male Wister rats, aged 90 days, were obtained from the Central Animal Research Facility, KMC, Manipal. The animals were kept in conventional settings, with a temperature of 28°C, a humidity level of 50%, and a light-dark cycle of 12:12. The rats were kept in cages with three per group and

clean rice husk for bedding. Water and regular laboratory food pellets were given to them.

EXPERIMENTAL DESIGN

Four experimental groups, consisting of six rats each, were randomly assigned from the total of twenty-four rats. Group I was the standard control group and was given distilled water. Group II received 100 mg/kg of aqueous leaf extract of *Ficus benghalensis.* Group III received 100 mg/kg of cyclophosphamide. Group IV received 100 mg/kg of aqueous leaf extract of *Ficus benghalensis* and 100 mg/kg of cyclophosphamide. For a duration of 28 days, oral gavage was used to administer aqueous leaf extract of *Ficus benghalensis, and cyclophosphamide was administered intraperitoneally.*

COLLECTION AND STORAGE OF SAMPLE:

The animals were weighed and sacrificed. The brain and liver were removed 24 hours after the last treatment. Half of the brain and part of liver were stored in 10% formalin at room temperature for histopathological analysis. After that, the tissues were exposed to varying degrees of alcohol to induce dehydration. The tissues that had undergone processing were placed in melted paraffin wax, and using a microtome, sections of five micrometer thick were made for slides. Following that, the sections were deparaffinized by passing them through xylene. Subsequently, they were mounted with DPX and stained with haematoxylin and eosin stains. Using a light microscope set to 400x magnification, the mounted sections were examined for histological changes.

RESULTS

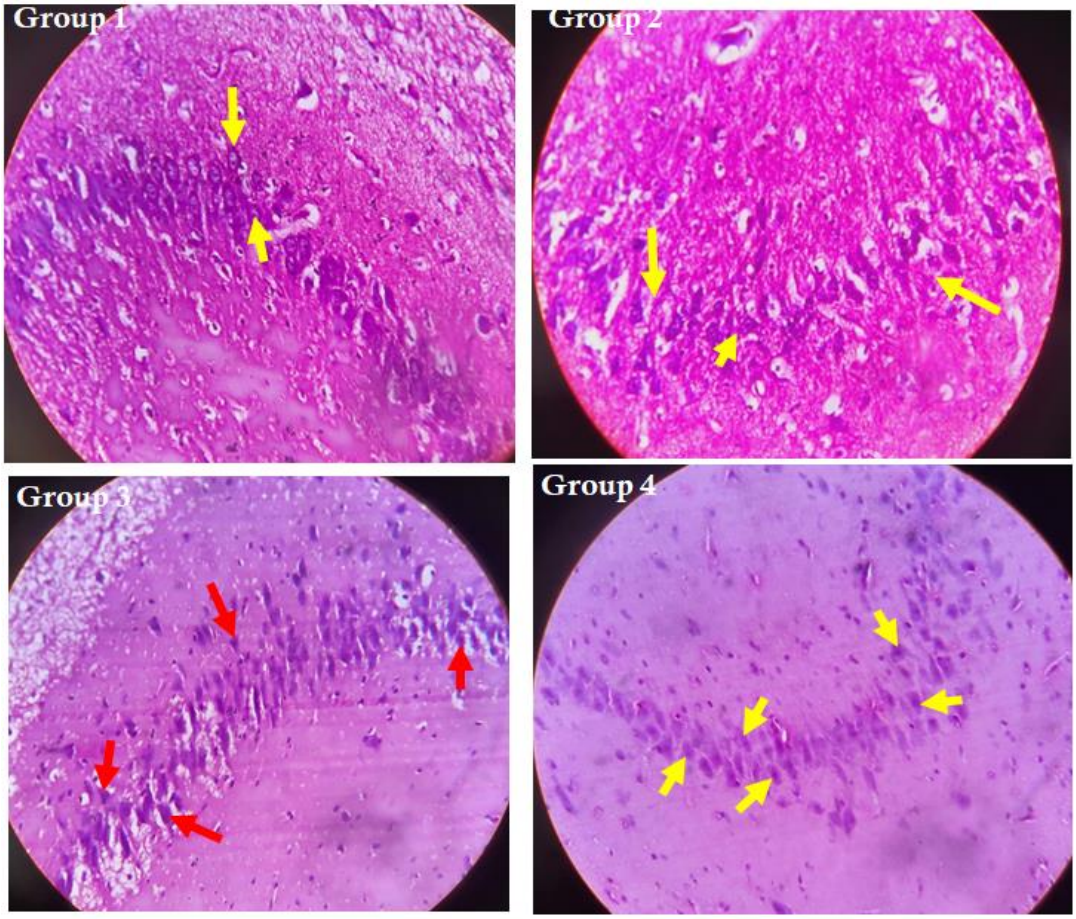

FIGURE 1a: Brain Histology (Hippocampal CA3 region

Figure 1a Legend:

Representative photomicrographs of Hematoxylin and Eosin stained hippocampal CA3 region of group 1 (Control), group 2 (*Ficus benghalensis* extract treated), group 3 (Cyclophosphamide treated) group 4 (*Ficus benghalensis* + Cyclophosphamide treated) rats showing the cell bodies of the pyramidal neurons. [Magnification: 40x10 X]

Qualitative analysis of Hematoxylin and Eosin- stained pyramidal neurons of hippocampal CA3 region:

Hematoxylin and Eosin- stained pyramidal neuronal cell bodies of hippocampal CA3 region of rats of control group (group 1) showed normal healthy neurons with healthy looking cell membrane, clear cytoplasm and prominent nucleus (indicated by yellow arrow). Group 3 (Cyclophosphamide treated) hippocampal CA3 region showed a number of degenerating, flame-shaped, pyknotic cell bodies of pyramidal neurons (indicated by red arrow in figure). The flame-shaped cells which

look deeply basophilic are indicative of karyopyknosis of the neurons of hippocampus. It has been noted that there is a marked increase in the healthy neurons in hippocampal CA3 region of rats belonging to groups 2 (*Ficus benghalensis* extract treated), and 4 (*Ficus benghalensis* + Cyclophosphamide treated) when compared to those of group 3.

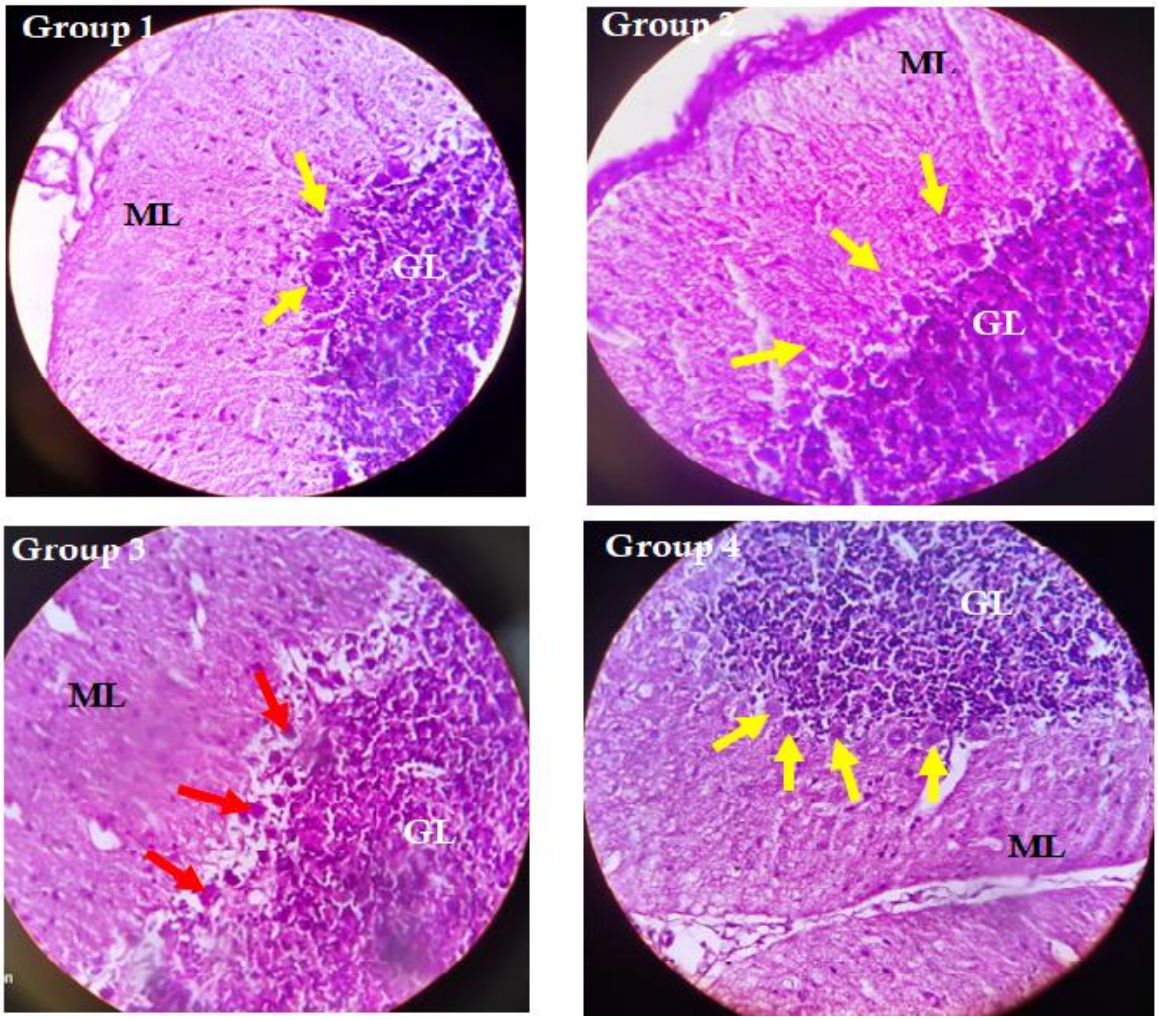

Figure 1b: Cerebellum

Figure 1b Legend: Representative photomicrographs of Hematoxylin and Eosin- stained cerebellar cortex of group 1 (Control), group 2 (FB extract treated), group 3 (Cyclophosphamide treated) group 4 (FB + Cyclophosphamide treated) rats showing molecular (ML), Purkinje cell (Arrows) and granular layers (GL). [Magnification: 40x10 X]

It may be noted that qualitatively, there is not much difference in the molecular and granular layers of the cerebellar cortex between the groups. However, the Purkinje cells in the group 3 showed some features of degeneration and pyknosis (indicated by red arrow). Further, they also looked distorted in their alignment when compared to Purkinje neurons (indicated by yellow arrow) of other groups (Groups 1, 2 and 4)

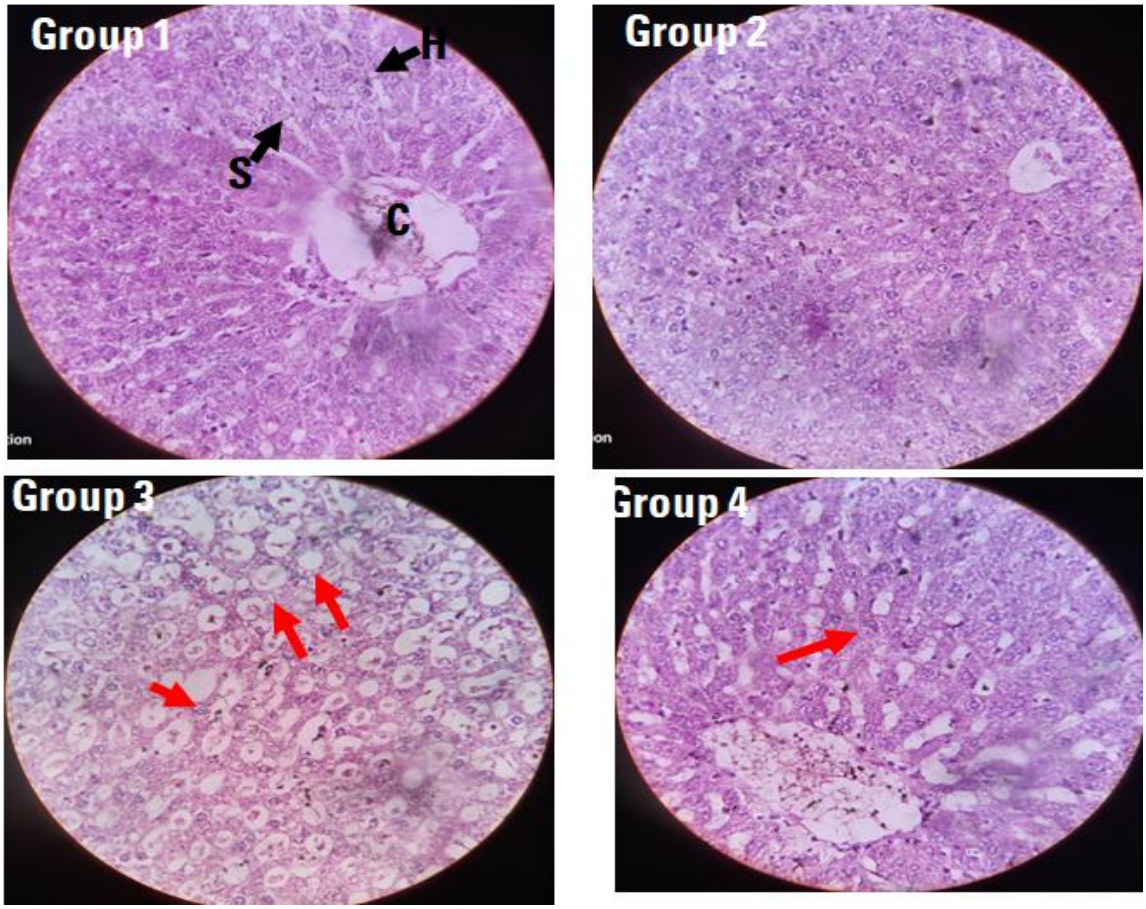

Figure 2: Photomicrographs of H & E- stained liver sections

Figure 2 Legend:
Representative photomicrographs of Hematoxylin and Eosin (H&E) stained sections of liver of group 1 (Control), group 2 (*Ficus benghalensis* extract treated), group 3 (Cyclophosphamide treated) group 4 (*Ficus benghalensis* + Cyclophosphamide treated) rats showing the cell bodies of the pyramidal neurons. [Magnification: 40x10 X]

Qualitative assessment of Hematoxylin and Eosin (H & E) stained liver tissue

H & E -stained sections of liver were observed using light microscope under 40 X magnification. Major components of liver structure; such as hepatocellular architecture and biliary system were observed

Group 1 (Control): Showed normal liver structure with hexagonal hepatic lobules, central vein and typical arrangement of hepatic cords radiating from the central vein. Portal triads consisting of biliary ductule, portal venule and hepatic arteriole were also normal in their location and pattern. Group 3 showed mild inflammatory cell infiltration and features of fatty liver (indicated by red arrow). Groups 2 showed features similar to that of normal control (Group 1). Though the group 4 showed almost normal hepatic structure, some features of mild fatty liver (indicated by red arrow) was seen here.

DISCUSSION

The study highlights the significant impact of *Ficus benghalensis* extract on the hippocampal CA3 region in rats subjected to cyclophosphamide treatment. In the control group, healthy pyramidal neurons exhibited well-defined cellular characteristics, such as intact membranes and prominent nuclei. In contrast, the cyclophosphamide-treated group displayed numerous degenerating neurons characterized by flame-shaped, pyknotic cell bodies, indicative of karyopyknosis—a process associated with cell death and degeneration. Remarkably, groups receiving *Ficus* benghalensis extract, either alone or in combination with cyclophosphamide, showed a notable increase in the population of healthy neurons compared to the cyclophosphamide-only group. This suggests that the extract may exert neuroprotective effects, promoting neuronal health and resilience in the face of cyclophosphamide-induced neurotoxicity.

The study on the methanolic leaf extract of Ficus religiosa (MEFR) assessed its neuroprotective potential against aluminium chloride (AlCl3)-induced neurotoxicity in rats. Aluminium chloride is known for its ability to cross the blood-brain barrier and disrupt the brain's oxidative balance, leading to neuronal cell death. Histological analyses revealed pronounced neurodegeneration in the hippocampal CA3 region of the AlCl3-treated rats, a critical area for memory, susceptibility to seizures, and overall neurodegenerative processes. However, rats administered MEFR at doses of 200 and 300 mg/kg body weight showed notable improvements in both the quantity and quality of neurons in this region. This suggests that MEFR has a protective effect, countering the neurotoxic impact of AlCl3 and potentially mitigating its

deleterious effects on hippocampal function and structure (Massand et al., 2020).

In another study, CPA-treated group, showed an increase in the number of degenerated neurons in the hippocampus. In contrast, the group of rats treated with *Callistemon subulatus exhibited* a marked reduction in degenerated neuron number (Rabie et al., 2023).

The cerebellar cortex analysis revealed that, while the molecular and granular layers remained relatively consistent across all groups, the Purkinje cells in the cyclophosphamide-treated group (Group 3) exhibited notable signs of degeneration and pyknosis, as indicated by the red arrow. These degenerative changes manifested as distorted alignment of the Purkinje neurons, contrasting sharply with the well-organized structure observed in the control (Group 1) and *Ficus benghalensis*-treated groups (Groups 2 and 4). This misalignment suggests that cyclophosphamide may disrupt the normal architecture and function of Purkinje cells, which play a critical role in motor coordination and balance. The preservation of Purkinje cell integrity in the other groups underscores the protective potential of *Ficus benghalensis* extract, suggesting it may counteract the neurotoxic effects of cyclophosphamide and maintain the overall organization of cerebellar neurons.

Previous study done to investigate the protective effects of *Allium sativum* extract against lead-induced cerebellar damage in pregnant rats and their offspring, histopathological examination revealed significant neurotoxic alterations. Lead exposure in the dams and their fetuses resulted in notable Purkinje cell degeneration and impaired development of the fetal cerebellum. However, co-treatment with *Allium sativum* extract significantly mitigated these effects. The extract led to a marked reduction in both blood and cerebellar lead levels, which in turn resulted in a notable improvement in cerebellar architecture.

While examining the effects of *Lycopersicon esculentum* (tomato) extract on rats exposed to electromagnetic fields, notable neuroprotective benefits were observed. Rats treated with the extract following exposure to electromagnetic fields exhibited a significant reduction in caspase-3-labelled Purkinje neurons and granule cells in the cerebellum, indicating fewer signs of apoptosis. Additionally, the extract therapy resulted in decreased degenerative changes in Purkinje neurons. These results suggest that Lycopersicon esculentum extract effectively inhibits apoptosis and neurodegeneration induced by electromagnetic field exposure during both prenatal and postnatal periods, highlighting its potential as a therapeutic agent in mitigating electromagnetic field-induced cerebellar damage (Köktürk et al., 2013).

The histological examination of liver tissue across the groups revealed distinct differences in hepatic structure and integrity. In Group 1 (Control), the liver exhibited a normal architecture characterized by hexagonal hepatic lobules, central veins, and orderly arrangements of hepatic cords radiating outward, along with well-organized portal triads comprising biliary ductules, portal venules, and hepatic arterioles. In contrast, Group 3 displayed mild inflammatory cell infiltration and indications of fatty liver, as highlighted by the red arrow, suggesting potential hepatic stress or damage. Interestingly, Group 2, which received Ficus benghalensis extract, demonstrated features consistent with the normal control group, indicating a protective effect on liver architecture. Meanwhile, Group 4, although showing nearly normal liver structure, presented mild fatty liver features, also marked by the red arrow, suggesting that while the extract mitigated some damage, it may not completely prevent the onset of fatty changes in the presence of cyclophosphamide.

Doustimotlagh et al. reported that post-treatment with *Nasturtium officinale* R. Br successfully preserved normal hepatocyte and sinusoidal architecture, contrasting with the alterations seen in the cyclophosphamide (CPA)-treated group (Doustimotlagh et al., 2020).

In the *Ficus benghalensis* and cyclophosphamide treated group, both liver and brain sections exhibited histological characteristics comparable to the control group, indicating a significant preservation of tissue integrity. This improvement may be attributed to the antioxidant properties of *Ficus benghalensis*, which could counteract oxidative stress and cellular damage induced by CPA. The observed protective effects suggest that *Ficus benghalensis* plays a crucial role in maintaining organ health during pharmacological stress.

Flavonoids in *Ficus benghalensis* act as powerful antioxidants. Antioxidants primarily function by slowing, preventing, or eliminating oxidative damage to target molecules. The extensive mechanisms of flavonoids involve (a) neutralizing free radical species, (b) binding metal ions, (c) inhibiting enzymes linked to free radical production, and (d) promoting endogenous antioxidant activity (Banjarnahor & Artanti., 2015).

Rutin, a flavonoid found in the leaves of *Ficus benghalensis,* is known for its potent antioxidant properties, effectively reducing oxidative stress by diminishing lipid peroxidation and enhancing overall antioxidant activity. Beyond its hepatoprotective effects, rutin has demonstrated a protective influence against doxorubicin-induced memory deficits, suggesting its potential in safeguarding cognitive function during chemotherapy (Ramalingayya et al., 2017). Additionally, studies indicate that rutin exhibits neuroprotective effects in models of streptozotocin-induced diabetes in rats, highlighting its ability to mitigate neurodegeneration (Ola et al., 2015).

CONCLUSION

Additional investigations are essential to fully understand the therapeutic potential of *Ficus benghalensis*. These studies should include evaluating the plant's effects across different parameters and at various time points, which would provide a comprehensive view of its efficacy and safety. Testing various doses and extracts from different parts of the plant is also crucial, as different parts may contain distinct bioactive compounds with varying effects. Furthermore, isolating and identifying the specific bioactive constituents of *Ficus benghalensis* is necessary to pinpoint the compounds responsible for its antioxidant properties. This process would help in developing natural antioxidant agents that are both effective and safe. Understanding these bioactive components can lead to the creation of targeted treatments to prevent or mitigate adverse effects associated with oxidative stress and other conditions. Overall, these steps are vital for translating the plant's potential into practical, scientifically backed therapeutic applications.

SCOPE OF THE STUDY

Further biochemical assessment of brain antioxidants and liver enzymes can provide critical insights into the potential protective effects of *Ficus benghalensis* against cyclophosphamide-induced toxicity. Future studies could explore the specific bioactive compounds within *Ficus benghalensis* responsible for its protective effects, elucidate the underlying mechanisms of action, and assess its efficacy in different animal models or clinical settings. Additionally, research could extend to evaluating the long-term safety and effectiveness of *Ficus benghalensis* as a preventive or adjunctive treatment in chemotherapy regimens. Investigations could also examine the interactions between *Ficus benghalensis* and other common drugs to ensure comprehensive safety profiles and potential synergistic effects.

REFERENCES

Alam M.F., Ajeibi A.O., Safhi M.H., Alabdly A.J.A., Alshahrani S., Rashid H., Qadri M., Jali A.M., Alqahtani S., Nomier Y., Moni S.S., Khalid M., Anwer T.(2023): Therapeutic Potential of Capsaicin against Cyclophosphamide-Induced Liver Damage. J Clin Med. Jan 24;12(3):911. doi: 10.3390/jcm12030911. PMID: 36769559; PMCID: PMC9917381.

Aswar M., Aswar U., Watkar B., Vyas M., Wagh A., Gujar K.N. (2008): Anthelmintic activity of *Ficus benghalensis*. *Int. J. Green Pharm. (IJGP) 2*, 170–172.

Banjarnahor S. D., & Artanti N. (2015): Antioxidant properties of flavonoids. *Medical Journal of Indonesia*. *23*(4), 239–244. https://doi.org/10.13181/mji.v23i4.1015

Dabbish E., Scoditti S., Shehata M.N.I., Ritacco I., Ibrahim M. a. A., Shoeib T., & Sicilia, E. (2023): Insights on cyclophosphamide metabolism and anticancer mechanism of action: A computational study. *Journal of Computational Chemistry*. https://doi.org/10.1002/jcc.27280

Doustimotlagh A. H., Kokhdan E. P., Vakilpour H., Khalvati B., Barmak M. J., Sadeghi H., & Asfaram A. (2020): Protective effect of Nasturtium officinale R. Br and quercetin against cyclophosphamide-induced hepatotoxicity in rats. *Molecular biology reports*, *47*(7), 5001–5012. https://doi.org/10.1007/s11033-020-05556-7.

Famurewa A. C., Asogwa N. T., & Ezea S. C. (2023): Antidiabetic drug sitagliptin blocks cyclophosphamide cerebral neurotoxicity by activating Nrf2 and suppressing redox cycle imbalance, inflammatory iNOS/NO/NF-κB response and caspase-3/Bax activation in rats. *International Immunopharmacology*. *116*, 109816. https://doi.org/10.1016/j.intimp.2023.109816

Gayathri M., & Kannabiran K. (2008): Antidiabetic and ameliorative potential of Ficus bengalensis bark extract in streptozotocin induced diabetic rats. Indian J Clin Biochem. Oct;23(4):394-400. doi: 10.1007/s12291-008-0087-2. Epub 2008 Dec 20. PMID: 23105795; PMCID: PMC3453136.

Jiang M., Wang W., Zhang J., Wang C., Bi Y., Li P., et al. (2020):Protective Effects and Possible Mechanisms of Actions of Bushen Cuyun Recipe on Diminished Ovarian Reserve Induced by Cyclophosphamide in Rats. Front Pharmacol. 11, 546

Kim T.Y., Leem E.Z., Lee J.M., Kim S.R. (2020): Control of Reactive Oxygen Species for the Prevention of Parkinson's Disease: The Possible Application of Flavonoids. *Antioxidants. 9*, 583. https://doi.org/10.3390/antiox9070583.

Köktürk S., Yardimoglu M., Celikozlu S. D., Dolanbay E. G., & Cimbiz A. (2013): Effect of *Lycopersicon esculentum* extract on apoptosis in the rat cerebellum, following prenatal and postnatal exposure to an electromagnetic field. *Experimental and therapeutic medicine. 6*(1), 52–56. https://doi.org/10.3892/etm.2013.1123.

Logesh R., Sathasivampillai S. V., Varatharasan S., Rajan S., Das N., Pandey J., & Devkota, H. P. (2023): Ficus benghalensis L. (Moraceae): A review on ethnomedicinal uses, phytochemistry and pharmacological activities. *Current Research in Biotechnology*. *6*, 100134. https://doi.org/10.1016/j.crbiot.2023.100134

Massand A., Rai R., Rai A. R., Joy T., Murlimanju B., & Marathe A. (2020): Effect of methanolic leaf extract of *Ficus religiosa* on neuronal degeneration: a pilot study in male albino wistar rats. *Indian Journal of Public Health Research & Development*. *11*(2), 685. https://doi.org/10.37506/v11/i2/2020/ijphrd/194888.

Mukherjee P.K., Saha K., Murugesan T., Mandal S., Pal M., Saha B. (1998)**:** Screening of anti-diarrhoeal profile of some plant extracts of a specific region of West Bengal, India. *J. Ethnopharmacol. 60*, 85–89.

Ola M. S., Ahmed M. M., Ahmad R., Abuohashish H. M., Al-Rejaie S. S., & Alhomida A. S. (2015): Neuroprotective effects of rutin in streptozotocin-induced diabetic rat retina. *Journal of Molecular Neuroscience, 56*, 440-448.

Olayinka E.T., Ore A., Ola O.S., Adeyemo O.A. (2015): Ameliorative Effect of Gallic Acid on Cyclophosphamide-Induced Oxidative Injury and Hepatic Dysfunction in Rats. *Med. Sci. 3*,78-92. https://doi.org/10.3390/medsci3030078

Olowe T.G., Oyovwi M.O., Nwangwa K.E., Ohwin E.P., Oghenetega O.B. (2024): Cytotoxic Properties of Cyclophosphamide: A Focus on Its Mechanistic Impacts on Male Gonadal Functions. *J Explor Res Pharmacol*. 9(2):106-115. doi: 10.14218/JERP.2023.00025S.

Pandit R., Phadk A., Jagtap A. (2010): Antidiabetic effect of *Ficus religiosa* extract in streptozotocin-induced diabetic rats. *J. Ethnopharmacol. 128*, 462–466.

Parameswari S. A., Saleem T. S. M., Chandrasekar K. B., & Chetty C. M. (2012). Protective role of Ficus benghalensis against isoniazid-rifampicin induced oxidative liver injury in rat. *Revista Brasileira De Farmacognosia*. *22*(3), 604–610. https://doi.org/10.1590/s0102-695x2012005000009

Patil V., Pimprikar R., Patil V. (2009): Pharmacognostical studies and evaluation of anti-inflammatory activity of *Ficus bengalensis* Linn. *J. Young Pharm. 1*, 49.

Rabie O., El-Nashar H. A., George M. Y., Majrashi T. A., Al-Warhi T., Hassan F. E., & Mostafa N. M. (2023): Phytochemical profiling and neuroprotective activity of Callistemon subulatus leaves against cyclophosphamide-induced chemobrain. *Biomedicine & Pharmacotherapy*. *167*, 115596.

Ramalingayya G. V., Cheruku S. P., Nayak P. G., Kishore A., Shenoy R., Rao C. M., & Krishnadas N. (2017): Rutin protects against neuronal damage in vitro and ameliorates doxorubicin-induced memory deficits in vivo in Wistar rats. *Drug design, development and therapy*, 1011-1026.

Tahir M. M., Rasul A., Riaz A., Batool R., Nageen B., Adnan M., Sarfraz I., Adnan M., Sadiqa A., & Selamoglu Z. (2024): Ficus benghalensis: A plant with potential pharmacological properties from tradition to pharmacy. *Tropical Journal of Pharmaceutical Research*. *22*(11), 2407–2413. https://doi.org/10.4314/tjpr.v22i11.22

Taur D., Nirmal S., Patil R., Kharya M. (2007): Antistress and antiallergic effects of *Ficus bengalensis* bark in asthma. *Nat. Prod. Res. 21*, 1266–1270.