© 2017 Journal of Pharmacy & Pharmacognosy Research, 5 (4), 238-250, 2017
ISSN 0719-4250
http://jppres.com/jppres

Original Article | Artículo Original

Extract of *Salvadora persica* roots attenuates lead acetate-induced testicular oxidative stress in rats

[Extracto de raíces de *Salvadora persica* atenúa el estrés oxidativo testicular inducido por acetato de plomo en ratas]

Gamal A. Soliman[1]; Majid A. Ganaie[1]; Hassan N. Althurwi[1]; Faisal F. Albaqami[1]; Mohammed A. Salkini[2]; Maged S. Abdel-Kader[2]*

[1]Department of Pharmacology, College of Pharmacy, Prince Sattam bin Abdulaziz University, Al-Kharj, Kingdom of Saudi Arabia.
[2]Department of Pharmacognosy, College of Pharmacy, Prince Sattam Bin Abdulaziz University, Al-Kharj, Kingdom of Saudi Arabia.
*E-mail: mpharm101@hotmail.com

Abstract

Context: Lead exerts pathological changes on male mammals. Deleterious effects on testicular tissues may be mediated by oxidative damage and subsequent lipid peroxidation. Medicinal plants can protect against such oxidative stress.

Aims: To determine the protective activity of *Salvadora persica*, against lead acetate (LA) testicular oxidative stress in rats.

Methods: Adult male Wistar rats were allocated into six groups: control group received the vehicle, *S. persica* group received extract (500 mg/kg), LA group was exposed to 0.1% LA in drinking water and three other groups were co-treated with LA plus *S. persica* (125, 250 and 500 mg/kg). Treatments were applied for 60 days. Five days prior to the end of the experiment, male rats in all groups were mated with untreated females.

Results: *S. persica* (500 mg/kg) increased testosterone level and relative weights of testes, cauda epididymis and seminal vesicles in normal rats but did not affect testicular antioxidant parameters and sperm characteristics. Superoxide dismutase, glutathione peroxidase, catalase activities and the level of reduced glutathione were significantly reduced and malondialdehyde was elevated in the testicular homogenate of LA-exposed rats. LA exposure significantly reduced serum levels of testosterone, follicle-stimulating hormone and luteinizing hormone, as well as, sperm characteristics and relative weight of the testes, cauda epididymis, seminal vesicles and ventral prostate. Administration of *S. persica* extract (250 and 500 mg/kg) significantly reduced oxidative stress and protected against LA-exposure effects.

Conclusions: *S. persica* extract exhibited marked protective activity against LA-induced testicular oxidative stress in rats.

Keywords: sex hormones; sperm; testis; toxicity.

Resumen

Contexto: El plomo ejerce cambios patológicos en los mamíferos machos. Los efectos deletéreos sobre los tejidos testiculares pueden estar mediados por daño oxidativo y posterior peroxidación lipídica. Las plantas medicinales pueden proteger contra este estrés oxidativo.

Objetivos: Determinar la actividad protectora de *Salvadora persica* frente al estrés oxidativo testicular de acetato de plomo (LA) en ratas.

Métodos: Ratas Wistar macho adultas se distribuyeron en seis grupos: el grupo control recibió el vehículo, el grupo *S. persica* recibió el extracto (500 mg/kg), el grupo LA fue expuesto a 0,1% de LA en agua potable y otros tres grupos fueron co-tratados con LA más *S. persica* (125, 250 y 500 mg/kg). Los tratamientos se aplicaron durante 60 días. Cinco días antes del final del experimento, las ratas macho en todos los grupos se aparearon con hembras no tratadas.

Resultados: *S. persica* (500 mg/kg) aumentó el nivel de testosterona y los pesos relativos de testículos, cauda epidídica y vesículas seminales en ratas normales, pero no afectó los parámetros antioxidantes testiculares y las características espermáticas. Las actividades de superóxido dismutasa, glutatión peroxidasa, catalasa y el nivel de glutatión reducido se redujeron significativamente y el malondialdehído se elevó en el homogeneizado testicular de las ratas expuestas a LA. La exposición LA redujo significativamente los niveles séricos de testosterona, hormona folículo-estimulante y hormona luteinizante, así como, las características espermáticas y el peso relativo de los testículos, cauda epidídica, vesículas seminales y próstata ventral. La administración de extracto de *S. persica* (250 y 500 mg/kg) redujo significativamente el estrés oxidativo y protegió contra los efectos de la exposición a LA.

Conclusiones: El extracto de *S. persica* mostró una actividad protectora marcada contra el estrés oxidativo testicular inducido por LA en ratas.

Palabras Clave: esperma; hormonas sexuales; testículos; toxicidad.

ARTICLE INFO
Received | Recibido: February 19, 2017.
Received in revised form | Recibido en forma corregida: May 10, 2017.
Accepted | Aceptado: May 21, 2017.
Available Online | Publicado en Línea: May 24, 2017.
Declaration of interests | Declaración de Intereses: The authors declare no conflict of interest.
Funding | Financiación: This study was supported by the Sheikh AbduAllah bin Zaid bin Ghonaim Research Chair in Prophetic Medicine, Developing and Manufacturing Natural Products.
Academic Editor | Editor Académico: Gabino Garrido.

INTRODUCTION

Over the last decades, various reports have shown that environmental exposure to heavy metals could adversely affects the male reproductive organs and leads to increasing in prevalence of infertility (Dorostghoal et al., 2014). Approximately 30% of infertility problem is due to male factors (Isidori et al., 2006). Lead is among the most prevalent toxic environmental metals. It is widely distributed in foods, water, and ambient air (Abdou and Hassan, 2014). Accordingly, exposure to lead and its derivatives is unavoidable. Lead affects various body systems, including the nervous, cardiovascular, and hematological, in addition to male reproductive function. Oxidative stress is a potential mechanism participated in lead poisoning causing reproductive damage in human and animals (Rao et al., 2016). Testes are vulnerable to oxidative stress due to the high level of unsaturated fatty acids and the presence of reactive oxygen species (ROS)-generating systems (Aitken and Roman, 2008). Therefore, it has been supposed that using of compounds with an antioxidant property may be to protect against the damaging effect of lead on different body organs (Shalan et al., 2005). The plants are considered as the main target in the investigation of new drugs of natural origin.

Salvadora persica (family Salvadoraceae) is a popular chewing stick commonly known as siwak or miswak used by Muslims for more than 1000 years (Ahmad and Rajagopal, 2014). Siwak exhibited significant antimicrobial activity against both aerobic and anaerobic bacteria (Ahmad and Rajagopal, 2014). Some reports manifested that *S. persica* contains particular ingredients that appear to have valuable medicinal properties, including antioxidative effects (Ibrahim et al., 2015). This investigation was designed to evaluate the potential protective effect of *S. persica* extract against LA-induced testicular oxidative stress using male Wistar rats as a model.

MATERIAL AND METHODS

Chemicals

Lead acetate (LA) was supplied from Sigma-Aldrich Company (St. Louis, MO, USA). The kits that were used for the measurement of antioxidant enzyme activities were provided from Cayman Chemical Company (Michigan, USA). Monobinde Inc. (California, USA) supplied other kits that were used for estimation of testosterone, FSH and LH. All other chemicals were of analytical grade and obtained from Medox Biotech, Chennai, India.

Plant material

The roots of *Salvadora persica* were purchased from the local market at Al-Kharj city in March 2016. The plant material was identified by Dr. Mohammad Atiqur Rahman, Taxonomist of the Medicinal, Aromatic and Poisonous Plants Research Center (MAPPRC), College of Pharmacy, King Saud University, Riyadh, Saudi Arabia. Voucher specimen (No. 9011) was deposited at the herbarium of this center.

Extraction

The fresh roots of *S. persica* (one kg) were cut manually into small pieces and extracted with 96% ethanol (3 x 5 L) by maceration at room temperature for 48 h each time. The combined extract was evaporated under reduced pressure using rotary vacuum evaporator to give brown aromatic residue. Extract was stored at refrigerator till time of use.

Animals

Mature male Wistar rats (185-210 g b. wt) were obtained from Lab Animal Unit, Pharmacy College, Prince Sattam bin Abdulaziz University and were kept under uniform conditions of temperature and light/dark (12/12 h) cycles, fed with standard rodent food and supplied with water *ad libitum*. The study protocol was approved by the Ethical Review Committee (Protocol No. PHARM-02-11-2016), Pharmacy College, Prince Sattam Bin Abdulaziz University, Al-Kharj, KSA. All experimental procedures, including administration of anesthesia, were carried out under the direction of a laboratory animal veterinarian. Animals were anesthetized with ketamine hydrochloride for blood collection procedures. All possible measures were taken to minimize discomfort of all the animals used in this study.

Acute toxicity

Two groups of rats (n = 6) were used to test the acute toxicity according to OECD-423 guidelines (OECD, 2001). Rats of the 1st group received *S. persica* extract (5000 mg/kg) by oral gavage while the other group (control) received the vehicle (3% v/v Tween 80 in distilled water). Rats were observed for signs of toxicity and/or death during the first 0.5 h and periodically during 24 h, then daily for a total of 14 days.

Selection of doses

No mortalities were observed following oral administration of *S. persica* extract at 5000 mg/kg, and hence 1/40th (125 mg/kg), 1/20th (250 mg/kg) and 1/10th (500 mg/kg) of the maximum dose administered were selected for the present study. The concentration of lead in drinking water was selected based on previously published studies (Ronis et al., 1996; El-Sayed and El-Neweshy, 2010; Dorostghoal et al., 2014).

Grouping of animals and treatment

Mature male Wistar rats (185-210 g body weight) were divided into six groups (n=6). First group (normal control) was provided with the vehicle at 5 mL/kg. Second group received *S. persica* roots extract at 500 mg/kg. The 3rd-6th groups (LA-exposed groups) were allowed to drink water containing 0.1 % LA for 60 consecutive days. The 3rd group was left as LA-control, while the 4th, 5th and 6th groups received the *S. persica* roots extract at 125, 250 and 500 mg/kg, respectively. Administration of the vehicle and test extract was made daily by oral gavage for 60 days.

Mating test

Five days prior to the end of the experiment each male rat was separately caged overnight with two untreated proestrous females. Successful mating was assured by detection of sperms in the vaginal smear in the next morning day. Each female with positive mating was kept under observation. Percentages of mating success and fertility success in addition to male fertility index were estimated.

$$\text{Mating success \%} = \frac{\text{number mated}}{\text{number paired}}\ x\ 100$$

$$\text{Fertility success \%} = \frac{\text{number pregnant}}{\text{number paired}}\ x\ 100$$

$$\text{Mating success \%} = \frac{\text{number pregnant}}{\text{number mated}}\ x\ 100$$

Estimation of sex hormones

At the end of the exposure duration, the rats were weighed and blood samples were withdrawn by retro orbital puncture into sampling tubes. Sera were separated by centrifugation of blood samples at 3500 rpm for 15 min.

Serum level of testosterone was estimated by the method described in the manufacturer's directions. The assay is based on the enzyme-linked immune absorbent assay (ELISA) as described by Chen et al. (1991). The assay kit of testosterone was obtained from Monobinde Inc., California, USA. Serum testosterone concentrations were obtained by correlating the absorbance of the test sample at 550 nm with the corresponding absorbance on the standard curve. Levels of follicle stimulating hormone (FSH) and luteinizing hormone (LH) in serum were estimated using ELISA kits according to Uotila et al. (1981). Assay kits of FSH and LH were supplied by Monobinde Inc., California, USA.

Assessment of testicular oxidative stress markers

Rats were sacrificed and dissected. Specimens from testis were homogenized in 0.15 M KCl solution at 4°C and centrifuged at 10,000 rpm for 15 min at 4°C and the supernatants were stored at –40◦C until analysis.

Activities of the antioxidant enzymes as superoxide dismutase (SOD), glutathione peroxidese (GPx), and catalase (CAT), and levels of reduced glutathione (GSH) and malondialdehyde (MDA) in testicular homogenates were estimated using the corresponding assay kits purchased from Cayman Chemical Company (Michigan, USA) according to the standard procedures in the manufacturer's instructions.

SOD assay utilized nitroblue tetrazolium for detection of superoxide radicals produced by

hypoxanthine and xanthine oxidase. The activity of SOD in the testicular homogenate was expressed as U/mg protein.

In GPx assay, GPx catalyzes the reduction of hydroperoxides, including H_2O_2 by GSH. GPx degraded H_2O_2 in the presence of GSH, decreasing GSH levels. The remaining GSH was then measured colorimetrically using the reaction with 5,5-dithobis-2-nitrobenzoic acid (DTNB). The activity of GPx is expressed as U/mg protein.

CAT assay measures the reaction of the enzyme in the presence of an optimal concentration of H_2O_2. The reaction produced formaldehyde, which was measured colorimetrically with 4-amino-3-hydrazino-5-mercapto-1,2,4-triazole as the chromogen.

In GSH assay, the sulfhydryl group of GSH reacts with DTNB to develop yellow colored 5-thio-2-nitrobenzoic acid. The development of yellow color was monitored at 412 nm on a spectrophotometer. The level of GSH in testicular homogenates is expressed as µmol/g tissue.

The level of MDA was determined using the thiobarbituric acid method based on its reaction with thiobarbituric acid to form thiobarbituric acid-reactive substances. The MDA level is expressed as µmol/g tissue.

Assessment of sperm parameters

The testis were weighed and the caudal epididymis was carefully excised. The epididymal fluid obtained from the caudal epididymis was immediately analyzed. A drop of the epididymal fluid of each rat was mixed with a drop of phosphate-buffered saline at pH 7.4 on a pre-warmed slide and examined quickly for progressive sperm motility. Sperm motility was estimated by light microscopy under a 400× magnification. Assessment of sperm motility was performed by observing three different fields in each sample and mean of the three observations was considered as the final motility outcome.

For determination of sperm count, semen was sucked from the cauda epididymis using a red blood pipette to 0.5 mark. Semen was diluted using warm normal saline to 101 mark. One drop of the diluted semen fluid was added to the Neubauer counting chamber, counted microscopically (Kruss MBL2000, A. Kruss Optonic, Germany) using the magnification of ×40 and results were expressed as 10^6 cells/mL (Sönmez et al., 2005).

Sperm viability was determined according to the method suggested by WHO (1999) involving the use of eosin, which penetrates the membranes of damaged cells. One drop of epididymal fluid was pressed onto a microscope slide, mixed with two drops of eosin 1% and allowed to remain undisturbed for 30 seconds. Then, three drops of 10% nigrosin were mixed with the solution and within 30 seconds, a thick smear was performed in triplicate. Viable sperms appeared colorless whereas non-viable ones exhibited red color. The results were determined microscopically (Hund Wetzlar H600/12, Germany, fitted with digital camera, canon EOS 550D) at ×400 magnification by counting both stained and non-stained sperms and are presented as a percentage (%). A cover slip was applied and two hundred sperms were calculated per animal to measure the morphological abnormalities under oil immersion. The abnormal sperms were calculated in triplicate. Data are shown as a percentage of sperm abnormalities.

Weights of reproductive organs

The reproductive organs (testis, epididymides, seminal vesicle and ventral prostate) were dissected out and weighed (Analytical Balance; Shimadzu AUW220D; Kyoto-Japan; range: 0.1 mg to 220 g). Relative weights of each organ (organ weight/body weight × 100) were calculated.

Histopathological examination of testis

Testis were collected from control and experimental groups, fixed in 10% formalin and processed routinely for paraffin embedding. Slices of 5 µm were obtained with rotary microtome, stained with hematoxylin-eosin (H&E) and examined under a light microscope (Hund Wetzlar H600/12, Germany, fitted with digital camera, canon EOS 550D).

Statistical analysis

Data are presented as mean ± standard error of means (SEM). Results were analyzed by one-way analysis of variance (ANOVA) followed by Dunnett's test to determine the intergroup variability by

using SPSS ver. 14.0. Results were considered to be statistically significant at $p<0.05$.

RESULTS

Acute toxicity test in rats

This study revealed that using of *S. persica* extract at 5g/kg did not result in any demonstrable acute toxic effect or death in rats during 14 days of perception. None of the medicated rats showed restlessness, depression, hyperthermia, and respiratory distress.

Effect of *S. persica* on fertility of normal rats

The nontoxic nature of *S. persica* extract in toxicity study is confirmed by the biochemical data after 60-day medication period in rats (Tables 1-4). Serum FSH and LH of *S. persica*-medicated rats didn't display any significant variations comparable to normal group, while testosterone level was greatly increased (Table 1). No statistically significant differences were noted in SOD, GPx and CAT activities and GSH and MDA levels of testicular homogenate between *S. persica*-treated rats (500 mg/kg) and the control group. Administration of *S. persica* extract (500 mg/kg) for 60 days didn't show any significant alteration in sperm count (55.2 x 10^6/mL), motility (88.8%), viability (91.7%), abnormalities (6.2%) and fertility success (100%) of rats compared to the control group (53.8 x 10^6/mL, 87.3%, 91.5%, 6.7% and 100%, respectively). Moreover, the extract did not affect body weight of rats, whereas the relative weights of testes, epididymides, seminal vesicle and ventral prostate were markedly increased (Table 5).

Table 1. Effect *S. persica* extract on testicular antioxidant profile, glutathione (GSH) and lipid peroxidation (MDA) in the testicular homogenate of normal and LA-exposed male rats.

Groups and treatment	SOD (U/mg protein)	GPx (U/mg protein)	CAT (U/mg protein)	GSH (µmol/g tissue)	MDA (nmol/g tissue)
Normal control	52.6 ± 2.16	3.3 ± 0.15	13.5 ± 0.30	9.8 ± 0.18	41.3 ± 1.36
S. persica (500 mg/kg)	54.1 ± 3.25	3.1 ± 0.13	14.3 ± 0.26	9.9 ± 0.19	38.8 ± 1.94
LA - control (0.1%)	27.2 ± 1.73[a]	1.3 ± 0.12[a]	7.7 ± 0.23[a]	5.7 ± 0.22[a]	97.6 ± 2.55[a]
LA + *S. persica* (125 mg/kg)	32.4 ± 1.85	1.7 ± 0.15	8.4 ± 0.28	6.3 ± 0.21	89.7 ± 2.74
LA + *S. persica* (250 mg/kg)	39.8 ± 1.22[b]	2.4 ± 0.15[b]	10.0 ± 0.29[b]	8.0 ± 0.28[b]	61.5 ± 2.36[b]
LA + *S. persica* (500 mg/kg)	41.7 ± 1.42[b]	2.8 ± 0.19[b]	11.6 ± 0.27[b]	8.9 ± 0.27[b]	50.8 ± 1.46[b]

Values are expressed as mean ± SEM of six animals in each group. [a]Significance compared to normal control group at $p< 0.05$ (Dunnett's test). [b]Significance compared to LA- control group at $p< 0.05$ (Dunnett's test). SOD: superoxide dismutase; GPx: glutathione peroxidase; CAT: catalase.

Table 2. Effect of *S. persica* extract on serum levels of reproductive hormones of normal and LA-exposed male rats.

Groups and treatment	Testosterone (ng/mL)	FSH (mIU/mL)	LH (mIU/mL)
Normal control	2.95 ± 0.07	5.23 ± 0.35	0.73 ± 0.04
S. persica (500 mg/kg)	3.62 ± 0.05[a]	5.20 ± 0.29	0.77 ± 0.05
LA - control (0.1%)	1.34 ± 0.04[a]	3.22 ± 0.28[a]	0.51 ± 0.02[a]
LA + *S. persica* (125 mg/kg)	1.50 ± 0.05	3.75 ± 0.20	0.60 ± 0.05
LA + *S. persica* (250 mg/kg)	2.15 ± 0.08[b]	4.58 ± 0.19[b]	0.68 ± 0.04[b]
LA + *S. persica* (500 mg/kg)	2.34 ± 0.09[b]	4.83 ± 0.16[b]	0.71 ± 0.04[b]

Values are expressed as mean ± SEM of six animals in each group. [a]Significance compared to normal control group at $p< 0.05$ (Dunnett's test). [b]Significance compared to LA- control group at $p< 0.05$ (Dunnett's test). FSH: follicle-stimulating hormone; LH: luteinizing hormone.

Table 3. Effect of *S. persica* extract on semen characteristics of normal and LA-exposed male rats.

Groups and treatment	Sperm cell characteristics (mean ± SEM)			
	Count ($x 10^6$/mL)	Motility (%)	Viability (%)	Abnormalities (%)
Normal control	53.8 ± 1.63	87.3 ± 2.45	91.5 ± 2.83	6.7 ± 0.33
S. persica (500 mg/kg)	55.2 ± 1.45	88.8 ± 2.84	91.7 ± 3.12	6.2 ± 0.27
LA - control (0.1%)	27.5 ± 1.15[a]	45.2 ± 2.81[a]	55.3 ± 2.87[a]	27.3 ± 1.97[a]
LA + *S. persica* (125 mg/kg)	32.3 ± 2.26	52.5 ± 2.74	63.7 ± 3.51	21.9 ± 1.84
LA + *S. persica* (250 mg/kg)	47.8 ± 2.55[b]	76.8 ± 2.59[b]	82.1 ± 3.66[b]	14.8 ± 0.52[b]
LA + *S. persica* (500 mg/kg)	49.2 ± 2.60[b]	82.6 ± 2.35[b]	86.8 ± 3.85[b]	9.6 ± 0.27[b]

Values are expressed as mean ± SEM of six animals in each group. [a]Significance compared to normal control group at $p< 0.05$ (Dunnett's test). [b]Significance compared to LA- control group at $p< 0.05$ (Dunnett's test).

Table 4. Effect of *S. persica* extract on the mating trial of normal and LA-exposed male rats with normal untreated females (mating ratio = 1 male: 2 females).

Groups and treatment	No. of females mated	Mating success (%)	No. of females pregnant	Fertility success (%)	Male fertility index (%)
Normal control	12/12	100.0	12/12	100.0	100.0
S. persica (500 mg/kg)	12/12	100.0	12/12	100.0	100.0
LA - control (0.1%)	5/12	41.66	3/12	25.00	60.00
LA + *S. persica* (125 mg/kg)	6/12	50.00	5/12	41.66	87.5
LA + *S. persica* (250 mg/kg)	11/12	91.66	10/12	83.33	90.90
LA + *S. persica* (500 mg/kg)	12/12	100.0	12/12	100.0	100.0

Data are expressed as numbers and percentage of six males and 12 females.

Table 5. Effect of *S. persica* extract on body and sexual organs weights of normal and LA-exposed male rats.

Groups and treatment	Final body weight (g)	Relative weight (g) of sexual organs (mean ± SEM)			
		Testes	Cauda epididymis	Seminal vesicles	Ventral prostate
Normal control	245.6 ± 6.14	2.14 ± 0.08	0.61 ± 0.03	0.49 ± 0.03	0.29 ± 0.02
S. persica (500 mg/kg)	253.3 ± 5.27	2.58 ± 0.07[a]	0.77 ± 0.02[a]	0.60 ± 0.02[a]	0.30 ± 0.02
LA - control (0.1%)	218.0 ± 6.72[a]	1.47 ± 0.09[a]	0.42 ± 0.02[a]	0.28 ± 0.02[a]	0.16 ± 0.01[a]
LA + *S. persica* (125 mg/kg)	227.2 ± 6.84	1.66 ± 0.06	0.48 ± 0.03	0.34 ± 0.03	0.18 ± 0.01
LA + *S. persica* (250 mg/kg)	239.1 ± 6.17[b]	1.95 ± 0.08[b]	0.55 ± 0.03[b]	0.40 ± 0.03[b]	0.23 ± 0.02[b]
LA + *S. persica* (500 mg/kg)	241.2 ± 6.13[b]	2.07 ± 0.07[b]	0.57 ± 0.03[b]	0.43 ± 0.02[b]	0.27 ± 0.02[b]

Values are expressed as mean ± SEM of six animals in each group. [a]Significance compared to normal control group at $p< 0.05$ (Dunnett's test). [b]Significance compared to LA- control group at $p< 0.05$ (Dunnett's test).

Effect of *S. persica* on fertility of LA-exposed rats

The tested parameters evaluated in male rats exposed to 0.1% LA plus *S. persica* (125 mg/kg) for 60 days were not significantly different from those of LA control group.

Assessment of testicular oxidative stress markers

Table 1 shows the effect of LA exposure either alone or in combination with *S. persica* extract on biochemical variables indicative of testicular oxidative stress in rats. The results indicated that drinking water containing 0.1% LA for 60 days induced oxidative stress with a significant depletion in the activities of testicular SOD (27.2 ± 1.73 U/mg protein), GPx (1.3 ± 0.12 U/mg protein) and CAT (7.7 ± 0.23 U/mg protein) as compared to the normal control (52.6 ± 2.16, 3.3 ± 0.15 and 13.5 ± 0.30 U/mg protein, respectively). In addition, testicular GSH showed a significant decrease (5.7 ± 0.22 µmol/g tissue) while MDA levels significantly increased (97.6 ± 2.55 µmol/g tissue) on LA exposed rats relative to the normal group (9.8 ± 0.18 and 41.3 ± 1.36 µmol/g tissue, respectively). Co-administration of LA plus *S. persica* extract (250 and 500 mg/kg) reduced the oxidative stress, as evidenced by significantly increased activities of SOD, GPx and CAT in testicular tissues when compared with those of LA-exposed rats. In addition, the protective action of *S. persica* on the most potent endogenous antioxidants, GSH was estimated in testicular tissue of rats (Table 1). Treatment with *S. persica* (250 and 500 mg/kg) were found to protect dose-dependently against GSH depletion in the testicular homogenate of LA-intoxicated rats. Further, co-exposure of rats to LA plus *S. persica* for 60 days was capable of decreasing the elevated MDA level in testes, when compared to LA-exposed rats (Table 1).

Effect on sex hormones

Obtained results showed that serum levels of testosterone (1.34 ± 0.04 ng/mL), FSH (3.22 ± 0.28 mIU/mL) and LH (0.51 ± 0.02 mIU/mL) were reduced significantly in LA-exposed rats, compared with normal control group (2.95 ± 0.07 ng/mL, 5.23 ± 0.35 mIU/mL and 0.73 ± 0.04 mIU/mL, respectively). Oral treatment with *S. persica* extract at 250 and 500 mg/kg successfully prevented LA-induced decreases in the levels of testosterone, FSH and LH in serum (Table 2).

Assessment of sperm parameters

The sperm count, sperm motility, sperm viability and sperm abnormality data are provided in Table 3. Rats exposed to 0.1% LA in drinking water for 60 days showed significant decrease in the count (27.5 x 10^6/mL) and the percentages of motility (45.2%) and viability (55.3%) of their sperms in comparison with the normal control group (53.8 x 10^6/mL, 87.3% and 91.5%, respectively). Moreover, the percentage of sperm abnormalities was significantly increased and the majority of spermatozoa showed bent and coiled tails (Fig. 1). In contrast, co-administration of LA plus *S. persica* extract (250 and 500 mg/kg) significantly increased sperm count, motility and viability over those in LA-treated group in a dose-dependent way. The spermatozoa in both groups were found to be of markedly better morphology in comparison to the LA-intoxicated rats.

Mating test

In the current investigation, the fertilizing capability of male rats was markedly decreased following oral exposure to 0.1% LA for 60 days. The fertility success and fertility index of LA-exposed males were reduced (25% and 60%, respectively) as compared to 100% in normal group (Table 4). Significant improvement in the fertility was noted in male rats exposed to LA plus *S. persica* extract (250 and 500 mg/kg) in a dose-dependent fashion. The ability of these male rats to mates was increased as manifested by the number of mated female rats (11/12 and 12/12, respectively) in comparison to 5/12 in LA alone group (Table 4). However the fertility success was 25% in LA-control males, it increased to 83.33 and 100% in rats medicated with LA plus *S. persica* (250 and 500 mg/kg, respectively). Furthermore, the rates of pregnancy in females that mated with male rats exposed to LA plus *S. persica* extract at 250 and 500 mg/kg were increased.

Effect on body and reproductive organ weights

Weights of the body and reproductive organs of the normal and LA-exposed male rats are provided in Table 5. Exposure of rats to LA alone showed a significantly lower weight-gain at the end of the experimental period in comparison to the normal rats. In addition, a marked reduction in relative weight of the testis, epididymis, seminal vesicles and ventral prostate was also found in LA-treated animals compared to normal rats. Conversely, rats exposed to LA plus *S. persica* extract (250 and 500 mg/kg) demonstrated significant increase in their body weight at the end of the experimental period in comparison with those exposed to LA alone. Similarly, relative weights of the testes, cauda epididymis, seminal vesicles and ventral prostate were considerably higher in rats exposed to LA and *S. persica* (250 and 500 mg/kg) in comparison to LA-alone group.

Histopathological examination of testes

The testes of the control group (Fig. 2A) and those treated with *S. persica* at 500 mg/kg (Fig. 2B) for 60 days showed normal histological structure of seminiferous tubules. The testicular tissues of both groups contained a well-organized seminiferous epithelium, demonstrating the normal process of spermatogenesis. LA control group displayed vacuolation and degenerative changes in most seminiferous tubules of the testes with absence of spermatogenic series in tubular lumen. The core of most tubules included spermatogonia only, while others were completely free indicating testicular dysfunction (Fig. 2C). Examination of testicular sections from rats treated with LA plus *S. persica* extract at 125 mg/kg b.wt disclosed a histopathological pattern of damage in most of seminiferous tubules (Fig. 2D). The protective effect of *S. persica* extract against deleterious effect of LA on the reproductive organs of males was confirmed by the histopathological results. *S. persica* extract at 250 mg/kg (Fig. 2E) and 500 mg/kg (Fig. 2F) showed prominent improvement in the testicular tissues of LA-exposed rats represented by reappearance of testicular tubules configuration.

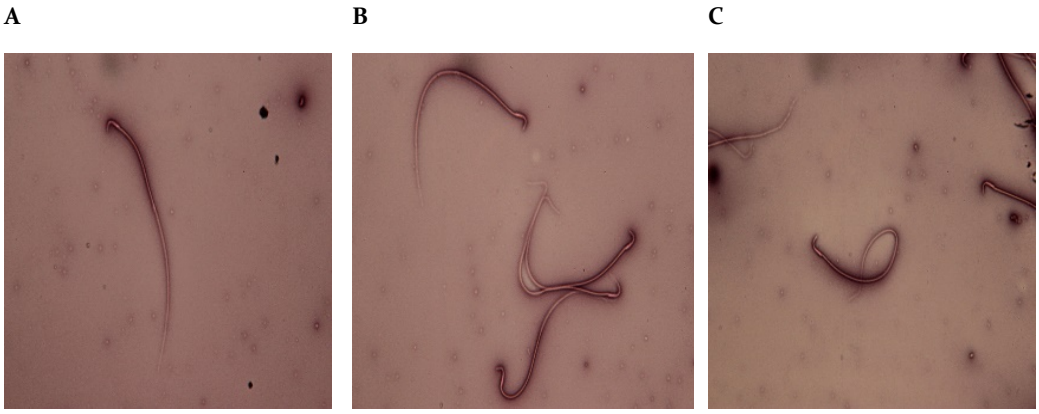

Figure 1. Photomicrographs (x 400) of normal sperm morphology of normal control male rats **(A)** and sperms with bent **(B)** and coiled **(C)** tails of LA control male rats.

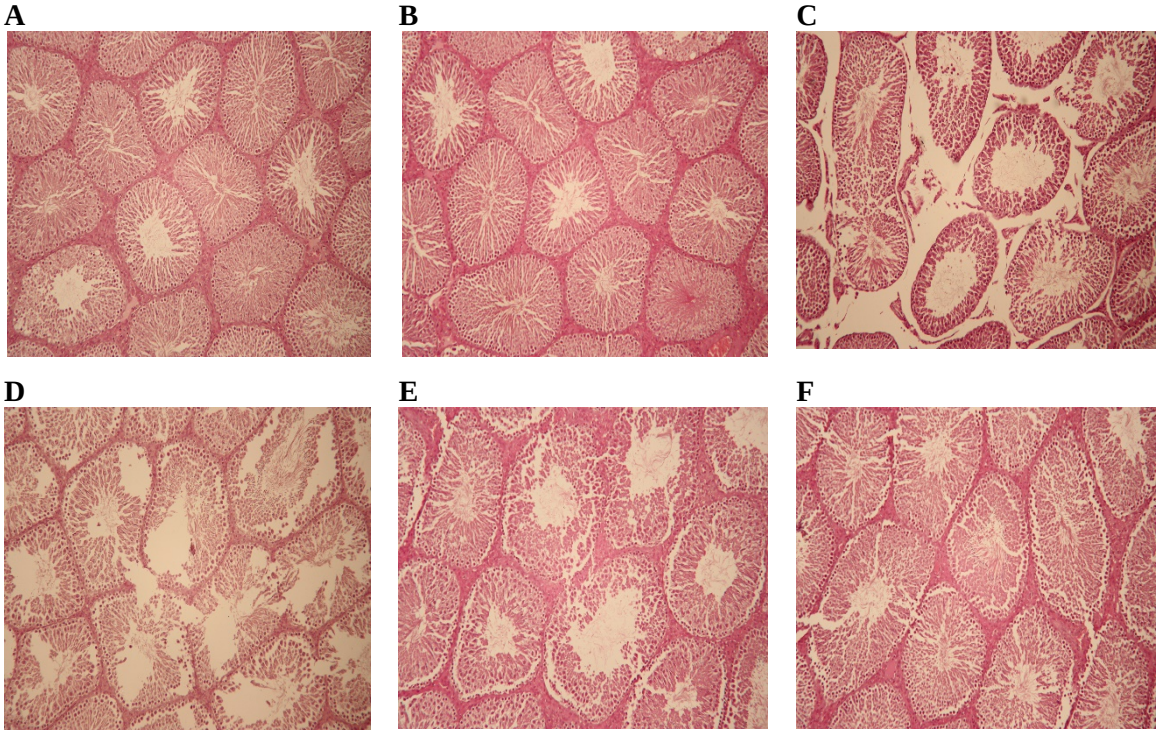

Figure 2. Photomicrographs (x 200, stained with H&E) of cross sections of testis of normal control rats showing well-preserved seminiferous tubules with sequence of spermatogenic cells **(A)**; testis of rats given *S. persica* extract at 500 mg/kg b. wt. for 60 days, showing normal histological structure of most seminiferous tubules **(B)**; testis of LA control rats, showing marked degeneration of most seminiferous tubules with absence of spermatogenic series in tubular lumen **(C)**; testis of LA-treated rats given *S. persica* extract at 125 mg/kg b. wt. for 60 days, showing a histopathological pattern of damage in most of seminiferous tubules **(D)**; testis of LA-treated rats given *S. persica* extract at 250 or 500 mg/kg b. wt., respectively for 60 days, showing normal histological structure of most seminiferous tubules **(E,F)**.

DISCUSSION

Acute oral toxicity in rats

This study suggests that *S. persica* extract administered at 500 mg/kg is not likely to produce toxic effect in rats. In this investigation, the oral LD_{50} value of *S. persica* extract was indeterminable in rats being in excess of 5 g/kg b.wt. Generally, the lower the LD_{50} value, the higher toxic the compound. Thus, the ethanol extract of *S. persica* roots can be classified as non-toxic as compounds having oral LD_{50} higher than 4 g/kg are considered as being safe or practically nontoxic (Kennedy et al., 1986). The safe nature of *S. persica* extract as recognized in acute toxicity study is well supported in male fertility study following medication of normal rats for 60 days. Treatment with 500 mg/kg of *S. persica* extract was well tolerated by rats, since there were no toxic symptoms or deaths noted during the experimental period.

Effect of *S. persica* on fertility of normal rats

Oral dosing of *S. persica* extract at 500 mg/kg for 60 days, did not significantly affects the values of SOD, GPx, CAT, GSH and MDA in the testicular homogenate of normal rats. It did not influence serum FSH and LH; however, a marked elevation in testosterone level observed in the treated rats. The increased serum level of testosterone by the tested extract may attributes to increase of testosterone synthesis by the Leydig cells, since these cells function as the major source of the hormone. The loss of significant adverse effect of *S. persica* extract on the motility, viability and morphology of sperms could probably signify that the extract did not disturb the microenvironment of the epididymis. In addition,

the extract did not affect the fertility success and the body weight gain of animals comparable to normal group suggesting that the general metabolic condition of male rats was in usual range. The relative weights of the testes and accessory glands were increased following *S. persica* medication for 60 days. This result might suggest an increase in the pattern of testosterone secretion. Histological examination of the testes failed to elucidate evidence of treatment-related effects.

Effect of *S. persica* on fertility of LA-exposed rats

The harmful health effects due to the exposure to heavy metals in the environment are a matter of dangerous concern and a global issue. Lead is the most profuse environmental toxic metal (Patra et al., 2011). The main reason in the reproductive toxicity of lead might connect to the excessive generation of ROS and induction of oxidative stress (Rao et al., 2016). However, testes have both enzymatic and non-enzymatic antioxidants to keep themselves against the adverse effects of free radicals generated by LA and other toxicants (Aitken and Roman, 2008). Oxidative stress is usually occurred due to an imbalance between the antioxidant tissue defenses and the production of ROS. Among the various antioxidant enzymes, SOD, GPx and CAT, act as important enzymes in the elimination of free radicals. Monitoring of the activities of the antioxidant enzymes, GSH and LPO in a term of MDA in biological samples are widely used to determine the state of oxidative stress.

The results of this study indicated that the activities of SOD, GPx and CAT enzymes are remarkably reduced in rats exposed to LA at a concentration of 0.1% for 60 days. These results reinforced the other findings that induced decrease in the activities of testicular antioxidant enzymes in LA-treated rats (Mabrouk and Ben Cheikh, 2015). It is known that ROS inhibits the antioxidant enzyme reactions (Rao et al., 2016) so, decrease in the activities of testicular antioxidant enzymes might relate to the excessive generation of ROS by LA. In addition, the current study demonstrated that concurrent administration of *S. persica* and LA significantly neutralized these effects in rats as evidenced by significant increase of their testicular SOD, GPx and CAT activities. Improvement in the activities of these enzymes does provide evidence that *S. persica* protects against the oxidative stress and/or overproduction of ROS by LA.

The thiol binding affinity of lead is a remarkable underlying mechanism responsible for its inhibitory effect on several biomolecules. GSH is the most considerable low molecular weight thiol compound synthesized within the cells. This non-enzymatic antioxidant plays a critical role in protecting cells against oxidative damage (Rao et al., 2016). In this investigation, exposure of rats to LA led to a pronounced depletion of their testicular GSH contents. Depletion of cellular GSH leaves the cell vulnerable to oxidative stress. On the other hand, administration of *S. persica* extract concurrently with LA prevented the decrease in the testicular GSH. Therefore, it seems that the protective mechanism of *S. persica* extract on LA-induced testicular injury is mediated, at least in part, via preserving GSH.

Many heavy metals, including lead, are known to produce ROS and consequently enhance LPO in reproductive organs. MDA is an indirect indicator of LPO in cells due to ROS effects (Bas and Kalender, 2016). ROS cause chain reactions of LPO in the cell membranes, which eventually leads to the generation of the major LPO product, MDA. As an indicator of ROS injury, MDA levels in LA-exposed rats were elevated compared with those in normal group in this present study. In addition, *S. persica* extract ameliorated the increased testicular MDA contents of LA-exposed rats toward normalcy. As a result, we believe that the possible mechanism of testicular protection offered by *S. persica* extract against the deleterious effect of LA is due to its biologically active components that exhibit antioxidant activities. Vinson et al. (1995) attributed the antioxidant activities of *S. persica* to its phenolic and polyphenolic compounds. The phenolic compounds show their antioxidant activity through different mechanisms including their capability to scavenge free radicals and/or activate the antioxidant enzymes (Kulkarni et al., 2004).

Testosterone, FSH and LH are the most important endocrine factors regulating functions of the testes. Testosterone is released by the Leydig cells of the testes in response to stimulation with LH and acts as a major factor that regulates sper-

matogenesis in seminiferous tubules (Smith and Walker, 2014). Moreover, the process of spermatogenesis is improved because of the synergistic impact of FSH and testosterone (McLachlan et al., 1996). Measurement of serum levels of testosterone is an index of Leydig cell function and high or low values correlate well with hypo- or hyper-gonadism. Anjum et al. (2011) reported reduced level of testosterone in serum of rats exposed to LA alone. This finding concurs with results of the current study in which LA alone group exhibited a marked reduction in serum level of testosterone. Reduction in serum level of testosterone might attributed to the testicular oxidative stress induced by LA.

In the concurrent treatment groups, *S. persica* extract at doses of 250 and 500 mg/kg successfully brought back the testosterone level toward the normal control value. These findings could be related to the androgenic activity of *S. persica* extract, which being manifested by the elevation of testicular weight and serum testosterone level in normal rats.

Progressive motility, concentration and morphology of spermatozoa are considered as markers for testicular function. Previous investigations have reported LA as a devastating element for testicular tissues and functions (Bonde et al., 2002). It disrupts the process of spermatogenesis by mechanisms that involved the generation of ROS and induction of LPO (Assi et al., 2016). Subsequently, progressive motility and morphology of spermatozoa may be impaired and sperm cell death may occur depending on ROS levels (Zalata et al., 2004). The obtained results confirmed these findings in rats exposed to LA for 60 days suggesting reduced sperm output and sperm nature. Agarwal and Allamaneni (2006) explained that spermatids and mature sperms are highly susceptible to ROS due to the high content of polyunsaturated fatty acids in their membranes. However, treating LA-exposed rats with *S. persica* extract (250 and 500 mg/kg) increased their epididymal sperm quality, such as sperm count, motility, viability and morphology. The improvement in these sperm parameters following medication of LA-exposed rats with *S. persica* extract could relevant to its capability to protect against the oxidative stress and LPO.

Effective impregnation of an ovum by a sperm depends not only on the count and on morphology of the sperm but is also related to functional parameters. Studies have shown that lead exposure affects the spermatogenesis capability of the testis (Gorbel et al., 2002). Moreover, Landrigan (1990) reported that occupational exposure of men to lead reduces their fertility. In the present study, the reduced testosterone level in serum and impaired quality of spermatozoa after exposure to LA might be responsible for the decreased fertilizing ability of rats. The increased percentage of the fertility success and number of pregnant females following exposure of males to LA + *S. persica* extract (250 and 500 mg/kg) agreed with the amelioration in the quality of spermatozoa. The increased rate of pregnancy is an indicator for the protective effect of *S. persica* extract against gonadotoxic effect of LA. In this respect, Donnelly et al. (1998) mentioned that sperm count and motility are directly consistent with the successful fertilization and pregnancy rates. In addition, Jannini et al. (1999) reported that erection of penis and sexual desire of males depends on concentration of testosterone in blood. Accordingly, the increase in mating success of males exposed to LA plus *S. persica* could be due to increased level of testosterone that improves androgen dependent parameters such as penile erection and sexual desire.

In this investigation, testicular injury following LA exposure was characterized by considerable decreases in the relative weights of the testis, epididymis and accessory sex glands in comparison with untreated control animals. The reduction in the weight of reproductive organs could be attributed to the reduction of androgen availability (Mylchreest et al., 2006). Administration of *S. persica* extract (250 and 500 mg/kg) concurrently with LA to rats induced a marked increase in weights of the testes and accessory sex organs. Testosterone has been shown to be substantial for the growth and normal functions of the male reproductive organs and reports have shown that the level of testosterone is directly correlated with the testicular and epididymal weights (Prins et al., 1991). Thus, the marked elevation in the testicular and epididymal weights could be due to the elevated level of testosterone in blood of LA + extract-medicated groups.

Heavy metals have the ability to pass across the blood testes barrier so, they injure the testes and degenerate the spermatogenic and Leydig cells (Sainath et al., 2011). Current study showed that LA displayed degenerative changes in the seminiferous tubule of testes and impaired the process of spermatogenesis in rats following a 60-day exposure. In addition, LA increased the formation of vacuoles in the testes of rats. Creasy (2001) described vacuoles as an early stage of damage induced by any toxicants. In the present study, the protective effects of *S. persica* extract against deleterious effect of LA on the reproductive organs of males were confirmed by the histopathological results in the testicular tissues of treated animals.

CONCLUSIONS

Salvadora persica seems to provide protective effect on LA-induced testicular damage in rats, possibly owing to its rich constituents of natural antioxidants. The present findings may be of fertility protective significance particularly in the areas where males are chronically exposed to lead.

CONFLICT OF INTEREST

The authors declare no conflict of interest.

ACKNOWLEDGEMENT

This research was supported by the Sheikh AbduAllah bin Zaid bin Ghonaim Research Chair in Prophetic Medicine, Developing and Manufacturing Natural Products.

REFERENCES

Abdou H, Hassan M (2014) Protective role of omega-3 polyunsaturated fatty acid against lead acetate-induced toxicity in liver and kidney of female rats. Biomed Res Int 2014: 435857.

Agarwal A, Allamaneni S (2006) Oxidative stress and human reproduction. In: Singh K, editor. Oxidative stress, disease and cancer. Singapore: Mainland Press; 687-703.

Aitken R, Roman S (2008) Antioxidant systems and oxidative stress in the testes. Oxid Med Cell Longev 1(1): 15-24.

Ahmad H, Rajagopal K (2014) *Salvadora persica* L. (Meswak) in dental hygiene. Saudi J Dent Res 5(2): 130–134.

Anjum MR, Sainath SB, Suneetha Y, Reddy PS (2011) Lead acetate induced reproductive and paternal mediated developmental toxicity in rats. Ecotoxicol Environ Saf 74(4): 793-9.

Assi M, Hezmee M, Haron A, Sabri M, Rajio M (2016) The detrimental effects of lead on human and animal health. Vet World 9(6): 660–671.

Bas H, Kalender S (2016) Antioxidant status, lipid peroxidation and testis-histoarchitecture induced by lead nitrate and mercury chloride in male rats. Braz Arch Biol Technol 59: 1–9.

Bonde J, Joffe M, Apostoli P, Dale A, Kiss P (2002) Sperm count and chromatin structure in men exposed to inorganic lead: Lowest adverse effect levels. Occup Environ Med 59: 234–242.

Chen A, Bookstein J, Meldrum D (1991) Diagnosis of a testosterone secreting adrenal adenoma by selective venous catheterization. Fertil Steril 55: 1202–1203.

Creasy D (2001) Pathogenesis of male reproductive toxicity. Toxicol Pathol 29(1): 64–76.

Donnelly E, Lewis S, McNally J, Thompson W (1998) *In vitro* fertilization and pregnancy rates: The influence of sperm motility and morphology on IVF outcome. Fertil Steril 70: 305–314.

Dorostghoal M, Seyyednejad M, Jabari A (2014) Protective effects of *Fumaria parviflora* L. on lead-induced testicular toxicity in male rats. Andrologia 46: 437–446.

El-Sayed Y, El-Neweshy M (2010) Impact of lead toxicity on male rat reproduction at "hormonal and histopathological hevels". Toxicol Environ Chem 92: 765-774.

Gorbel F, Boujelbene M, Makni-Ayadi F, Guermazi F, Croute F, Soleilhavoup J, el Feki A (2002) Cytotoxic effects of lead on the endocrine and exocrine sexual function of pubescent male and female rats. Demonstration of apoptotic activity. C R Biol 325: 927–940.

Ibrahim M, AL Sahli A, Alaraidh I, Al-Homaidan A, Mostafa E, EL-Gaaly G (2015) Assessment of antioxidant activities in roots of Miswak (*Salvadora persica*) plants grown at two different locations in Saudi Arabia. Saudi J Biol Sci 22(2): 168–175.

Isidori AM, Pozza C, Gianfrilli D, Isidori A (2006) Medical treatment toimprove sperm quality. J Reprod Biomed 12: 704–714.

Jannini EA, Screponi E, Carosa E, Pepe M, Lo Giudice F, Trimarchi F, Benvenga S (1999) Lack of sexual activity from erectile dysfunction with a reversible reduction in serum testosterone. Int J Androl 22: 385–392.

Kennedy G, Ferenz R, Burgess B (1986) Estimation of acute oral toxicity in rats by determination of the approximate lethal dose rather than the LD50. J App Toxicol 6(3): 145–148.

Kulkarni P, Aradhya S, Divakar S (2004) Isolation and identification of radical scavenging antioxidant – punicalagin from the pith and carpellary membrane of pomegranate fruit. Food Chem 87: 551–557.

Landrigan P (1990) Current issues in the epidemiology and toxicology of occupational exposure to lead. Environ Health Perspect 89: 61–66.

Mabrouk A, Ben Cheikh H (2015) Thymoquinone supplementation reverses lead-induced oxidative stress in adult rat testes. Gen Physiol Biophys 34(1): 65–72.

McLachlan R, Wreford N, O'Donnell L, de Kretser D, Robertson D (1996) The endocrine regulation of spermatogenesis: in-

dependent roles for testosterone and FSH. J Endocrinol 148: 1–9.

Mylchreest E, Malley L, O'Neill A, Kegelman T, Sykes G, Valentine R (2006) Reproductive and developmental toxicity of inhaled 2,3-dichloro-1,3- butadiene in rats. Reprod Toxicol 22(4): 613–22.

OECD (2001) OECD Guideline for Testing of Chemicals: Acute oral toxicity-acute toxic class method. Guideline No. 423, Organization for Economic Co-operation and Development, December 17, pp: 1–14.

Patra R, Rautray A, Swarup D (2011) Oxidative stress in lead and cadmium toxicity and its amelioration. Vet Med Int 2011: 457327.

Prins SG, Birch L, Greene GL (1991) Androgen receptor localization in different cell types of the adult rat prostate. Endocrinology 129: 3187–3199.

Rao F, Zhai Y, Sun F (2016) Punicalagin mollifies lead acetate-induced oxidative imbalance in male reproductive system. Int J Mol Sci 17: 1269–1280.

Ronis M, Badger T, Shema S, Roberson P, Shaikh F (1996) Reproductive toxicity and growth effects in rats exposed to lead at different periods during development. Toxicol Appl Pharmacol 136**:** 361–371.

Sainath SB, Meena R, Supriya CH, Reddy KP, Reddy PS (2011) Protective role of *Centella asiatica* on lead-induced oxidative stress and suppressed reproductive health in male rats. Environ Toxicol Pharmacol 32: 146–154.

Shalan M, Mostaza M, Hassouna M, El-Nabi S, El-Refaie A (2005) Amelioration of lead toxicity on rat liver with vitamin C and silymarin supplements. Toxicology 206: 1–15.

Smith LB, Walker WH (2014) The regulation of spermatogenesis by androgens. Semin Cell Dev Biol 30: 2–13.

Sönmez M, Türk G, Yüce A (2005) The effect of ascorbic acid supplementation on sperm quality, lipid peroxidation and testosterone levels of male Wistar rats. Theriogenology 63: 2063–2072.

Uotila M, Ruoslahti E, Engvall E (1981) Relative conversion of arachidonic acid through lipoxygenase and cyclooxygenase pathways by homogenates of diseased periodontal tissues. J Immunol Methods 42: 11–15.

Vinson J, Dabbag Y, Serry M, Jang J (1995) Plant flavonoids, especially tea flavonols, are powerful antioxidants using *in vitro* oxidation model for heart disease. J Agric Food Chem 43: 2800–2802

WHO (1999) Cambridge, United Kingdom: Cambridge University Press. Laboratory Manual for the Examination of Human Semen and Sperm-Cervical Mucus Interactions. 4th, ed.

Zalata A, Ahmed A, Allamaneni S, Comhaire F, Agarwal A (2004) Relationship between acrosin activity of human spermatozoa and oxidative stress. Asian J Androl 6(4): 313–318.

Author contribution:

Contribution	Soliman GA	Ganaei MA	Althurwi HN	Albaqami FF	Salkini MA	Abdel-Kader MS
Concepts or ideas	X					X
Design	X	X	X	X	X	X
Definition of intellectual content	X					X
Literature search		X	X	X	X	
Experimental studies	X	X	X	X	X	X
Data acquisition		X	X	X	X	
Data analysis	X		X			X
Statistical analysis		X		X	X	
Manuscript preparation	X			X	X	X
Manuscript editing	X	X	X		X	X
Manuscript review	X					X

Citation Format: Soliman GA, Ganaei MA, Althurwi HN, Albaqami FF, Salkini MA, Abdel-Kader MS (2017) Extract of *Salvadora persica* roots attenuates lead acetate-induced testicular oxidative stress in rats. J Pharm Pharmacogn Res 5(4): 238–250.