Therapeutic potential of *Datura stramonium* in wound healing and oxidative stress reduction in wistar albino rats

Ananth A[1], Uma devi A[2], Naveenkumar Rajendran[3] and Rajiv Gandhi Gopalsamy[4]

[1]Department of Microbiology, Thanthai Hans Roever College (Autonomous), Perambalur. Tamilnadu. India.
[2]Department of Microbiology, Dhanalakshmi Srinivasan College Arts & Science for Women (Autonomous), Perambalur. Tamilnadu. India.
[3]University of Wisconsin-Madison, USDA Forest Products Laboratory Madison, WI-53706. United States.
[4]Division of Phytochemistry and Drug Design, Department of Biosciences, Rajagiri College of Social Sciences, Kochi, Kerala.
Correspondence to Author:
Dr.Ananth A, Department of Biotechnology, Thanthai Hans Roever College (Autonomous), Perambalur. Tamilnadu. India

Received: Dec 15, 2025 Accepted: Jan 11, 2026 Published: Jan 12, 2026

Abstract---- In this study, we evaluated the wound healing and in-vivo antioxidant potential of *Datura stramonium* (Linn) leaf extracts in rats. The leaves were extracted and tested for their wound healing activity using experimentally induced wounds following approved protocols. Serum samples were analyzed to assess in-vivo antioxidant activity. All formulations of the plant leaf extracts significantly reduced the period of epithelialization compared to the control group. Additionally, the treatments markedly decreased wound contraction relative to control. The extracts demonstrated notable antioxidant activity, evidenced by reduced levels of lipid peroxidation (LPO) and increased levels of superoxide dismutase (SOD), catalase, and glutathione (GSH) in response to oxidative stress. These results indicate that the ethyl acetate extract of *D. stramonium* leaves may offer therapeutic benefits in promoting wound healing, showing superior efficacy compared to other plant extracts.

Keywords---- *Datura stramonium leaves; Wound healing; Medicinal plants; In-vivo antioxidant activity; Wound contraction*

1. INTRODUCTION

A wound is defined as a disruption in the continuity of the skin or mucous membrane. Wounds are generally classified into three types: acute (e.g., cuts, burns), chronic (e.g., diabetic foot ulcers, pressure ulcers), and surgical wounds. They may arise from trauma, surgery, infection, or underlying diseases such as diabetes and vascular disorders. Chronic wounds affect approximately 1–2% of the global population, with diabetic foot ulcers impacting over 400 million people worldwide, and pressure ulcers affecting more than 2.5 million individuals in the United States alone. Surgical site infections occur in approximately 3–5% of surgical procedures globally. Although synthetic wound dressings may be less expensive initially, their long-term costs and potential drawbacks—such as delayed healing and increased risk of infection—can outweigh their benefits. In contrast,

natural or biological wound dressings may promote faster healing, reduce infection risk, and provide better moisture management, making them a more cost-effective option over time [1].

The modern medical system primarily focuses on alleviating symptoms and reducing disease burden, but often does little to address the root cause of illness. Modern medicines can act as a double-edged sword: patients must recover not only from the disease itself but also from the adverse side effects of the drugs. While modern medicine may provide

temporary relief, it rarely offers a complete cure, and the disease often reappears in a different form or at a later time. Additionally, prolonged use of these medicines can lead to nutritional deficiencies by depleting the body's natural reserves. The underlying cause of many diseases is often the accumulation of toxins in the body, resulting from factors such as emotional stress, unhealthy diet, and lack of physical activity. Conventional drugs can further exacerbate toxicity at a time when the body's ability to cope is already compromised. Therefore, healing through natural remedies and preserving this traditional knowledge for future generations is of great importance [2].

Phytotherapeutics refers to the use of plant-derived compounds or extracts for therapeutic purposes, including wound healing. These natural agents exhibit antimicrobial properties, helping to reduce the risk of infection and maintain a clean wound environment. Phytotherapeutics also possess anti-inflammatory activity, which accelerates wound healing and minimizes tissue damage. By neutralizing free radicals, they reduce oxidative stress, further supporting the healing process. Additionally, phytotherapeutic compounds can stimulate cell proliferation, differentiation, and migration, thereby promoting tissue repair and regeneration. They are also known to enhance collagen synthesis, which is essential for wound strength and structural integrity [3].

Phytotherapeutics, being derived from natural sources, generally pose a lower risk of adverse reactions and promote biocompatibility. They are often more affordable than conventional treatments, making them an attractive option for wound care. Phytotherapeutics can act on multiple pathways involved in wound healing, providing a comprehensive approach to tissue repair. Their natural origin and favorable safety profile often improve patient acceptance, adherence, and treatment outcomes. Additionally, the use of phytotherapeutics can reduce dependence on antibiotics, thereby minimizing the risk of antibiotic resistance [4].

.

Healing is a vital survival mechanism and represents the body's effort to restore normal structure and function. Wound healing is the physiological response to injury, which may occur through regeneration or repair. In the skin, the dermis primarily participates in repair, whereas the epidermis mainly undergoes regeneration; the combined response of these layers to injury is collectively termed wound healing [5]. This process involves continuous cell-to-cell and cell-to-matrix interactions, allowing coordinated tissue restoration. The fundamental principles of wound healing include minimizing tissue damage, ensuring adequate tissue perfusion and oxygenation, providing proper nutrition, and maintaining a moist wound environment to restore anatomical continuity and functional integrity. The efficiency of wound healing can be improved by reducing the time required for repair and by minimizing complications that may hinder the process [6].

Datura stramonium, commonly known as thornapple, angel's trumpet, jimson weed, or moonflower, belongs to the Solanaceae (nightshade) family. Although it is believed to have originated in the Americas, it is now widely distributed across the world [7]. *Datura stramonium* is widespread, with higher abundance in temperate, tropical, and subtropical regions. For centuries, it has been used in traditional medicine to alleviate asthma symptoms and as an analgesic during surgical procedures or bone-setting. The plant is also a potent hallucinogen and deliriant, traditionally employed for the intense visions it induces [8]. However, the tropane alkaloids responsible for both its medicinal and hallucinogenic properties are highly toxic; doses only slightly above the therapeutic range can be fatal, and careless use often leads to hospitalizations or death. Leaf extracts are taken orally to treat asthma and sinus infections, while stripped bark is applied externally to manage swellings, burns, and ulcers [9].

The leaves of *Datura stramonium* have been traditionally used to relieve headaches. The vapor from an infusion of the leaves is employed to alleviate arthritis-related conditions, such as rheumatism and gout. Burning the leaves produces smoke that has been used to treat respiratory ailments, including asthma and bronchitis. Ethanol extracts of *D. stramonium* leaves exhibit acaricidal, repellent, and oviposition-deterring properties against mites, as well as repellent activity against mosquito larvae [10]. Additionally, the leaves have been used to manage cardiovascular issues, such as palpitations and hypertension, and leaf juice is applied for the treatment of earaches. Poultices made from *D. stramonium* leaves are traditionally used to treat boils [11]. *Datura stramonium* Linn exhibits significant anti-inflammatory and antimicrobial activity, attributed to its rich and diverse content of flavonoids and phenolic compounds. Traditionally, it has been used to treat painful wounds and sores. The plant is also applied as a poultice for the management of fistulas, abscesses, and wounds, as well as for alleviating severe neuralgia [12]. The present study was undertaken to optimize and evaluate the in vivo wound healing potential of various leaf extract formulations of *Datura stramonium* Linn. as a mono-herbal composition.

II. MATERIALS AND METHODS

A. Animal Selection

Healthy adult male albino Wistar rats were procured from the Central Animal House, KMCH College of Pharmacy, Coimbatore, for the study. The animals weighed between 100–200 g and were 8–10 months old. At the beginning of the experiment, the rats were housed in groups of eight per cage under controlled environmental conditions (12 h light/12 h dark cycle, temperature-controlled room), with free access to standard pellet diet and tap water ad libitum.

All experimental procedures were carried out in accordance with ethical guidelines for the care and use of laboratory animals and were approved by the Institutional Animal Ethical Committee (IAEC) [Approval No.: IAEC/KMCH/07/2015–2016, dated 16/2015].

B. Preparation of simple ointment

Fusion Method

Melt ingredients with higher melting points (e.g., hard paraffin, cetostearyl alcohol) in a water bath. Add lower melting point substances (e.g., wool fat, soft paraffin). Stir until homogeneous. Allow to cool with continuous stirring to prevent separation. Incorporate wound-healing agent (if heat-labile, add during cooling) [13].

C. Preparation of Extract

Six groups of Wistar rats (eight animals per group) were used for both excision and burn wound models, which are grouped and discussed separately. The different extracts of *Datura stramonium* (2%)—namely ethanol extract (DSEE), chloroform extract (DSCE), hexane extract (DSHE), and ethyl acetate extract (DSEAE)—were prepared by dissolving the respective extracts in distilled water [14].

D. Experiment Protocol of Wound Model

- Group 1 (Control): Wound without treatment.
- Group 2 (Standard): Wound treated with simple ointment base.
- Group 3 (Test I): Wound treated with *Datura stramonium* ethanol extract ointment (DSEE, 2%).
- Group 4 (Test II): Wound treated with *Datura stramonium* chloroform extract ointment (DSCE, 2%).
- Group 5 (Test III): Wound treated with *Datura stramonium* hexane extract ointment (DSHE, 2%).

- Group 6 (Test IV): Wound treated with *Datura stramonium* ethyl acetate extract ointment (DSEAE, 2%).

All formulations were applied topically once daily for 21 days or until complete epithelialization, whichever occurred earlier [15].

E. Excision Wound Model

The animals were anaesthetized with diethyl ether and placed on the operation table in their natural position. A square-shaped excision wound measuring approximately 1.5 cm in width and 0.2 cm in depth was created on the depilated, ethanol-sterilized dorsal thoracic region of each rat. Male albino Wistar rats weighing 110–150 g were randomly divided into six groups, with eight rats in each group [16].

Wound contraction was evaluated by tracing the wound margins on transparent sheets at regular intervals (days 1, 3, 5, 7, 9, 11, 13, and 15). Parameters such as wound contraction percentage, scar area, and time required for complete epithelialization were recorded [17], [18].

F. Burn Wound Model

A partial-thickness burn wound model was employed according to standard guidelines. Briefly, rats were anaesthetized with ketamine (100 mg/kg, i.m.), and the dorsal hair was clipped. A burn wound was created by carefully pouring molten wax (80 °C) into a metal cylinder placed on the shaved dorsal surface at the nape of the neck. After recovery from anaesthesia, the animals were housed individually and maintained under standard laboratory conditions in accordance with good laboratory practice (GLP) norms [19], [20], [21].

G. Assessment of Excision and burn wound healing
Non-invasive longitudinal assessment
Standardized photography

Photograph each wound at each time point with a high-resolution camera or smartphone. Place a rigid ruler or a QR/scale marker in the same plane as the wound in every image to allow scale calibration. Maintain constant distance and lighting or use an imaging box [22].

Wound area measurement (planimetry)

Measure wound area from images using ImageJ (free), or a validated smartphone app / digital planimetry tool. Record the initial wound area on day 0 (A_0) and area at time t (A_t). Automated segmentation tools reduce operator error and speed up analysis [23], [24],

$$\text{Wound contraction (\%)} = \frac{A_0 - A_t}{A_0} \times 100$$

H. Time to complete epithelialization

Define epithelialization time as the number of days from wounding to the day the scab falls off without raw wound remaining (or when the wound bed is completely re-epithelialized on inspection). Record the date for each animal [25], [26].

Biochemical and biochemical-histological end-points

I. Tissue sampling schedule

For invasive assays, sacrifice subsets of animals (e.g., n = 3 per group) on pre-set days (commonly day 7 and day 14 or day of complete epithelialization) to obtain wound tissue for biochemical and histological analyses. Collect adjacent unwounded skin as internal control.

J. Hydroxyproline assay (collagen content)

Dry wound tissue (weigh, dry at 50–60 °C till constant weight), hydrolyze in 6 N HCl, and assay hydroxyproline colorimetrically (standard protocols). Express hydroxyproline content as μg hydroxyproline/mg dry tissue, a surrogate for collagen deposition and maturation. Recent wound studies routinely include hydroxyproline as a primary biochemical endpoint.

K. Histopathology & scoring

Tissue collection and fixation

Euthanize animal according to approved protocol. Excise a representative portion of the wound including adjacent normal skin (include full thickness where relevant). Immediately place tissue in 10% neutral buffered formalin (NBF) at a tissue: fixative volume ratio of 1:10 (v/v). Aim to trim tissue to ≤5 mm thickness so fixative penetrates rapidly. Fixation time: 24–48 hours at room temperature (small skin pieces usually 24 h; larger samples up to 48 h). Do not over-fix >72 h if possible for antigen preservation.

Preparation note: 10% NBF ≈ 4% formaldehyde (commercial "10% formalin" is ~37–40% formaldehyde stock — follow lab SOPs for correct dilution) [27], [28].

Tissue processing (routine paraffin)

After fixation, rinse briefly in running tap water (10–30 min) if required to remove excess formalin. Trim and place fixed samples into labelled tissue cassettes. Process in an automated tissue processor or manually using these steps (approx. times for skin):

- 70% ethanol — 1 × 30 min
- 80% ethanol — 1 × 30 min
- 95% ethanol — 2 × 30 min
- 100% ethanol — 2 × 30 min (or 2 × 1 h)
- Xylene (or substitute) — 2 × 30 min (clearing)
- Paraffin wax (56–58 °C) — 3 × 30–45 min (infiltration)

Embed tissues in paraffin blocks with desired orientation so wound surface is vertical and sections show full epidermis → dermis → subcutis [29].

Sectioning and mounting

Trim blocks and cut 4μm thick sections on a microtome. Float sections on a 45–50 °C water bath to remove wrinkles, pick up on clean glass slides (optionally coated slides to improve adhesion). Dry slides on a slide warmer (37–60 °C) for 30–60 min or overnight at 37 °C.

Deparaffinization and rehydration

1. Xylene — 2 × 5 min (or xylene substitute per manufacturer)
2. 100% ethanol — 2 × 3 min
3. 95% ethanol — 1 × 2 min
4. 70% ethanol — 1 × 2 min
5. Rinse in running tap water for 2–5 min (or distilled water) — slides are now ready for H&E.

Hematoxylin & Eosin (H&E) staining (typical times; adjust by reagent)

Hematoxylin (Harris or Mayer's): 3–8 min (check stain intensity). Rinse in running tap water 1–2 min. Differentiate if needed in 0.3% acid alcohol (brief dip), then rinse. Blueing: immerse in alkaline water (tap water or 0.2% ammonia water) 30–60 s. Rinse in

running tap water 1–2 min. Eosin Y: 1–3 min (shorter if concentrated). Dehydrate through graded ethanols (70% → 95% → 100%), clear in xylene (2 × 3–5 min), and mount with DPX and coverslip.

Microscopic evaluation & scoring

Examine slides under light microscope (×4, ×10, ×40 objectives). Record / score parameters relevant to wound healing: re-epithelialization, epidermal thickness, presence/degree of inflammatory cell infiltration (neutrophils, macrophages), granulation tissue formation, neovascularization, collagen deposition/maturation, edema, necrosis, and foreign material. Use blinded scoring (two independent observers) where possible and record scoring system (e.g., 0 = absent, 1 = mild, 2 = moderate, 3 = severe) [30].

L. Oxidative stress & inflammatory markers

Serum samples were collected for antioxidant assays. To evaluate the antioxidant activity, rats were divided into two groups: control and experimental. Experimental rats received 1.25 mL of the leaf extract, while control rats received DMSO. A 10% tissue homogenate was prepared in 0.15 M KCl and centrifuged at 8000 rpm for 10 minutes. The resulting cell-free supernatant was used for the following assays:

- Lipid peroxidation (LPO): Measured by determining thiobarbituric acid reactive substances (TBARS) levels.
- Reduced glutathione (GSH): Assessed to evaluate endogenous antioxidant status.
- Catalase (CAT) activity: Determined using standard enzymatic methods.
- Superoxide dismutase (SOD) activity: Evaluated according to established protocols.
- Vitamin C and total protein levels: Measured to assess overall antioxidant capacity and protein content.

All assays were performed using standard, validated techniques [31].

M. Statistical Analysis

The results are presented as mean ± standard error (SE) for each group (n = 6). Differences between groups were analyzed using one-way analysis of variance (ANOVA), followed by appropriate post-hoc tests to determine pairwise significance. A p-value < 0.05 was considered statistically significant [32].

III. RESULTS

Normal wound healing occurs in three distinct phases: inflammation, proliferation, and remodeling. This process relies on adequate local blood circulation as well as the synthesis and deposition of collagen. Conventional approaches for managing chronic or complicated wounds include debridement, irrigation, antibiotics, tissue grafts, proteolytic enzymes, and corticosteroids. However, these methods are often associated with significant limitations and adverse effects [33].

Datura stramonium contains bioactive components that play a crucial role in wound repair, including vitamin C, amino acids, and vitamin E. Vitamin C, a fat-soluble antioxidant, supports the stabilization of lysosomal enzymes essential for collagen synthesis and helps prevent free radical–induced cross-linking, which can impair normal wound healing.

A. Effect of Datura stramonium *extracts on Excision Wound Healing*

The wound healing activity of the extracts, evaluated using the excision wound model, is presented in Figures 1 and 3. Treatment with the ethyl acetate fraction of the methanolic extract of *Datura stramonium* (DSEAE) and the chloroform extract demonstrated a markedly faster rate of wound contraction compared with the control groups. Notably, the

groups treated with the standard paraffin cream exhibited significant healing activity, achieving 80.70% wound contraction.

The percentage of wound closure was also found to be significant, with animals in Groups III, IV, V, and VI showing 89%, 90%, 86%, and 99% complete contraction, respectively, on the 15th day when compared with the control group. The duration required for complete epithelialization of the excision wound is considered a critical parameter in evaluating the wound healing process. In this study, the mean time for complete epithelialization in all treated groups was comparatively longer than that observed in the standard paraffin cream–treated group.

The Group VI treatment exhibited faster wound contraction than the standard. All other treated groups demonstrated comparable wound healing activity. In both excision and burn wound models, all prepared formulations produced a significant reduction in the period of epithelialization when compared with the control group ($p < 0.05$). Additionally, all treatments resulted in a significant decrease in wound contraction (by 50%) relative to the control. The higher dose of the leaf extract (2%) was particularly effective, showing greater efficacy in enhancing the breaking strength of excision wounds.

Excision Wound Healing Study

On the third day of the wound healing study, histopathological examination of the wound tissues revealed the following observations:

- Group I (Control): Microscopic sections showed skin with epidermis exhibiting focal areas of ulceration (Fig. 6). The dermis presented focal dense inflammatory infiltrates composed of lymphoplasmacytic cells and neutrophils, along with granulation tissue. No evidence of wound healing was observed.

- Group II (Standard): Sections revealed skin with epidermis showing focal ulceration. The dermis contained granulation tissue, focal lymphoplasmacytic infiltration, and a few neutrophils. Adjacent areas displayed early fibrosis.

  Group III (DSEE-treated): Sections showed skin with epidermis demonstrating focal ulceration. The dermis revealed focal dense inflammatory infiltrates consisting of scattered lymphoplasmacytic cells and a few neutrophils.

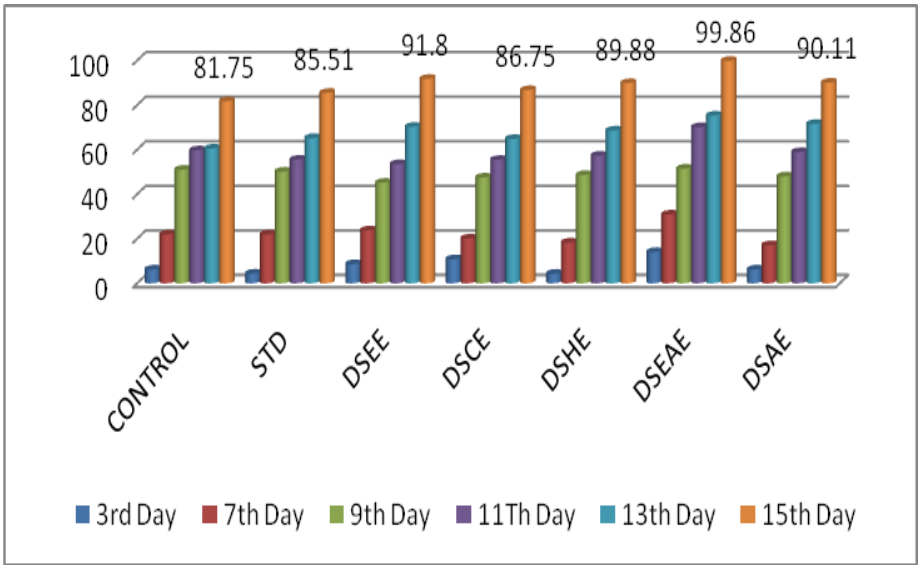

Fig. 1. Excision wound healing activity of *Datura stramonium* leaf

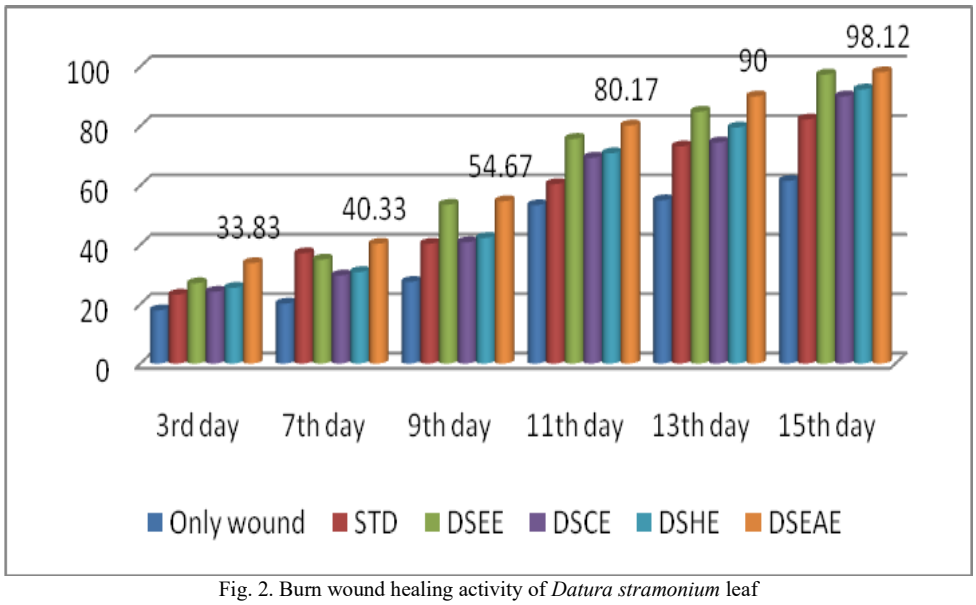

Fig. 2. Burn wound healing activity of *Datura stramonium* leaf



Fig. 3. Excision wound healing activity on 15th day



Fig. 4. Burn wound healing activity on 15th day

- Group IV (DSCE-treated): Sections revealed epidermis with focal ulceration. The dermis contained granulation tissue with focal lymphoplasmacytic infiltration. Adjacent areas showed fibrocollagenous stroma. In some areas, mild proliferation of thin-walled vessels with lymphoplasmacytic infiltration was also observed.

- Group V (DSHE-treated): Sections showed epidermis with ulceration. The dermis exhibited diffuse scattered lymphoplasmacytic infiltration with a few neutrophils. Adjacent areas displayed fibrocollagenous stroma. Mild proliferation of thin-walled vessels with lymphoplasmacytic infiltration and mild granulation tissue were also noted.

  Group VI (DSEAE-treated): Sections revealed dermis with chronic inflammatory infiltrates composed of lymphocytes and neutrophils (Fig. 7). Adjacent areas showed fibrosis, with focal areas demonstrating granulation tissue formation.

Histopathological observations on Day 9

On the ninth day of treatment, histopathological evaluation of skin tissues from different groups revealed the following features:

- Group I (Control): Sections showed tissue fragments lined by stratified squamous epithelium. Adjacent areas displayed neutrophilic abscesses along with karyorrhectic and necrotic debris. No evidence of wound healing was observed.

- Group II (Standard): Sections revealed tissue fragments with proliferation of thin-walled vessels. Foci of necrotic debris were present. The dermis showed neutrophilic infiltration, along with proteinaceous, fluid-like material.

- Group III (DSEE-treated): Sections demonstrated proliferation of thin-walled vessels. The dermis showed evidence of granulation tissue formation with mild lymphoplasmacytic infiltration (Fig. 5).

- Group IV (DSCE-treated): Sections showed tissue fragments with proliferation of thin-walled vessels. The dermis exhibited granulation tissue with mild lymphocytic infiltration, while adjacent areas revealed dense fibrocollagenous tissue (Figs. 8 and 9).

- Group V (DSHE-treated): Sections showed dense proliferation of thin-walled vessels along with regenerating epithelium. Foci of necrotic debris and fibrocollagenous tissue were observed. In some areas, deposition of refractive proteinaceous material (matrix protein) and granulation tissue were also noted.

- Group VI (DSEAE-treated): Effective wound healing was observed in animals treated with DSEAE. Histological sections of the skin showed focal areas of granulation tissue with proliferation of blood vessels. Dense areas of fibrosis and focal inflammatory infiltrates were also noted. Overall, the DSEAE treatment demonstrated a pronounced healing response, which was superior to that observed with the standard drug.

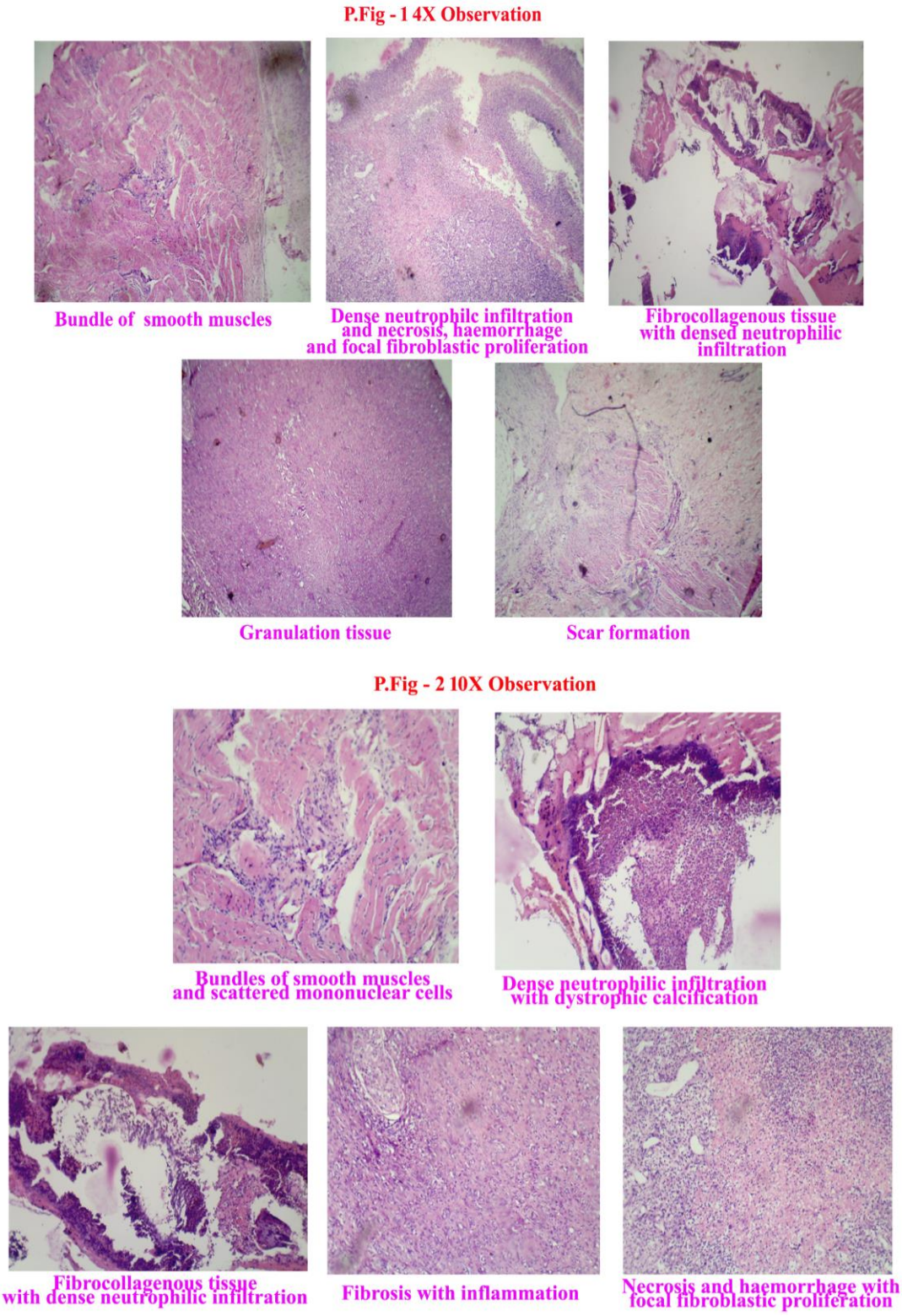

Fig.5 Histopathological Studies

Effect of *Datura stramonium* Extracts on Burn Wound Healing

- Day 3: Wounds in the untreated, simple ointment–treated, and all extract-treated groups appeared swollen and bruised. In contrast, wounds in the extract-treated groups exhibited only mild swelling, with relatively dry wound surfaces. Notably,

most wounds in the DSEAE-treated group had begun to contract from the wound edges.

- Day 7: Wounds in the untreated, simple ointment–treated, and extract-treated groups appeared dark red, with thickening of the skin at the wound site, and largely remained unchanged in size compared to Day 1. However, wounds treated with the extracts showed noticeable contraction relative to the control group.
- Day 9: Wounds in all groups showed moderate exudation and absence of hair growth, with scabs covering the wound surface. Wounds in the extract-treated groups displayed dry surfaces, progressive contraction, and early signs of hair growth.
- Day 15: On the final day of the study, all groups exhibited moderate exudation and scabs beginning to separate from the wound surface. Extract-treated wounds showed a marked reduction in size and continuous hair growth at the wound site. Among these, wounds treated with DSEAE and DSHE demonstrated the most significant reduction in wound size (Figs. 2 and 4).
- Overall, topical application of DSEAE at 2.5% and 5% concentrations, as well as Aloe vera extract gel (10%), significantly shortened the period of epithelialization and produced a marked decrease in wound contraction compared to the control group.

B. In-Vivo Antioxidant Activity

Serum samples from all groups, including those treated with plant extracts and the control group, were analyzed for antioxidant activity. The results demonstrated significant antioxidant effects in the extract-treated groups, evidenced by decreased levels of lipid peroxidation (LPO) and increased levels of superoxide dismutase (SOD), catalase, and reduced glutathione (GSH) in response to oxidative stress (Table 1).

TABLE 1
In-Vivo Anti-oxidant Activity of *Datura stramonium* of leaf extracts

S.No.	Group	LPO (µ.mol/L)	GPx (µ.mol/L)	CAT (µ.mol/L)	SOD (µ.mol/L)	Vit C mg/dl	Protein Mg/dl
1	Control	33.10±0.4	07.24±0.7	14.86±1.3	10.11±1.2	07.09±0.4	10.01±1.4
2	Standard	17.21±0.2	20.30±0.4	25.61±0.5	16.23±0.7	17.93±0.8	17.71±0.7
3	DSEE	15.11±0.5	23.33±0.6	27.22±0.1	18.34±0.4	26.42±1.8	27.43±1.5
4	DSCE	16.15±0.4	22.11±0.3	27.42±0.4	17.33±0.5	21.51±0.6	20.61±0.3
5	DSHE	17.34±0.7	25.30±0.5	28.17±0.3	19.41±0.5	24.53±0.5	24.32±0.5
6	DSEAE	14.22±0.3	27.30±0.4	29.33±0.5	20.26±0.6	27.19±0.3	28.74±0.6

LPO – Lipid Peroxidation, GPx – Reduced Glutathione, CAT – Catalase SOD – Superoxide Dismutase, Vit C – Vitamin C

IV. DISCUSSION

Datura stramonium contains several bioactive constituents essential for wound healing, including vitamin C (ascorbic acid), amino acids, vitamin E, and zinc. Ascorbic acid promotes collagen synthesis and helps counteract collagen degradation. Vitamin E, a fat-soluble antioxidant, contributes to wound repair by stabilizing lysosomal enzymes necessary for collagen formation and preventing free radical–induced cross-linking that can impair normal healing. Zinc has been shown, including in the authors' laboratory, to enhance the tensile strength of wounds, thereby improving overall healing. Additionally, *Datura stramonium* facilitates capillary penetration, cleansing, and dilation at the injury site, which supports tissue repair. The plant extract may also accelerate epithelialization and reduce dehydration-induced necrosis, further promoting efficient wound healing [34], [35].

The present study was undertaken to evaluate the wound healing potential of the ethyl acetate leaf extract of *Datura stramonium* in experimentally induced wounds in rats. The ethyl acetate extract was found to enhance wound healing by increasing wound contraction,

improving breaking strength, and reducing the period

of epithelialization. These effects are likely mediated through stimulation of collagen synthesis and modulation of various growth factors involved in tissue repair.

Treatment with *Datura stramonium* leaf extracts significantly increased the levels of catalase, indicating a protective effect on soft tissues. The extracts also contributed to a reduction in tumor burden, which in turn decreased oxidative stress and helped restore the normal levels of antioxidant enzymes. Superoxide dismutase (SOD) and catalase are considered primary antioxidant enzymes, as they play a crucial role in the direct elimination of reactive oxygen species (ROS) and in maintaining cellular redox balance [36], [37]. A decrease in hepatic catalase activity is a well-established phenomenon associated with tumor burden, and reduced SOD activities have also been reported in multiple organs of tumor-bearing animals. The results of the present study are consistent with these observations. Treatment with *Datura stramonium* leaf extract effectively reduced oxidative stress in tumor-bearing animals and restored the activities of key enzymatic antioxidants, including catalase and SOD [38].

The free radical scavenging system, including superoxide dismutase (SOD) and catalase, is present in all oxygen-metabolizing cells. In EAC-bearing mice, SOD and catalase levels were significantly decreased, leading to reduced total SOD activity in the liver. Inhibition of SOD and catalase activity has been associated with enhanced tumor growth. Administration of *Datura stramonium* leaf extract at different doses (400 mg/kg) significantly increased SOD and catalase levels, suggesting its antioxidant and free radical–scavenging properties.

The present study was undertaken to evaluate the wound healing potential of the ethyl acetate leaf extract of *Datura stramonium* (DSEAE). The extract promoted wound healing in experimentally induced wounds in rats by enhancing breaking strength, wound contraction, and reducing the period of epithelialization. These effects are likely mediated through stimulation of collagen synthesis by various growth factors. The wound healing activity was further supported by the increased tensile strength of incision wounds. In general, effective wound healing agents enhance collagen deposition, which strengthens tissues and facilitates cross-linking between collagen fibers, thereby improving overall wound integrity [39], [40], [41].

The observed increase in tensile strength of treated wounds may be attributed to enhanced collagen concentration, stabilization of collagen fibers, and the improved activity of myofibroblasts, which contribute to tissue elasticity. Histological examination of the treated lesions revealed better tissue alignment, reduced infiltration of inflammatory cells, and significantly improved biomechanical properties. These findings are consistent with the results obtained in the present study [42], [43].

The wound healing activity of *Datura stramonium* may be attributed to the antioxidant, anti-inflammatory, and antimicrobial properties of its phytochemical constituents [44]. Tannins, flavonoids, saponins, sterols, polyphenols, and triterpenoids are actively involved in the wound healing process. Tannins act as free radical scavengers and promote healing due to their astringent and antimicrobial properties. Flavonoids exhibit potent antioxidant and free radical–scavenging effects, enhancing the levels of antioxidant enzymes in granulation tissue. Saponins contribute to wound contraction and increased epithelialization through their antioxidant and antimicrobial activity. Triterpenoids facilitate wound healing owing to their astringent and antimicrobial properties. Sterols and polyphenols

also support wound repair by scavenging free radicals and reducing lipid peroxidation, thereby minimizing cell necrosis and improving vascularization [45].

Growth hormone is known to promote fibroblast proliferation, which is essential for tissue repair [46]. Lipid peroxidation plays a critical role in various types of injuries, including burns and skin ulcers. Drugs that inhibit lipid peroxidation are believed to enhance the viability of collagen fibrils, strengthen collagen fibers, prevent cellular damage, and promote DNA synthesis. Antioxidants such as vitamin C, vitamin E, and metronidazole have also been reported to accelerate wound healing. *Datura stramonium* leaf extracts are rich in phenolic compounds, which exhibit potent antioxidant and free radical–scavenging activity. Additionally, these extracts possess iron-chelating and reducing properties [47]. In vitro assays confirm that *Datura stramonium* leaves act as natural antioxidants, supporting their therapeutic potential in wound healing [48], [49], [50].

V. CONCLUSION

All the prepared formulations demonstrated significant wound healing activity, achieving up to 99.1% wound closure. In vivo studies further confirmed the antioxidant potential of the extracts. Overall, the results of this study suggest that *Datura stramonium* leaves could serve as an effective therapeutic agent for the treatment of excision and burn wounds. Among the tested extracts, the ethyl acetate fraction exhibited the most pronounced activity.

VI. ACKNOWLEDGEMENTS

The authors are grateful to Prof. G. Ariharasivakumar, KMCH College of Pharmacy, Kovai Medical Center Research and Educational Trust, Coimbatore, for his continuous encouragement and support, as well as for providing access to all necessary laboratory facilities.

VII. Conflict of interest

None.

VIII. REFERENCES

[1] F. Khallef, *Datura stramonium flowers as a potential natural resource of anti-inflammatory agents against bacterial infections*, MDPI -Pharmaceuticals, 2023, vol. 16(7).
[2] Aleksandra Shedoeva, David Leavesley, Zee Upton and Chen Fan, *Wound Healing and the Use of Medicinal Plants. Evid Based Complementary and Alternative Medicine*, 2019.
[3] Temidayo Ogunmoyole, Racheal Imoleayo Adeyeye, Beatrice Oluwatosin Olatilu, Olubukola Abidemi Akande and Oluwadare Joel Agunbiade, *Multiple organ toxicity of Datura stramonium seed extracts*, Toxicol Rep, 2019, vol. 6.
[4] A. Abdullahi, E. Murtalaa Oyinloye, A. Oladapob Aderonke, E. Aderionlaa Wasiu, O. Olootoc Oluwatosin, O. Soyinkac Royhan, A. Folarind Farouk, O. Oladojab Oluwatoyin, E. Shondea Luqmon, B. Osipitana Emmanuel, Adegbea and A. Julius Abolarinwa, *Sub-chronic (Ninety Days) Toxicity Study of Hydroethanolic Leaf Extract of Datura stramonium L. in Rodents*, Clinical Complementary Medicine and Pharmacology, 2023, vol. 3(2).
[5] Chandan K Sen. (2019). *Human Wounds and Its Burden: An Updated Compendium of Estimates*, Advances in wound care, 2019, vol. 8(2).
[6] Mohammad Reza Farahpour, *Medicinal Plants in Wound Healing*, Book Chapter Intechopen, 2019.
[7] Andras Kerchner and Agnes Farkas, *Worldwide poisoning potential of Brugmansia and Datura. Forensic toxicology*, 2020, vol. 38.
[8] Majid Jalali, Mehdi Abedi, Farshid Memariani and Abdolbaset Ghorbani, *Ethnobotanical study of wild edible plants in the mountainous regions of Semnan Province*, Iran. J. of Ethnobiology and Ethnomedicine, 2024, Vol. 20.
[9] Yibala Ibor Oboma and God'sman C Eberechukwu. *Alteration in Oxidative Stress Enzymes and Proteins by Datura metel Stramonium hydroethanolic root extract promotes hippocampus and cerebral cortex neurons damage in adult sprague dawley rats*, Subst Abuse Rehabil, 2025, vol. 16.
[10] Ananthasekar Anbumani, Radhika Sathasivam and Chellaia Muthammal Padma, *Synergistic effect of Polyvinyl alcohol and Datura stramonium leaf extract films for novel antibacterial and wound dressing applications*, J. of Industrial and Eng Chem. 2023, vol. 134(5).
[11] F. O. Oyedeji, T. T. Ogunkunle, A. B. Fawehinmi and O. M. Balogun, *Evaluation of Wound Healing and Antibacterial Activities of Crude Ethanol Extract of Datural metel Leaves on Wistar Rats*, Arch Appl Sci Res, 2021, vol. 13(10).
[12] Suresh Kumar Dev, P. K. Choudhury, Rajnish Srivastava and Maya Sharma, *Anti-microbial, anti-inflammatory and wound healing activity of polyhedral formulation*, Biomedicine & Pharmacotherapy, 2019, vol. 111.
[13] C. K. Kokate, A. P. Purohit and S. B. Gokhale. 58th ed., Pharmacognosy, Advika Book publication, 2023.

[14] Bilel Damergi, Rym Essid, Nadia Fares, Nadine Khadraoui, Lucía Ageitos, Ameni Ben Alaya, Dorra Gharbi, Islem Abid, Monerah Rashed Alothman, Ferid Limam, Jaime Rodríguez, Carlos Jiménez and Olfa Tabbene, *Datura stramonium Flowers as a Potential Natural Resource of Bioactive Molecules: Identification of Anti-Inflammatory Agents and Molecular Docking Analysis*, Molecules 2023, vol. 28.

[15] S. Singh, and V. Kumar, (2022). *Animal models for wound healing studies: A systematic review*, Wound Medicine, 2022, 37.

[16] Gupta Surbhi, Anand Anubhav and Gupta Kumar Ramesh, *Assessment of wound healing potential of simvastatin emulgel in rat excision wound model*, Letters in Drug Design & Discovery, 2024, vol. 21(9).

[17] Shafiul Azam Zishan, Md. Maien Uddin, Mahatir Mohammad, S. M. Asadul Karim Azad, Jannatul Naima, Sadab Sipar Ibban and Md. Saiful Islam Arman, *Costus speciosus leaf and seed extracts for wound healing: a comparative evaluation using mice excision wound models*, Clinical Phytoscience, 2024, vol. 10.

[18] Tawhida Islam, Iffat Ara, Tariqul Islam, Pankaj Kumar Sah, Ray Silva de Almeida, Edinardo Fagner Ferreira Matias, Cícero Lucas Gomes Ramalho, M. Henrique Douglas Coutinho and Muhammad Torequl Islam. *Ethnobotanical uses and phytochemical, biological, and toxicological profiles of* Datura metel *L.: A review*, Curr Res in Toxico, 2023, vol. 4.

[19] Grigory Demyashkin, Tatiana Sataieva, Ludmila Shevkoplyas, Tatyana Kuevda, Maria Ahrameeva, Mikhail Parshenkov, Alexander Mimuni, Georgy Pimkin, Dmitrii Atiakshin, Vladimir Shchekin, Petr Shegay and Andrei Kaprin. *Burn Wound Healing Activity of Hydroxyethylcellulose Gels with Different Water Extracts Obtained from Various Medicinal Plants in Pseudomonas aeruginosa-Infected Rabbits*, Int J Mol Sci., 2024, vol. 25(16).

[20] Kamilia Dwi Utami and Ulfah dian Indrayani. *Potential Healing Effect Of Mulberry Leaf Extract Oinment on Burn Injury in rats*, International Journal of Human and Health Sciences (IJHHS), 2020, vol. 5(2).

[21] A. Ibrahim, K. M. A. Hassanein, M. Soliman, *New burn model for developing consistent second- and third-degree burn injuries in rats*, BMC Research Notes, 2025, vol 18.

[22] C. X. Huang, E. Siwan, S. L. Fox, M. Longfield, S. M. Twigg and Danqing Min. (2023). *Comparison of digital and traditional skin wound closure assessment methods in mice*, Lab Anim Res, 2023, vol. 39.

[23] O. Sunday Udegbunam, Sunday Ogbobe, H. Nnamdi Okereke, S. Adaobi Enejere, R. Ijeoma Udegbunam, H. Toochukwu Ezeobialu, *Assessment of wound contraction, re-epithelialization and histological changes in full thickness excision wounds of rats treated with different concentrations of hydrogen peroxide*, Trop J. of Pharma Res, 2021, vol. 20(8).

[24] K. Preeja Sundaresan and P. Kala Kesavan. *In vitro evaluation of antibacterial activity in ethanolic extract of whole plant Sphaeranthus indicus Linn*, Int J Basic Clin Pharmacol. 2020. Vol. 9(11).

[25] Lalitha Vaidyanathan and T Sivaswamy Lokeswari, *Anti-bacterial and anti-inflammatory properties of* Vernonia arborea *accelerate the healing of infected wounds in adult Zebrafish*, BMC Complement Med Ther. 2024, vol. 24.

[26] Zhao Chunlin, Guo Yuchen, Li Lingli, Yang Mei, *Non-invasive techniques for wound assessment: A comprehensive review*, Int Wound J. 2024, vol. 21(11).

[27] Benu George, Nitish Bhatia and T. V. Suchithra, *Burgeoning hydrogel technology in burn wound care: A comprehensive* meta-*analysis*, European Polymer Journal. 2021, vol. 157(15).

[28] Uche Chidiebere. *Evaluation of Antibacterial and Wound Healing Activity of Cocos nucifera (Coconut) Husk Ash Extract in Mice*, J Food Process Technol, 2021, vol. 12(4).

[29] A. Hamid, P. L. Chong, Y. Y. Khor, P. Y. Kong, N. R. Rasli, N. M. Abd Warif, A. R. Ghazali and N. F. Jufri. (2024). B*iochemical, immunological markers, histology and ultrastructural changes of open wound healing in rats treated with ethyl acetate extract of Zingiber zerumbet*, Heliyon, 2024, vol.10(4).

[30] Santoso, Astrid Widhowaty, Eri Amalia, Kartika Indah Sari, Veni Takarini and Irna Sufiawati, *Histopathological Evaluation of Wound Healing and Anti-Inflammatory Effects of Granola Potato Peel Ethanol Extract in Rat Oral Mucosa*, J. of Exp. Pharma, 2024, vol. 16.

[31] U. Esther Alum, E. Joseph Inya, P. C. Okechukwu Ugwu, I. Emmanuel Obeagu, Chinyere Aloke, M. Patrick Aja, G. Mmesoma Okpata, C. Esther John, O. Manasseh Orji and Ozioma Onyema. *Ethanolic leaf extract of Datura stramonium attenuates methotrexate-induced biochemical alterations in Wistar Albino rats*, RPS Pharmacy and Pharmacology Research. 2023, vol 2(1).

[32] Aya Hassan, Ghada Samy, Mohamed Hegaz, Ahmed Balah and Shaimaa Fathy, *Statistical analysis for water quality data using ANOVA (Case study – Lake Burullus influent drains)*, Ain Shams Engineering Journal. 2024, vol 15(4).

[33] Maryam Ghahremani-Nasab, Azizeh Rahmani Del Bakhshayesh, Naeimeh Akbari-Gharalari and Ahmad Mehdipour, *Biomolecular and cellular effects in skin wound healing: the association between ascorbic acid and hypoxia-induced factor*, Journal of Biological Engineering, 2023 vol 17.

[34] Vinay Kumar, Abul K. Abbas, Jon C. Aster. *Robbins & Cotran Pathologic Basis of Disease (Robbins Pathology)*, 10th edition, Elsevier, 2020.

[35] Nada Bechara, M. Victoria Flood and E. Jenny Gunton, *A Systematic Review on the Role of Vitamin C in Tissue Healing*, Antioxidants (Basel), 2022, vol 11(8).

[36] Daniel Rodrigues de Bastos, Adhemar Longatto Filho, Mércia Patrícia Ferreira Conceicao, Lara Termini. *High Levels of Superoxide Dismutase 2 Are Associated With Worse Prognosis in Patients With Breast Cance,*. Eur J Breast Health, 2024, vol 20(3).

[37] U. Esther Alum, P. C. Okechukwu Ugwu, M. Patrick Aja, I. Emmanuel Obeagu, E. Joseph Inya, P. Amarachi Onyeije, Esther Agu and Chinaza Godswill Awuchi, *Restorative effects of ethanolic leaf extract of Datura stramonium against methotrexate-induced hematological impairments*, Cogent Food & Agriculture, 2023, vol 9.

[38] Bakht Nasir, Muhammad Waleed Baig, Muhammad Majid1, Syeda Masooma Ali, Muhammad Zafar Irshad Khan, Syeda Tayyaba Batool Kazmi and Ihsan-ul Haq. *Preclinical anticancer studies on the ethyl acetate leaf extracts of Datura stramonium and Datura inoxia*, BMC Complementary Medicine and Therapies, 2020 vol 20.

[39] Shruti Gajbhiye and Sarika Wairkar, *Collagen fabricated delivery systems for wound healing: A new roadmap*, Biomat.Adv, 2022, vol. 142.

[40] Manman Li, Mei Han, Yusheng Sun, Yingying Hua, Guifang Chen and Liefeng Zhang. *Oligoarginine mediated collagen/chitosan gel composite for cutaneous wound healing*, Int. J. of Biolog. Macromole. 2019, vol 122.

[41] A. Anbumani, S. Radhika, C. M. Padma, *Synergistic effect of Polyvinyl alcohol and Datura stramonium: Approach towards active wound dressing*, J. of Industrial and Engi Chemi, 2024, vol 134(25).

[42] Lusiana Aulia and Yunita Sari Pane, *Effect of* Aloe vera *extract in post-burn skin repair in rats*, F1000Res. 2023, vol 11.

[43] Warintorn Ruksiriwanich, Pichchapa Linsaenkart, Anurak Muangsanguan, Korawan Sringarm, Pensak Jantrawut, Chaiwat Arjin, Sarana Rose Sommano, Yuthana Phimolsiripol and J. Francisco Barba, *Wound Healing Effect of Supercritical Carbon Dioxide Datura metel L. Leaves Extracts: An In Vitro Study of Anti-Inflammation, Cell Migration, MMP-2 Inhibition, and the Modulation of the Sonic Hedgehog Pathway in Human Fibroblasts*, Plants (Basel). 2023, vol 12(13).

[44] Meenakshi Sharma, Inderpreet Dhaliwal, Kusum Rana, Anil Kumar Delta and Prashant Kaushik, *Phytochemistry, Pharmacology, and Toxicology of Datura Species—A Review*, Antioxidants (Basel), 2021, vol 10(8).

[45] Abirami, J. Jabesta, R. E. Renitta, D. A. Anand and A. V. Samrot, *Antimicrobial activity of flower extracts against wound pathogens and fungi*, Current Research in Green and Sustainable Chemistry , 2021, vol 4.

[46] M. Arage, T. Eguale and M. Giday, *Evaluation of Antibacterial Activity and Acute Toxicity of Methanol Extracts of Artemisia absinthium, Datura stramonium, and Solanum anguivi*, Infect Drug Resist, 2022, vol 15.
[47] Ali Jaber, Lamis Al-Harakeh, Ghassan Ibrahim and Edmond Cheble. *Phytochemical study and antioxidant activity of extract from the leaves of lebanese Datura metel L*, European j. of pharmaceutical and medical res, 2019, vol 6(8).
[48] A. Ananth and S. Rajan S, *In-vitro antioxidant activity of Datura stramonium leaves. Pelagia Research Library*, Advances in Applied Science Research, 2015, vol 6(4).
[49] Sumit Sheoran and Swati Arora, *Evaluation of Antioxidant Anticancer and Antimicrobial Activities of Datura Leaf Extracts*, A Microbiological Perspective Biorxiv, 2025, vol 1.
[50] Nitin Jangra, Aakanksha Singla, Vivek Puri, Divya Dheer, Hitesh Chopra, Tabarak Malik and Ameya Sharma, *Herbal bioactive-loaded biopolymeric formulations for wound healing applications*, *RSC Adv.*, 2025, vol 15.