

Journal of Applied Life Sciences International

12(2): 1-14, 2017; Article no.JALSI.33244
ISSN: 2394-1103

Effects of Raw Ethanolic Seed Extract of *Tetracarpidium conophorum* on Heamatological and Histopathological Parameters in Swiss Albino Mice Infected with *Plasmodium berghei*

O. O. Ogundolie[1*], E. O. Dada[1], I. B. Osho[2] and D. A. Oloruntola[1]

[1]Department of Microbiology, The Federal University of Technology, Akure, Ondo State, Nigeria.
[2]Department of Animal Production and Health, The Federal University of Technology, Akure, Ondo State, Nigeria.

Authors' contributions

This work was carried out in collaboration between all authors. Author OOO designed the study, performed the statistical analysis, wrote protocol, and wrote the first draft of the manuscript. Authors EOD and IBO managed the analyses of the study. Authors OOO and DAO managed the literature searches. All authors read and approved the final manuscript.

Article Information

DOI: 10.9734/JALSI/2017/33244
Editor(s):
(1) Purnachandra Nagaraju Ganji, Department of Hematology and Medical Oncology, Emory University School of Medicine, USA.
Reviewers:
(1) Viduranga Waisundara, Rajarata University of Sri Lanka, Mihintale, Sri Lanka.
(2) Elvis Ofori Ameyaw, University of Cape Coast, Cape Coast, Ghana.
(3) M. E. Khan, University of Agriculture, Makurdi, Benue State, Nigeria.
Complete Peer review History: http://www.sciencedomain.org/review-history/19608

Original Research Article

Received 5th April 2017
Accepted 16th May 2017
Published 19th June 2017

ABSTRACT

Study was carried out to determine the heamatological and histopathological effects of raw ethanolic seed extract of *Tetracarpidium conophorum* in swiss albino mice infected with *Plasmodium berghei* (NK65). Standard methods were employed to determine the heamatological, histopathological indices and biochemical assay. The experimental mice were acclimatized for seven days before the commencement of treatment. Mice were grouped into six groups (A, B, C, D, E and F) of four mice each. The mice in group B were treated with a standard antimalarial drug (chloroquine as positive control) at a dose of 5 mg/kg body weight, while mice in groups D, E and F was administered with increasing dosages (200, 400, 600 mg/kg body weight) of seed extracts for four consecutive days respectively. Group C (Normal control) served as mice that was not infected

**Corresponding author: E-mail: olubusolalilian@gmail.com;*

and treated. Heamatological analysis revealed an increase in Packed Cell Volume, Red Blood Cells, Heamoglobin and Platelet values of all mice in groups D, E and F (mice administered different concentrations of the extract). Mice in group B (chloroquine treated group) have the highest value. Mice in group A (negative control) exhibited lowest values of Heamoglobin, Platelet, Red blood cells, and Packed Cell Volume. There was significant increase in the levels of Alanine Transaminase and Aspartate Transaminase in group A (infected and not treated) compared to mice in groups C, D, and E. Restorative effects of seed extract was observed on the liver and kidney of mice at dose levels (400 and 600 mg/kg) used, but the seed extract at the dose of 600 mg/kg was observed to have adverse effects on the liver of the mice. This study therefore shows that *Tetracarpidium conophorum* was able to boost the formation of heamatological indices and was not toxic to the organs (liver and kidney) in mice.

Keywords: Tetracarpidium conophorum; Plasmodium berghei; heamatology; histopathology; Albino mice.

1. INTRODUCTION

Malaria has been a severe and life threatening disease for thousands of years. The major impact of the disease is entirely on the developing countries, with the heaviest burden in Africa. It is one of the leading infectious diseases in many tropical regions, including Nigeria [1].

According to Rabiou et al. [2], malaria is a complex disease whose epidemiology and clinical manifestations varies widely in different parts of the world as a result of the species of malaria parasite, their susceptibility to antimalarial drugs, distribution and efficiency of mosquito vectors, climate and level of immunity of the exposed human population. This parasitic disease is transmitted by the bite of an infected female *Anopheles* mosquito. Five *Plasmodium* species (*Plasmodium falciparum*, *Plasmodium vivax*. *Plasmodium malariae* and *Plasmodium ovale*) that infect human [3]. The fifth specie (*Plasmodium knowlesi*) is found throughout Southeast Asia as a natural pathogen of long-tailed and pig-tailed macaques has recently been implicated to be a major cause of human malaria in Malaysia [4]. According to Andare – Neto et al. [5], *Plasmodium falciparum* being the most dominant and pathogenic is responsible for almost all mortality caused by malaria in tropical and Sub tropical countries where the temperature and rainfall are optimum for the development of vectors and parasites. Berendt et al. [6], reported four *Plasmodium* species (*Plasmodium berghei*, *Plasmodium chabaudi*, *Plasmodium vinckei* and *Plasmodium yoellii*) that have been described in African murine rodents and occur geographically in Central Africa. *Plasmodium berghei* is transmitted by the bite of mosquito (*Anopheles dureni*). These parasites of rodents are practical model organisms in the laboratory for the study of human malaria aimed at the development of new vaccines and treatments.

According to WHO (2015) [1], antimalarial drug resistance is a major health problem, which hinders the control of malaria. The use of chloroquine (CQ) to prevent and treat *falciparum* malaria has led to the widespread appearance of chloroquine resistant strains of *Plasmodium falciparum* throughout the world. Atetetgeb et al. [7] was of the opinion that this resistance has increasingly extended to other available antimalarial drugs (amodiaquine, lumetantrine, mefloquine or sulfadoxine, pyrimethamine). Consequently, the possible source of malaria treatment will appear to lie in the use of traditional herbal medicine. Phillipson et al. [8] advanced that the use of plants for the treatment of malaria has extended to over three continents, including several countries in Africa, America and Asia.

Tetracarpidium conophorum climbing shrub 10-20 ft long is known in the Southern Nigeria as 'Ukpa' (Igbo),Western Nigeria as awusa or asala (Yoruba), in the littoral and Western Cameroon as 'Kaso'or 'Ngak'. It is found in Uyo, Lagos, Akure, Kogi and Ibadan [9]. This plant is cultivated principally for the nuts which are cooked and consumed as snack [9].The fruits are edible, the plant is medicinal and used for various purposes, including masticatory, thrush, antihelminth, syphilis, dysentary and as an antidote to snake bites [9]. Walnuts are considered to be an herb in Traditional Chinese medicine. They are said to tonify kidneys, strengthen the back and knees, and moisten the intestines. It is believed to stop asthma and is prescribed to be taken between bouts of asthma,

but not for acute asthma. It is used for elderly as a constipation cure [10].The bark is used in tea as laxative and chewed for toothaches. It helps to prevent and control high blood pressure. As a result of Ascorbic acid in the root, the plant can be used in herbal medicine for the treatment of skin conditions including eczema, pruritus, psoriasis and parasitic skin conditions [11]. This vitamin can be used in the treatment of common cold and other diseases like prostate cancer [12], other vitamins though in trace amounts are essential for body metabolism. There is also an interesting ability of ascorbic acid as an antioxidant to prevent or at least minimize the formation of carcinogenic substances from dietary materials [11]. Walnut extract possess anticancer property and reduces diabetic complication [13]. The aim of the study is to determine the effect of raw ethanolic seed extract of *Tetracarpidium conophorum* on hematological and histological parameters in swiss albino mice infected with *Plasmodium berghei.*

Raw unshelled walnut **Raw shelled walnut**

Fig. 1. *Tetracarpidium conophorum* seeds (Nigerian walnuts)

2. MATERIALS AND METHODS

2.1 Seeds Collection

The seeds of the plant *Tetracarpidium conophorum* were collected on the 6th of May, 2016 from a farmland in Akure, Ondo State. Seeds were identified and authenticated by Dr Fayehun Lawrence at the Department of Crop Soil and Pest (CSP) Management, School of Agricultural Technology, The Federal University of Technology, Akure, Ondo State, Nigeria. Samples were deposited to the Department of Microbiology Laboratory, The Federal University of Technology, Akure for further analysis.

2.2 Preparation of Extracts

The seeds were separated from the hull, washed and dried at room temperature (27±°C) for a month before grinding into a coarse powder with mortar and pestle then stored in an air tight bottle prior to analysis. Five hundred grams (500 g) of the grounded powder was soaked into 700 mls of 75% ethanol, stirred and left for 72 hours. The mixture was filtered using a millipore filter (pore size 0.7um) and concentrated in a rotary evaporator at 40°C. The concentrate was heat dried over a water bath to obtain a solvent free extract and was refrigerated at 20°C.

2.3 Assemblage of Experimental Mice

Ethical use of experimental mice was in conformity with international, national and institutional guidelines for care and use of laboratory animals in Biomedical Research by Canadian council of animal care and United State National Institute of Health described by Adeneye, [14].

Mice weighing between 17-22 g were obtained from animal house, Obafemi Awolowo University, Ile-Ife. Mice were housed in plastic cages with saw dust as beddings. They were fed with pellets (Supreme Pet food) and water ad libitum and acclimatized for 7 days at room temperature 29°C -30°C before the commencement of the experiment.

2.4 Preparation of Seed Extract

Seed extract was prepared by measuring 1.0 g, 2.0 g, 3.0 g on a sensitive scale and dissolving into 5 mL of distilled water to produce concentrations of 200 mg/ml, 400 mg/ml and 600 mg/ml respectively and administered orally as treatment dose to mice in groups D, E, and F.

2.5 Grouping of Animals

The method described by Berhan et al. [15] was used to group the experimental mice. A total of 24 mice were randomly divided into six groups A (negative control), B (positive control), C (normal control), D, E and F of four mice per group for the antimalarial activity. While a total of 16 mice were randomly grouped into four groups of four mice each.

2.6 Acute Toxicity

Acute toxicity test of the seed extract was carried out using [16]. Each mouse was respectively

administered (400, 600, 900, 1000 mg/kg body weight) of *Tetracarpidium conophorum* ethanolic seed extract orally. The mice were observed daily for seven days for reduced activities, licking of paw, body weakness, sleeping and mortality.

2.7 Collection of Parasites

Chloroquine sensitive strain of malaria parasite (*Plasmodium berghei NK 65*) in a donor mouse was obtained from Obafemi Awolowo University, Ile-Ife Osun State, Nigeria. Parasite was kept alive by inoculating 0.2 mls of it into a healthy mouse (infected mouse) through intraperitoneal route. By cardiac puncture, 0.2 mls of the parasite was withdrawn from the infected mouse and serially diluted with sterile 4.8 mls of normal saline to obtain 1x107 *Plasmodium berghei* infected erythrocyte. Mice in groups A, B, D, E and F were given 0.2 mls of the parasite after the parasitemia level of the infected mouse had been ascertained to be high. Group C (normal control) was not infected. Mice were visually observed for behavioral changes (decreased activities, loss of appetite) [17].

2.8 Determination of Parasitemia

Parasitemia in the mice was determined**,** using the method described by Hilou et al. [18]. After 3 hours of infection with the *Plasmodium berghei*, the seed extract was prepared by measuring 1.0 g, 2.0 g, 3.0 g on a sensitive scale and dissolving it into 5 ml of distilled water to produce concentrations of 200 mg/ml, 400 mg/ml and 600mg/ml respectively and administered orally as treatment dose to mice in groups D, E, and F. Group B mice (positive control) received 5 mg/kg of chloroquine, mice in group C (normal control) received 0.2 mls of normal saline, Mice in group A (negative control) were not treated. The treatment was administered for four consecutive days.

On day five, parasitemia level of the mice (except group C) was determined by collecting a drop of blood on a microscope slide from each mouse by venesection of the tail. Thin blood smear was made and allowed to dry at room temperature. It was fixed with methanol before staining with 10% Giemsa for 10 minutes. The slides were allowed to air-dry, examined and counted under light microscope at X100 magnification (oil-immersion). The parasitemia was determined by counting minimum of three fields per slide with 100 RBC per field [19]. The percentage suppression of parasitaemia was calculated for each test concentration by comparing the parasitaemia in infected groups with those that received different concentrationsn of the test extract using [20].

Parasitemia = (Number of parasitized RBC x 100 / Total Number of RBC examined) (1)

Average % chemosuppression = (Parasitemia in negative control – Parasitemia in treatment x 100) / Parasitemia in negative control (2)

2.9 Administration of Drugs

The method described by Hilou et al. [18] was used. After 3 hours of infection with the *Plasmodium berghei*, different concentrations (200, 400, 600 mg/kg body weight) of the extract were respectively prepared and administered orally as treatment dose to mice in groups D, E, and F. Group B mice (positive control) received 5 mg/kg of chloroquine, mice in group C (normal control) received 0.2 mls of normal saline, Mice in group A (negative control) were not treated. The treatment was administered for four consecutive days.

2.10 Hematological Analysis of *Tetracarpidium conophorum* Seed Extract

On the fifth day of the experiment, the Swiss albino mice used for antimalarial activity were subjected to euthanasia under chloroform, dissected and blood was collected through cardiac puncture in an Ethylene Diamine Tetra-acetic Acid (EDTA) bottle and the blood parameters (Red blood cells (RBC), White blood cells (WBC), Packed Cell Volume (PCV), Mean Cell hemoglobin Concentration (MCHC), Mean Cell Corpuscular Volume (MCV) and Mean Cell Hemoglobin (MCH)were assayed using Abacus 380 hematology analyzer.

2.11 Biochemical Assays

Blood was collected from mice in a lithium heparin bottle through cardiac puncture. The alanine transaminase (ALT) and aspartate transaminase (AST) was determined with Automated Refloton machine using the recommended test strips.

2.12 Histopathological studies

Histopathological analysis was carried out using the method of Yerbanga et al. [21].This was carried out to know the effect of the parasite and seed extract on organs in mice. After subjecting the mice to euthanasia under chloroform. Liver and kidney were removed and fixed in 10% formalin for 48 hours. The fixed organs were washed in several running tap water to remove oxidizing agents in fixative. The organs were sliced and suspended in the decalcifying solution by means of a waxed thread to remove calcium. When decalcification was completed tissues were then transferred directly to 70% alcohol for 4hrs, then to 90% alcohol and finally in 2 changes of absolute alcohol 4hrs each. The tissue were cleared in clearing agent such as xylene for $1^{1/2}$hr and later using a warm pair of blunt-nosed forceps to transferred the tissue to a bath of molten paraffin wax in a mould.

The surface of the mould was blown until a thin film of wax had solidified and later immersed gently in a container of cold water for 30 minutes.The embedded tissues were sectioned by trimming the block using microtome machine. The ribboning produced were transferred gently onto the surface of warm water in a water bath (10°C)

When the tissue sectioning was fully expanded, a prepared clean, grease –free slide was dipped obliquely into the water as close to the section as possible allow its surface to touch the edge of the section. Slides were completely removed with attached section was adjusted to a suitable position on the slide with a mounted needle.

The slide with sectioning was transferred to hot plate at 45°C for 1hr to ensure that the sections were thoroughly dried before staining. Before staining, paraffin wax was removed from the slide by immersing the slide in xylene for 30minutes. Slides were then transferred to absolute alcohol for 30 seconds to remove the xylene. Using blunt-nosed forceps, the slide were transferred into different descending grade of alcohol (90%, 70%) for 30 seconds each and finally were washed thoroughly in distilled water.

Slides were flooded with solution 1 for 30 minutes.They were washed thorough in running tap water, and differentiated in solution 2 until no more colour is seen.

The slide were flooded with scotts's tap water (solution 3) for 10 minutes and counterstain in solution 4 (Eosine) for 2 minutes. Finally, they were washed in running water until the excess eosin was removed. They were dehydrated in ascending grade of alcohol (70%, 90% and absolute) for 30 seconds, cleared with xylene for 3 minutes.

The slides were mounted using Canada balsam and cover slip. The morphological changes within the tissues of the control and infected mice were observed under the microscope.

2.13 Statistical Analysis

All data were expressed as mean ±S.E. One way analysis of variance was used to analyze data. $P< 0.05$ was considered significant difference between means (Duncan's multiple range test).

3. RESULTS

Recent published study on "*In vivo* antiplasmodial activity of ethanolic seed extract of *Tetracarpidium conophorum* in swiss albino mice infected with *Plasmodium berghei* revealed at 200, 400, and 600 mg/kg concentration of the seed extract, mean parasite count of the mice was 34.9%, 24.85%, and 18.38% respectively. Chemosuppression value of the extract in groups D, E and F were 2.77%, 30.55%, and 47.22% respectively, while the value for chloroquine (group B) was 55.5%. Parasitemia in groups D, E, and F decreases with increase in dose levels of the extract. The observed value chemosuppression of mice administered 5 mg/kg body weight of chloroquine were significantly higher ($P< 0.05$) than mice in groups D, E and F. above were significantly higher ($P< 0.05$) compared with the mice in group A. The parasitemia in the chloroquine treated mice is lower than mice administered with the highest dose of the seed extract.

Hematological analysis (Table 1) revealed increase in Packed Cell Volume (PCV), Red Blood Cells (RBC), Hemoglobin (HGB) and Platelet (PLT) values of all mice in group D, E and F. The PCV, RBC, HGB and PLT of mice in group D was (4.27 ± 0.01^{d}, 6.21 ± 0.01^{d}, 9.10 ± 0.01^{c}, 18.46 ± 0.03^{c}), group E (8.02 ± 0.01^{c}, 7.01 ± 0.01^{c}, 9.20 ± 0.01^{c}, 23.47 ± 0.01^{c}) and group F (8.08 ± 0.00^{c}, 7.50 ± 0.01^{c}, 11.1 ± 0.00^{b}, 39.25 ± 0.03^{c}) respectively. These values were significantly different ($P< 0.05$) from group A. Mice in group B had the highest value. There

was increase in the MCV (Mean Corpuscular Volume) values of mice in groups E (54.48±0.21[b]) and F (55.11±0.01[a]) compared to the group A (21.82±0.02[f]) and group B (53.84±0.03[c]).However, MCV of mice in groups D,E and F was not significantly different (P< 0.05) from mice in group B. There was increase in MCV (Mean Corpuscular Hemoglobin) and MCHC (Mean Corpuscular Hemoglobin Concentration) values for all mice in groups D, E and F. These values were significantly different from the group A except for the mice in group B (chloroquine treated group) which exhibited increase in the values. Mice in group A exhibited lowest values of HGB, PLT, RBC, MCH, MCV, MCHC, and PCV.

Biochemical analysis in mice is shown in Fig. 2. There was increase in the level of ALT (Alanine Transaminase) and AST (Aspartate Transaminase) in group A (infected and not treated) these values are (111.70±0.21[a] and 227.17±0.60[a]) respectively. ALT and AST for mice in group D, E and F are, (86.13±0.13[c], 161.27±0.03[b]), (81.40±0.31[d], 120.73±0.23[d]), (89.13±0.09[b], 142.70±0.21[c]) respectively while that of group B and C are (65.90±0.49[e], 114.80±0.17[e]), (30.23±0.39[f], 114.50±0.29[e]) respectively. Mice in group C have the lowest value of ALT and AST.

Histopathological examination carried out on the liver and kidney of experimental mice is indicated

Table 1. Hematological analysis of mice

Groups	PCV (%)	RBC (x10mc^3)	HGB (g/100 ml)	MCV	MCH	MCHC	PLT
A	3.14±0.01[d]	6.14±0.03[d]	3.10±0.01[e]	21.82±0.02[f]	10.97±0.06[e]	25.89±0.01[e]	17.31±0.02[e]
B	12.74±0.02[b]	8.42±0.01[b]	6.71±0.01[d]	53.84±0.03[c]	21.73±0.01[a]	46.83±0.03[a]	2217.52±0.03[b]
C	41.15±0.03[a]	19.14±0.03[a]	13.52±0.02[a]	49.07±0.07[e]	16.02±0.01[b]	32.70±0.01[b]	4488.60±0.01[a]
D	4.27±0.01[d]	6.21±0.01[d]	9.10±0.01[c]	50.81±0.00[d]	14.45±0.03[d]	26.64±0.02[d]	18.46±0.03[e]
E	8.02±0.01[c]	7.01±0.01[c]	9.20±0.01[c]	54.48±0.21[b]	14.81±0.03[d]	29.16±0.05[c]	23.47±0.01[d]
F	8.08±0.00[c]	7.50±0.01[c]	11.1±0.00[b]	55.11±0.01[a]	15.31±0.01[c]	29.73±0.03[c]	39.25±0.03[c]

Data are presented as Mean ± S.E (n = 3). Values with the same superscript letter(s) along the same column are not significantly different (P<0.05).
KEY: Group A = Infected and untreated, Group B = Infected and treated with Chloroquine, Group C = Not infected and not treated, Group D = 200 mg/kg of seed extract, Group E = 400 mg/kg of seed extract, Group F= 600 mg of seed extract

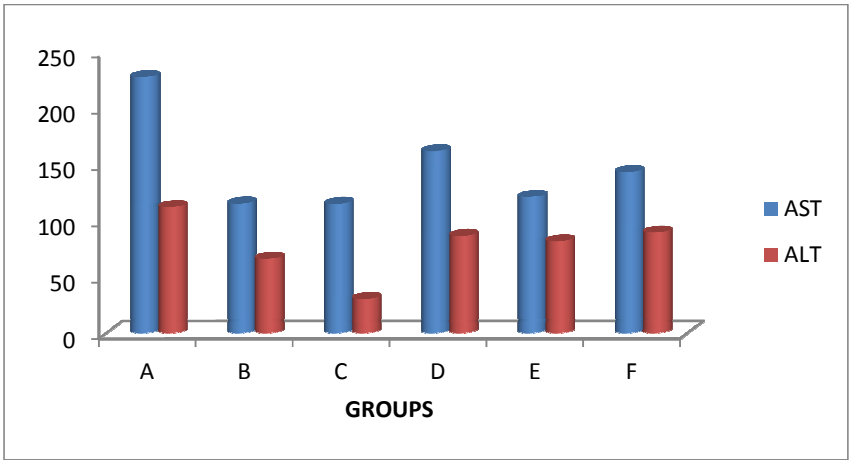

Fig. 2. Biochemical assay
Data are presented as Mean±S.E (n=3). Values with the same superscript letter(s) along the same column are not significantly different (P<0.05).
KEY: Group A = Infected and untreated, Group B = Infected and treated with Chloroquine, Group C = Not infected and not treated, Group D = 200 mg/kg of seed extract, Group E = 400 mg/kg of seed extract, Group F= 600 mg/kg of seed
AST = Aspartate Transaminase
ALT = Alanine Transaminase

on Plates 1-12. The liver of mice in the negative control, (group A) was observed to be characterized with high vacuole formation in the parenchyma (Plate 1). The liver of the mice administered with 5mg/kg of chloroquine showed low level of vacuole formation. (Plate 2). The liver of the normal group of mice fed with pellets and water was observed to show a well-arranged and intact hepatocytes, normal hepatic tissues, hepatocytes with granular cytoplasm (Plate 3). The liver of the mice administered with 200mg/kg of *T. conophorum* seed extract showed vacuolation in parenchyma and increase in basophilic content of the hepatocytes (Plate 4). The liver of mice administered with 400 mg/kg of *T.conophorum* seed extract showed more intact parenchyma tissue of the liver (Plate 5). However, the liver of experimental mice administered the highest dose of the seed extract (600 mg/kg) was characterized with hyperchromatic liver cells, loss of hepatic morphometric appearances with fatty infiltration. (Plate 6).

The kidney of mice of mice in group A (infected and not treated) was characterized with glomerular swelling tightly filling the Bowman's capsule, degeneration of distal and proximal tubules, renal parenchymal vacuolation, necrosis in the glomerulus and cellular proliferation in mesengial area (Plate 7). Mice in group B (chloroquine treated group) showed vacuole formation in the cortex with glomerulus filling the Bowman's space (Plate 8).While the examination of kidney of the mice in group C (normal control group) showed normal kidney histology (Plate 9). Mice in group D (200 mg/kg body weight of extract) showed renal cortex containing high fatty cell infiltration, area of necrosis is observed at collecting tubules and karyolysis of macula densa (Plate 10) For mice in groups E and F (administered with 400 mg/kg and 600 mg/kg body weight of the extract) more intact distal tubules and proximal tubule were observed (Plates 11 and 12).

4. DISCUSSION

Recent study on "*In vivo* antiplasmodial activity of ethanolic seed extract of *Tetracarpidium conophorum* in swiss albino mice infected with *Plasmodium berghei* revealed that the seed extract at the dose of 600 mg/kg (highest dose) exhibited the highest antiplasmodial effect compared to other dose levels used (200 and 400 mg/kg).

Findings from this study which revealed an increase in the levels of blood parameters (HGB (hemoglobin), PCV (Packed cell volume, RBC (Red blood cells) in the mice administered different concentrations of the seed extracts (groups D to F) compared with group A mice (infected and not treated) is in contrast with the findings of Apeh et al. [22] who reported decrease in the levels of Hemoglobin, Packed cell volume, Red blood cells in mice fed with *T. conophorum* seed extract and attributed it to the presence of cyanide which might have hindered the formation of the hematological indices in mice.

Histopathological Studies:

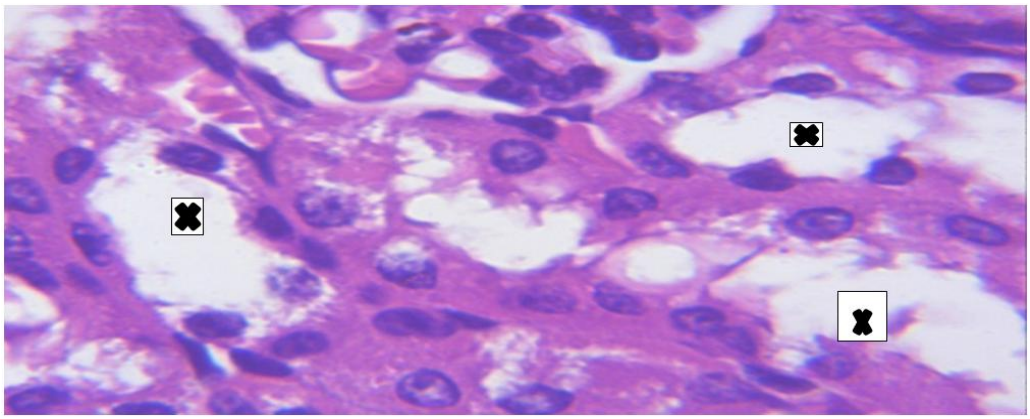

Plate 1. Photomicrograph of liver of albino mice infected with *Plasmodium berghei* untreated (negative control group A) showing change in liver morphology with high vacuole formation in the parenchyma. H&E (X40)

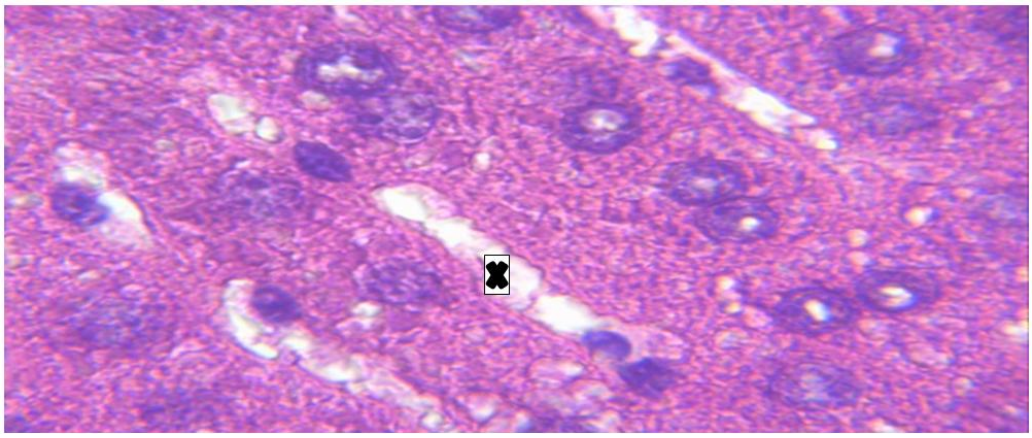

Plate 2. Photomicrograph of a liver section of liver of mice infected with *Plasmodium berghei* and treated with chloroquine at 5 mg/kg body weight (Positive control group B), the hepatocytes showed small level of vacuole formation. H&E (X40)

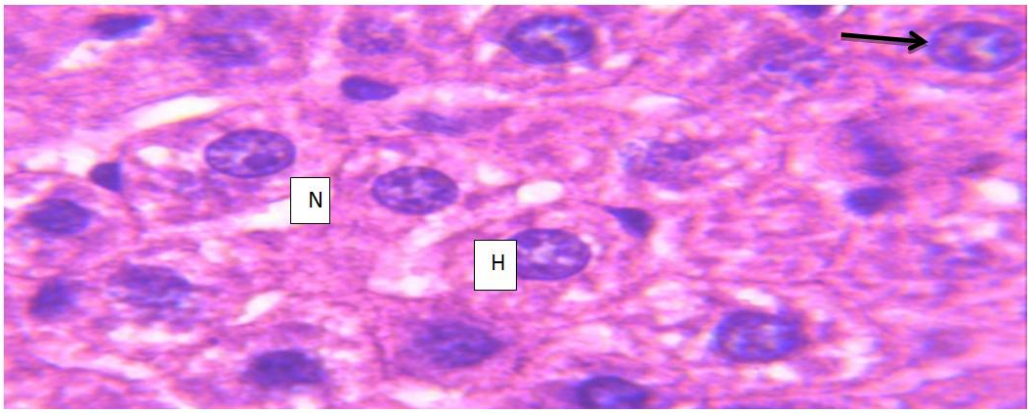

Plate 3. Photomicrograph of Liver of (normal control group C) not infected and not treated, the section depicts normal morphology of the liver with well-arranged and intact hepatocytes (normal hepatic tissue (N), showing hepatocytes (H) with granular cytoplasm (arrow). H&E (X40)

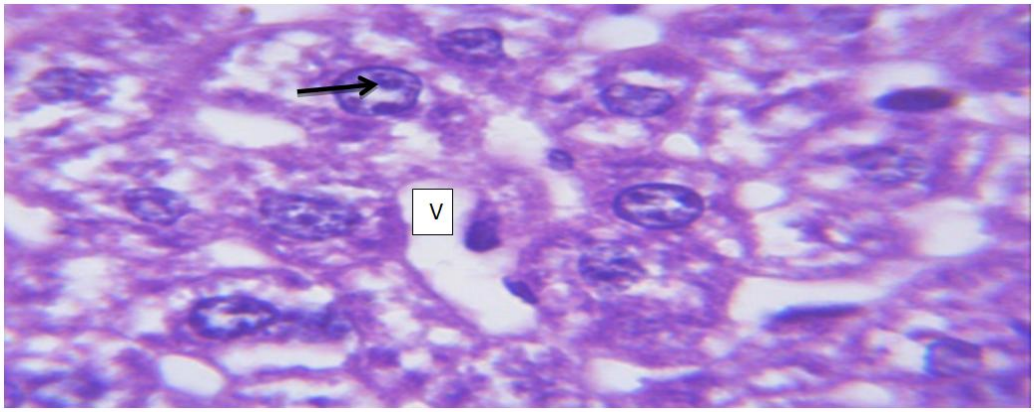

Plate 4. Photomicrograph of liver of albino mice infected with *Plasmodium berghei* and treated with 200mg/kg of seed extract (group D) showing level of vacuolation in the parenchyma (V), there is increase basophilic content of the hepatocytes (arrow). H&E (X40)

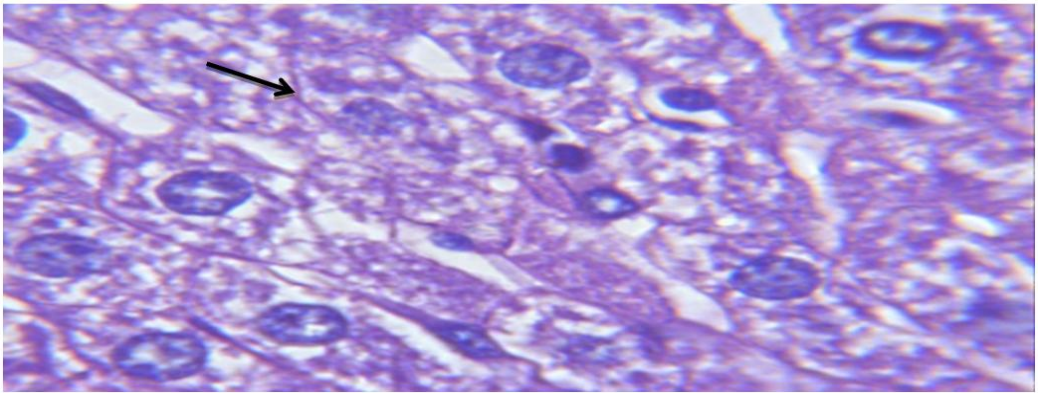

Plate 5. Photomicrograph of liver of albino mice infected with *Plasmodium berghei* and treated with 400 mg/kg of seed extract (group E) showing more intact parenchyma tissue of the liver (arrow). H&E (X40)

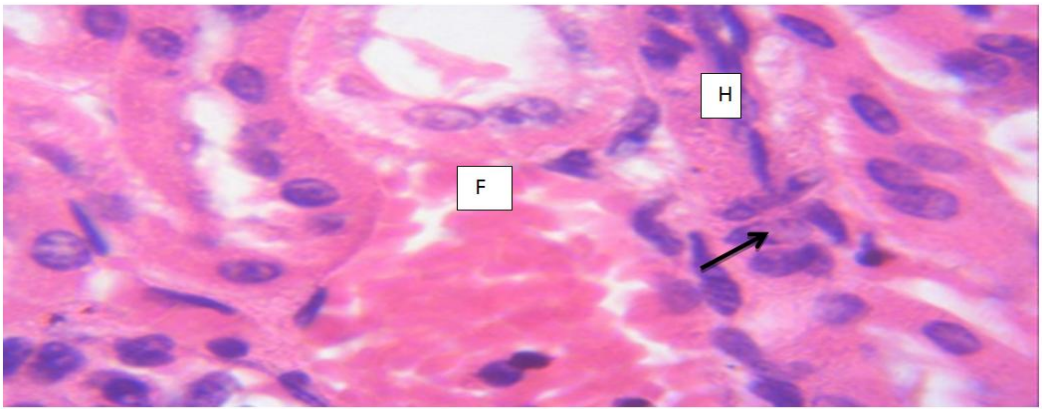

Plate 6. Photomicrograph of Liver of albino mice infected with Plasmodium berghei and treated with 600 mg/kg of seed extract (group F) shows hyperchromatic liver cells (arrows) sectioning showed loss of hepatic morphometric appearances(H) with fatty infiltration (F) H&E (X40)

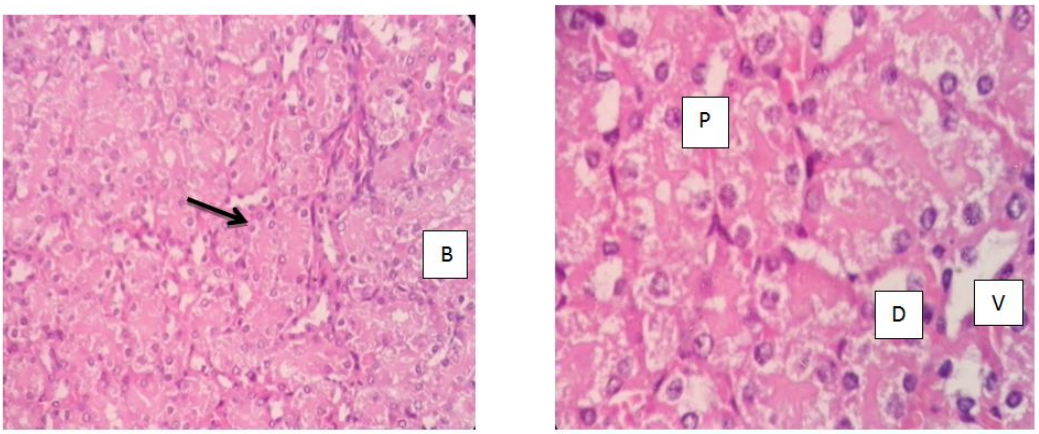

Plate 7. Photomicrograph of a transverse section of the kidney of mice after infected and not treatment, it shows glomerular swelling (arrowed) tightly filling the Bowman's capsule (B), degeneration of distal (D) and proximal tubules (P) renal parenchymal vacuolation (V), necrosis in the glomerulus and cellular proliferation appear in mesengial area. (HE) stain (X 40&100)

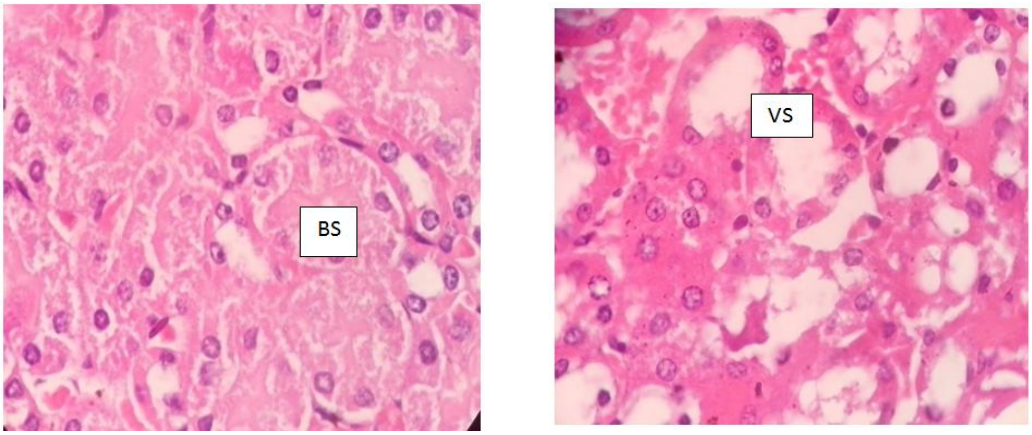

Plate 8. Photomicrograph of a transverse section of the kidney of mice after treatment with 5 mg/kg of chloroquine. It shows is vacuole space formation in the cortex (VS) with glomerulus filling the Bowman's space (BS).(HE) stain (X40&100).

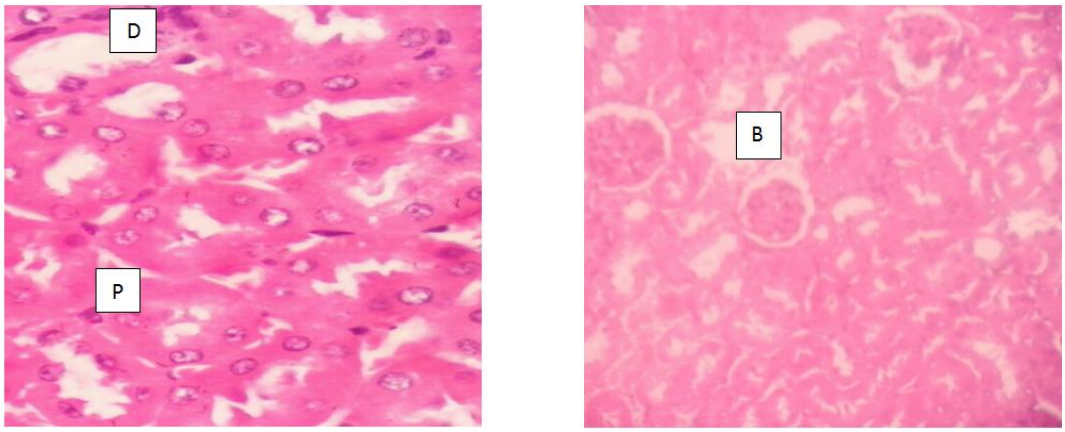

Plate 9. Photomicrograph of a transverse section of the kidney of mice in the normal control group (group C). It shows glomerulus filling the Bowman's space (BS).The Proximal (P) and Distal(D) Convoluted tubule is intact(HE) stain (X40&100)

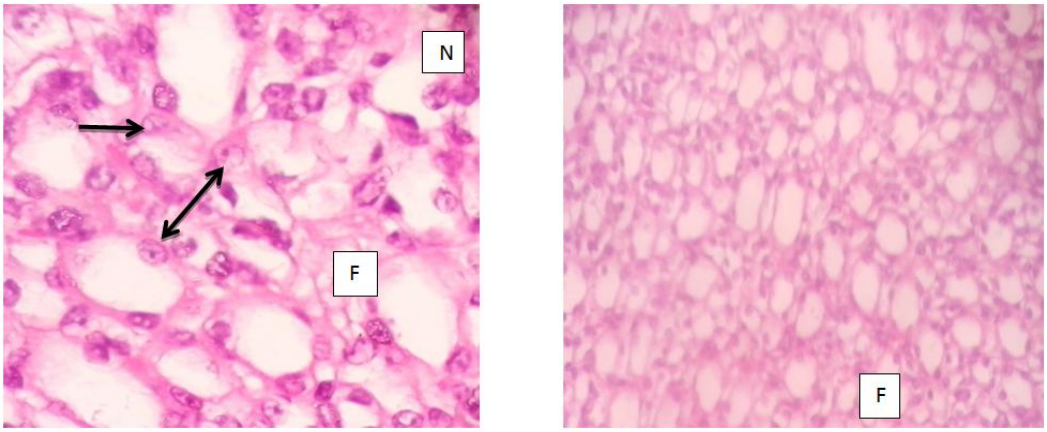

Plate 10. A photomicrograph of a section in the renal cortex of a mice infected with *plasmodium berghei* and treated with 200 mg/kg of *T. conophorum* seed extract showing renal cortex containing high fatty cell infiltration (F) and area of necrosis is observed at collecting tubules(N), karyolysis of macula densa (arrowed)

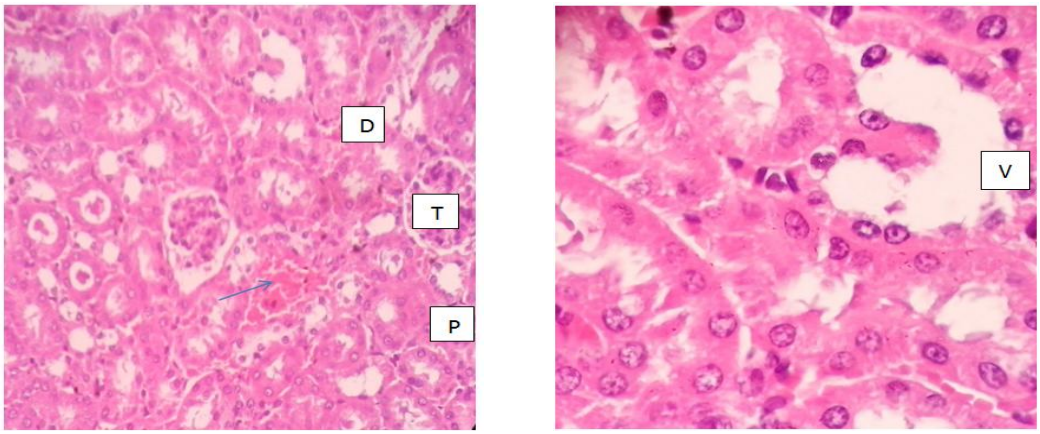

Plate 11. A photomicrograph of a section in the renal cortex of a mice infected with *Plasmodium berghei* and treated with 400 mg/kg of *T. conophorum* seed extract showing renal corpuscles consisting of lobulated glomeruli (T) tightly occupying the Bowman's capsules, Proximal (P) and distal (D) convoluted tubules are also seen still intact however there vacuole formation (V)

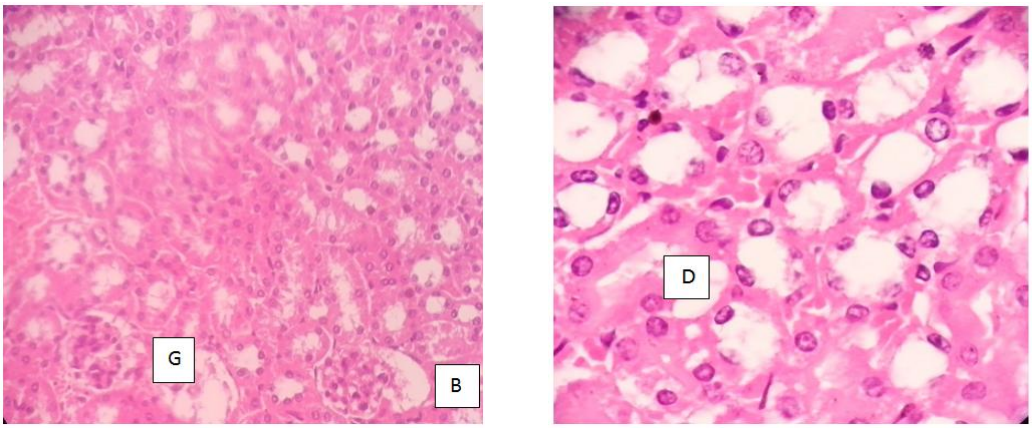

Plate 12. A photomicrograph of a section in the renal cortex of a mice infected and treated with 600 mg/kg of *T. conophorum* showing renal corpuscles consisting lobulated glomeruli (G) undergoing some degeneration and Bowman's capsules (B) and Proximal (P) and distal (D) convoluted tubules are also seen still intact

Decrease in the values of HGB, RBC and PVC observed in the negative control group is expected and could probably be due to anemia as reported by Chang and Stevenso, [23].

Increase in the level of AST (Aspartate Transaminase) and ALT (Alanine Transaminase) observed group A (mice infected and not treated) and increase in ALT observed in group F (mice administered with the highest dose of the seed extract) could be attributed to the reason suggested by Ojo et al. [24] that very high level of AST and ALT are usually due to liver disorder or decreased blood flow to the liver caused by malaria infection. However, decrease in the ALT and AST in the mice administered 400 mg/kg (group E) could be as a result of hepatoprotective and nephroprotective ability of the seed extract and decreased AST level observed in mice administered 600 mg/kg (group F) concentration of the seed extract could be due to the nephroprotective ability of the extract at that dose. This reason was advanced by Atawodi et al. [25] who, on serum biochemistry of mice administered *Dodonaea angustifolia* reported decrease in the levels of AST and ALT in mice.

The change in liver morphology with high vacuole formation in the parenchyma observed in mice infected and not treated (group A) is expected and was reported to be due to cellular trauma and morphological change in the tissue architecture, a normal reaction of the liver tissue to infection. This is in agreement with the findings of Innocent et al. [26] who reported change in the morphology of parenchyma tissue of the liver, hyperplasia and high vacuole formation in the liver of mice infected with *Plasmodium berghei.*

Normal morphology of the liver with well-arranged parenchyma tissues of the liver and intact hepatocytes observed in the normal control group (group C) and group E (administered 400 mg/kg of seed extract) is expected. It could be due to the restorative effect of the seed extract on the liver. This is in line with the findings of Syed et al. [27] who on the Hepatoprotective and Nephroprotective activity of *Phyllanthus amarus* seed extract reported that the liver of wistar rat showed a normal morphology and intact hepatocytes. Hyperchromatic liver cell with fatty infiltration observed in mice administered 600 mg/kg body weight of the extract could be due to the accumulation of fat in the liver of the mice, as *T.conophorum* seed extract has been reported to contain high fat content which could be a health risk factor [28].

The glomerular swelling, degeneration renal parenchymal vacuolation, necrosis in the glomerulus and cellular proliferation appear in mesengial area, which are signs of renal toxicity observed in the liver of mice infected and not treated (group A) is expected. This could be due to the free hemoglobin which catalyzes oxidative damage, hypoxia and lactic acidosis, promoting metabolic acidiosis which is aggravated by the altered renal function that is observed in patients with malaria [29]. This agrees with the findings of Basir et al. [30] who reported vacuolation in the tubules, necrosis in glomerulus of mice infected with *Plasmodium berghei*. The distinct glomerulus, well intact proximal and distal tubules observed in group E (treated with 400 mg/kg seed extract) and F (treated with 600 mg/kg seed extract) suggests that the seed extract of *T.conophorum* improved the structure of the kidney. This agrees with the findings of Ezejindu et al. [31] who reported that the leaf extract of *Moringa oleifera* did not produce adverse effect on the kidney of experimental animals.

5. CONCLUSION

The seed extract at 400 mg/kg when administered to the mice was observed to have restorative effects on the liver and kidney of the mice. However, the 600 mg/kg restored the kidney but had adverse effect on the liver. Hence, *Tetracarpidium conophorum* seed extract at the dose of 400 mg/kg could be considered suitable to treat human malaria infection.

The Federal government should pay close attention to its cultivation and more efficient preservation procedures to achieve round the year availability of this very important seeds.

COMPETING INTERESTS

Authors have declared that no competing interests exist.

REFERENCES

1. WHO, World Malaria Report. Geneva. Switzerland; 2015;99-110.
2. Rabiou L, Thierry F, Isabelle J, Cyril C, Earle W, Ibrahim A, Jean-Bernard D. Ecology of marban malaria vectors in niamey, Republic of Niger. Malaria Journal. 2016;15:314-316.
3. Getie A. Evaluation of antimalarial activity of seeds of *Dodonea augustifolia* against *Plasmodium berghei* in Swiss albino Mice. Addis Ababa University, Ethiopia. 2013;1-26.
4. Janet CS, Timothy ME, Davis KSL, Sunita SGS, Asmad M, Shanmuga R, Hasan AR, David JC, Balbir S. Malaria in humans is widely distributed and potentially life threatening. Clinical Infectious Disease. 2008;46(2):165.
5. Andare- Neto VF, Goulart MF, Silva Felho JF, Pinto MFR. Antimalarial activity of pphenazines from lapachol, B-lapachone and its derivatives against *Plasmodium falciparum In vitro* and *Plasmodium berghei In vivo*. Bio-organic Medicine. 2014;14:1145-1149.
6. Berendt AR, Tumer CDH, Newbold CL. Cerebral malaria: The sequestration hypothesis. Parasitology Today. 2014; 10(10):412-414.
7. Phillipson JB, O'Neil MJ, Wright CW. Warhurst DC. Plants as sources of

antimalarial and amoebicidal compounds. Medicinal and poisonous plants of the tropics. Proceedings of symposium of the 14th International Botanic Congress. Berlin, Pudoc, Wageningen; 2014.

8. Atetetgeb K, Hassen M. Antimalarial properties of crude extracts of seeds of *Brucea antidysenterica* and leaves of *Ocimum lamidolium.* Complement Alternative Medicine. 2016;12:16-18.
9. Obianine AW, Uche FL. The effects of aqueous extracts of *Tetracapiduim conophorum* seeds on the hormonal parameters of male guinea pigs, (E-ed) Elesevier, Singapore; 2010.
10. Wikipedia. African walnut from free encyclopedia; 2008.
11. Hunt S, Golf JL, Holbrook J. Nutrition principles and chemical practices. John Wiley and Sons New York: 1980;49-52.
12. Okwu DE, Okwu ME. Chemical composition of *Saponidiamombin* plants. J. Sustainable Agricultural Environment. 2004;6:140–147.
13. Kaneto H, Kajimoto Y, Miyagawa J, Matuoka T, Fujitani Y. Umayahara,. Y, Hanafusa T, Matsuzawa Y, Yamasaki Y, Hori M. Beneficial effect of antioxidants in diabetes: Possible protection of pancreatic beta-cells against glucose toxicity. Diabetes. 2014;48(12):2398-2406.
14. Adeneye AA. Haematopoetic effect of methanol seed extract of Citrus paradise Macfad (grape fruit) in Wistar rats. Biomedical Research, 2008;19(1):23-26.
15. Berhan M, Eyasu M, Kelbessa, U. *In vivo* antimalarial activity of *Dodonaea augustifolia* seed extracts against *Plasmodium berhei* in Mice Model. CNCS Mckelle University. 2012;4(1):47-63.
16. Akhila JS, Lwar MC, Shyamjith. Acute toxicity studies and determination of median lethal dose. Current Science. 2007;93(7):10.
17. Hayashi K, Nakagama Y, Horio F, Uchida K, Osawa T. Antiplatelet and anticancer isothiocyanates in Japanese horseradish, wasabi. Bio Factors. 2000;13:271–276.
18. Hilou A. Nacoulma OG, Gulguemde TR. *In vivo* antimalarial activities of extracts from *Amaranthus spinosis* L. and *Boerhaavia erecta* L. in mice. *Journal of Ethnopharmacology.* 2006;103:236-240.
19. Moody A. Rapid diagnostic tests for malaria parasites. Clinical Microbiology Review. 2010;15:66-78.
20. World Health Organization. Malaria microscopy quality assurance manual. Version. 2009;1:5-10.
21. Yerbanga RS, Koama BK, Matsabisa JB, Ouedraogo JB, Ouedrago GA. Evaluaton of the antiplasmodial activity and lethality of the Leaf Extract of *Cassia alata* L. (Fabaceae). Paskitan Journal of Biological Sciences. 2016;19:171-178.
22. Apeh VO, Agu CV, Ogugua PN, Uzoegwu EG, Anaduaka TE, Agbalu IS. Effect of cooking on proximate, phytochemical constituents and hematological parameters of *Tetracarpidium conophorum* in mlae albino rats. European Journal of Medicinal Plants. 2014;4(12):1388-1399.
23. Chang KH. Stevenso MM. Malarial anemia: Mechanism and implications of insufficient erythropoiesis during blood-stage malaria. International Journal of Parasitology. 2014;24:1501-16.
24. Ojo OO, Nadro MS, Tella IO. Protection of rats by extracts of somecommon Nigerian trees against acetaminophen-induced hepatotoxicity. African Journal Biotechnology. 2006;5(9):755-760.
25. Atawodi SE, Nuratu A, Bature EI, Isah MA. Lipid profile, haemoglobin level and antioxidant effect of pre- treatment with Methanolic extract of *Byrsocarpus coccineus* Shum & Thonn. Leaf against Carbon Tetrachloride-Induced injuries to liver, kidney and heart of rats. British Biotechnology Journal. 2014;4(12).
26. Innocent AE, Inyang AA, Rosemary BB, Enobong IB, Sediongde JU. Erythropoeitic and hepatoprotective potential of etahnolic extract of *Nauclea latifola* in mice infected with *Plasmodium berghei.* American Journal of Medical Sciences and Medicine. 2014;2(10):7-12.
27. Syed AB, Iqbal MM, Ibrahim MD. hepatoprotective and nephroprotective activity of *Phyllanthus anmarus* Schum & Thonn. Seed extract. Annals of Phytomedicine. 2012;1(2):97-104.
28. Hassan LG, Umar KJ. Nutritive value of balsam apple (*Momordica balsanina* L) leaves. Pakistan Journal of Nutrition. 2007; 5(6):522–529.

29. Renia L, Howland S, Claser C, Charlotte Gruner A. Cerebral malaria: Mysteries at the blood-brain barrier. Virulence. 2012; 3(2);193-201.

30. Basir R, Fazalul Rahiman SS, Hasballah K, Chong WC, Talib H, Yam MF, Jabbarzare M, Tie TH, Othman FM, Moklas MA, Abdullah M, Ahmad Z. *Plasmodium berghei* ANKA infection in ICR mice as a model of cerebral malaria. Iran Journal Parasitology. 2012;7(4):62-74.

31. Ezejindu DN, Udemezue OO, Akingboye AJ. Protective effects of *Moringa oleifera* leaf extracts on the kidneys of adult wistar rats. American Journal of Engineering Research. 2014;3(2):157-16.

© 2017 Ogundolie et al.; This is an Open Access article distributed under the terms of the Creative Commons Attribution License (http://creativecommons.org/licenses/by/4.0), which permits unrestricted use, distribution, and reproduction in any medium, provided the original work is properly cited.

Peer-review history:
The peer review history for this paper can be accessed here:
http://sciencedomain.org/review-history/19608