Research Square

Preprints are preliminary reports that have not undergone peer review.
They should not be considered conclusive, used to inform clinical practice,
or referenced by the media as validated information.

Anticoccidial effect of "Shi Ying Zi" Powder in chickens infected with *Eimeria tenella*

Xu Song
Sichuan Agricultural University
Yunhe Li
Sichuan Agricultural University
Yaqin Chen
Sichuan Agricultural University
Renyong Jia
Sichuan Agricultural University
Yongyuan Huang
Sichuan Agricultural University
Ting Yong
Sichuan Agricultural University
Yuanfeng Zou
Sichuan Agricultural University
Lixia Li
Sichuan Agricultural University
Xinxin Zhao
Sichuan Agricultural University
Zhongqiong Yin (yinzhongq@163.com)
Sichuan Agricultural University

Research

Keywords: Anticoccidial drug, Coccidiosis, Shi Yin Zi powder

Posted Date: December 11th, 2019

DOI: https://doi.org/10.21203/rs.2.18694/v1

License: This work is licensed under a Creative Commons Attribution 4.0 International License. Read Full License

Abstract

Background

Coccidiosis is one of the most economically important diseases affecting the poultry industry. Currently, anticoccidial drugs used in veterinary clinical showed many deficiencies, and new control measures are urgently needed. Many plant-derived drugs, such as herbal extracts, showed effects with less drug residues and resistance. Development of herbal medicine as the anticoccidial drug is one of the most prospective method for treating coccidiosis.

Methods

“Shi Ying Zi” powder is consisted of *Cnidium monnieri* (L.) Cuss, *Taraxacum mongolicum* Hand-Mazz and salt with the proportion of 55: 40: 5 (g/g/g). 200 1-day-old broiler chicks free of coccidiosis were equally divided into 10 groups: normal group, untreated group, 4 protective groups (positive control group and three “Shi Ying Zi” powder groups) and 4 therapeutical groups (positive control group and three “Shi Ying Zi” powder groups). At 11th day of age, the chicks in the four protective groups were prophylactically supplemented with “Shi Ying Zi” powder at the doses of 5g/kg, 10g/kg and 15g/kg and monensin (100mg/kg), respectively. At 14th day of age, chicks except those in blank group were inoculated with 2×10^4 sporulated oocysts of *E. tenella*. When the first hemorrhagic fecal was found, therapeutical drugs started administration. The low (5g/kg), medium (10g/kg) and high doses (15g/kg) of “Shi Ying Zi” powder were added into the diet, respectively. Sulfachloropyrazine sodium (positive control) was added into water (1g/L). The anti-coccidial index, biochemical parameters and tissue lesions were determined from 4 d post infection to 8 d post infection.

Results

Supplement with “Shi Yin Zi” powder for 3d prior to infection or after infection could improve the survival rate and relative growth rate and alleviate the pathological changes in the cecum, liver and kidney. “Shi Yin Zi” powder could recover the contents of glutamic-pyruvic transaminase, creatinine, albumin and triglycerides in serum. The hemorrhage and total number of oocysts in feces were reduced. The anti-coccidial index reaches to 165. The anti-coccidial effects were equal to positive controls (monensin and sulfamlopyrazine).

Conclusions

“Shi Ying Zi” powder possesses potent anticoccidial effect and exhibits the potential to control *E.tenella* infection.

Introduction

Coccidiosis caused by seven species of intracellular protozoan parasites of the genus *Eimeria* is one of the most detrimental and lethal diseases of commercial poultry flocks [1]. It is a rapidly developing intestinal disease that presents with bloody diarrhoea and listlessness and can cause heavy mortality in affected flocks [2]. *Eimeria* oocysts are highly infectious and resilient, and easily transferred by animals, insects, dust, contaminated feed, water and equipment [3]. *Eimeria* oocysts typically invade intestinal epithelium cells and cause destruction of the infected cells, resulting in reduction of feed conversion, body weight gain, egg production, and increased morbidity and mortality [4]. Therefore, management of coccidiosis and maintenance of the immune functions for maximum performance, growth and production in poultry industry are fundamental requirements for profitable farming[5]. Thus far, chemoprophylaxis and anticoccidial feed additives are two typical methods for controlling the disease, but coccidiosis oocysts gradually show drug tolerance and eventually the phenomenon of survival and reproduction [6]. To prevent the emergence of drug resistance, new drugs have been developed and administered on a rotational basis with existing drugs; however, this has resulted in the increased cost of poultry products. Furthermore, drug or antibiotic residue in the poultry products is potentially annoyance to consumer [6]. In recent years, the anticoccidial drug development is slower than the emergence of drug resistant *Eimeria* spp., which has stimulated the search for new and alternative control methods for avian coccidiosis [7].

There are many plant-derived drugs with anticoccidial effects, such as herbal extracts [8-9]. Compared with chemotherapeutic drugs, herbal anticoccidials usually show less drug residues and less drug resistance [10]. *Cnidium monnieri* (L.) Cuss. is a widely used traditional herbal medicine in China, Vietnam and Japan, and its fruits have been used to treat a variety of diseases including female vulva pain, male impotence, epilepsy and ulcer [11]. *Taraxacum mongolicum* Hand-Mazz is a commonly used Chinese medicine to treat infection, fever, upper respiratory tract infection, pneumonia, and other infectious diseases [12]. These two herbals are recorded in the Pharmacopoeia of the People’s Republic of China. Based on the traditional Chinese veterinary medicine theory, unlike other herbal extracts, this study prepares a herbal formula “Shi Ying Zi” which is the powder of the mixture of *Cnidium monnieri* (L.) Cuss, *Taraxacum mongolicum* Hand-Mazz. and salt in the ratio of 55:40:5 (g/g/g). The anticoccidial effects of “Shi Ying Zi” powder were evaluated in chickens infected with *Eimeria tenella* through supplement for 3d prior to infection or after infection for determination of the preventive effect and therapeutic effect of “Shi Ying Zi” powder.

Methods

Preparation of “Shi Ying Zi” powder

“Shi Ying Zi” powder is consisted of *Cnidium monnieri* (L.) Cuss, *Taraxacum mongolicum* Hand-Mazz and salt with the proportion of 55: 40: 5 (g/g/g). The two herbals were procured from Baicaotang pharmaceutical chain Co. LTD (Chengdu, China). The samples of the two plant material (*Cnidium monnieri* (L.) Cuss and *Taraxacum mongolicum* Hand-Mazz) are deposited at the herbarium of Natural medicine research center, College of Veterinary medicine, Sichuan Agricultural University, with voucher number 2017-0168 and 2017-0205, respectively. The quality criteria of the two herbals were fit for the standards of the Pharmacopoeia of the People's Republic of China (Version 2015, China pharmacopoeia committee).The content of osthole in *Cnidium monnieri* (L.) Cuss is not less than 1% and the content of caffeic acid is not less than 0.02% in *Taraxacum mongolicum* Hand-Mazz. The mixture of *Cnidium monnieri* (L.) Cuss, *Taraxacum mongolicum* Hand-Mazz and salt were smashed into powder, followed by sieving through 150μm ± 6.6μm screen cloth to give the “Shi Ying Zi” powder.

Experiment design

200 1-day-old broiler chicks free of coccidiosis were purchased from a local hatchery and equally divided into 10 groups which contained normal group, untreated group, 4 protective groups (positive control group and three “Shi Ying Zi” powder groups) and 4 therapeutical groups (positive control group and three “Shi Ying Zi” powder groups). Chicks were reared in poultry shed and maintained free from coccidian infection and anticoccidial drug

At 11th day of age, the chicks in the three “Shi Ying Zi” powder groups were prophylactically supplemented with “Shi Ying Zi” powder at the doses of 5g/kg (ShiYingZi-PL), 10g/kg (ShiYingZi-PM) and 15g/kg (ShiYingZi-PH), respectively. In the positive control group, monensin was added (100mg/kg). The normal group and untreated group were fed with normal diet. At 14th day of age, chicks except those in blank group were inoculated with 2×10^4 sporulated oocysts of *E. tenella*. When the first hemorrhagic fecal was found, therapeutical drugs started administration. The low (5g/kg, ShiYingZi-TL), medium (10g/kg, ShiYingZi-TM) and high doses (15g/kg, ShiYingZi-TH) of “Shi Ying Zi” powder were added into the diet, respectively. In the positive control group, sulfachloropyrazine sodium was added into water (1g/L).

Clinical symptoms

The chicks were examined daily for recording clinical signs, such as ruffled feathers, anorexia, huddling together, ruffled feathers, loose dropping, hemorrhagicy feces, and mortality.

Hemorrhagic fecal score

Hemorrhagic fecal score is a qualitative estimation of the deviation of fecal appearance from normal. They were obtained by scoring the fecal each morning from 4dpi to 8dpi. Hemorrhagic fecal score was made from 0 to 4: a score of 0 indicates normal fecal without hemorrhagic, a score of 1 indicated 1%-25% fecal with hemorrhagic; a score of 2 indicated 25%-50% fecal with hemorrhagic; a score of 3 indicated 51%- 75% fecal with hemorrhagic; a score of 4 indicated 76%-100% fecal with hemorrhagic.

Lesion score of caecum

The postmortem examination was conducted on 8dpi. The dead and slaughtered birds were incised, and gross lesions in caecum were recorded. The pathogenicity and severity of the disease was studied by recording lesion scoring, which was evaluated based on extent of lesions in a particular organ as described by Johnson and Reid [13]. The lesions included petechial hemorrhages, thickening of caecum wall, hemorrhagic fecal contents, and mucoid discharge. Lesion score was made from 0 to 4: a score of 0 indicated no lesion; a score of 1 indicated mild lesion; a score of 2 indicated moderate lesion; a score of 3 indicated severe lesion; a score of 4 indicated more severe lesion.

Oocysts index in caecum

Caecum contents were collected on 8dpi after postmortem examination. The counting of oocysts was made by McMaster method [14]. The score was made from 0 to 40: a score of 0 indicated the oocysts in feces were 0-0.1×10^6，a score of 5 indicated the oocysts in content were 0.11×10^6-1×10^6，a score of 10 indicated the oocysts in content were 1.1×10^6-1.9×10^6，a score of 20 indicated the oocysts in content were 2.0×10^6-5.9×10^6，a score of 30 indicated the oocysts in content were 6.0×10^6-10.9×10^6，a score of 40 indicated the oocysts in content were more than 1.1×10^7

Anti-coccidiosis index

Anti-coccidiosis index（ACI）=（Relative weight gain rate + Survival rate）-（Oocysts index in caecum + Gross lesions score）[15].

When ACI is larger than 180，it means the anti-coccidiosis drug is high efficiency; when ACI is 160-180, it means the anti-coccidiosis drug is medium efficiency; when ACI is 120-160, it means the anti-coccidiosis drug is low efficiency, and when ACI is lower than 120, it means the drug do not possess anti-coccidiosis efficiency.

Biochemical indexes

For biochemical studies, 3–4 ml blood was collected from randomly selected 5 chicks of each group into tubes without any anticoagulant at intervals 0, 4 and 8dpi. After clotting, serum was separated and various parameters were estimated, including total serum protein, albumin, aspartate

aminotransferase and alanine aminotransferase, serum creatinine and serum triglyceride. The globulins were calculated by subtracting the values of albumin from total serum proteins.

Histopathology

After dissection, the caecum, liver, kidney tissue samples were excised, fixed with neutral buffered formalin (10%), and then embedded in paraffin. Approximately 4 μm thick cross sections were excised and stained with hematoxylin and eosin (HE) for histopathological examination.

Result

Clinical symptoms and mortality

After challenged with *E. tenella*, the clinical signs and symptoms were closely monitored throughout the trial. The clinical signs, including dullness, anorexic and loose dropping, were first observed in the untreated group at 3dpi. The symptoms in ShiYingZi-treated groups of protective administration were observed at 4dpi, which is similar with untreated group, but much milder than untreated group. Mortality of untreated group was highest in all groups. Appearance of hemorrhage in feces was noted on 4dpi in untreated group and many oocysts were found in caecum, suggesting the model was successfully established. Pretreatment with “Shi Ying Zi”, bloody stools were detected on 5dpi.

E. tenella infection induced 25% mortality rate in the untreated group. Pretreatment only caused 5% mortality rate in the ShiYingZi-PL group and ShiYingZi-PH group. There were no mortality in the ShiYingZi-PM group and monensin group (**Table 1**). When the drugs were supplemented after infection, the mortality rates were 10% in the ShiYingZi-TL group and 5% in the ShiYingZi-TM group. In the ShiYingZi-TH group and sulfachloropyrazine sodium group, there were no mortality (**Table 1**).

Anticoccidial efficacy

Hemorrhagic fecal score (**Table 2**) and the total number of oocysts per gram of feces (**Table 3**) were measured from 4dpi to 8dpi. Pretreatment and therapeutical administration could alleviate the hemorrhage in feces and accelerate recover from bloody stool. The number of oocysts shedding in feces were also reduced by the two routes.

Coccidiosis induced decreased weight gain, and the relative weight gain rate is 53% compared with normal group (**Table 4**). ShiYingZi-pretreatment could recover the relative weight gain rate up to 86% compared with normal group, which is better than monensin (77%). With treatment with ShiYing Zi, the relative weight gain rate could reach to 77% in comparison with untreated group. The gross lesions score and caecum oocyst index were decreased after pretreatment or treatment with “Shi Ying Zi” powder and the positive controls. Pretreatment with “Shi Ying Zi” powder at the dose of 10g/kg showed highest anti-coccidiasis activity that the ACI was 165, which is higher than monensin (159)

Biochemical indexes

The contents of total protein (**Table 5)**, albumin (**Table 6)** and triglyceride (**Table 11)** were significantly decreased after infection on 4dpi and 8dpi ($p < 0.05$), but they were significantly ($p > 0.05$) increased after pretreatment or treatment with “Shi Ying Zi” powder and positive controls. Serum globulin concentrations (**Table 7**) in the infected chicks with or without treatment were significantly ($P<0.05$) increased on 4dpi and 8dpi, no significant difference was observed among all the infected chicks. The contents of glutamic-pyruvic transaminase (**Table 8)**, and creatinine (**Table 10)** in the infected chicks were significantly increased on 4dpi and 8dpi ($P<0.05$), after pretreatment or treatment, they were significantly decreased ($P<0.05$). Coccidiosis induced significantly ($P<0.05$) increased content of aspartate aminotransferase on 4dpi and 8dpi (**Table 9),** after pretreatment or treatment, it was significantly decreased on 8dpi ($P<0.05$).

Histopathological examination

In the caecum, oocysts invaded caecum mucosa and intestinal gland (**Fig.1B**) and serious karyopyknosis and necrocytosis were detected in caecum mucosa cell; In the ShiYingZi-PM group (**Fig.1C**), ShiYingZi-TH group (**Fig.1E**) and positive control groups (**Fig.1D**, monensin; **Fig.1F**, sulfachloropyrazine sodium), few oocysts were observed in caecum mucosa cell, and the caecum mucosa cell appeared granular and vacuolar degeneration; in the uninfected group (**Fig.1A**), caecum showed the normal structure.

In the liver, *E.tenella* infection induced serious hepatocyte necrosis and inflammatory cell infiltration (**Fig.1H**); granular and vacuolar degeneration appeared in ShiYingZi-PM group (**Fig.1I**), ShiYingZi-TH group (**Fig.1K**) and positive control groups (**Fig.1J**, monensin; **Fig.1L**, sulfachloropyrazine sodium); without infection, liver showed the normal structure (**Fig.1G**).

In the kidney, serious granular and vacuolar degeneration and cell necrosis were observed in the untreated group (**Fig.1N**); few granular and vacuolar degeneration were observed in the ShiYingZi-PM group (**Fig.1O**), ShiYingZi-TH group (**Fig.1Q**) and positive control groupS (**Fig.1P**, monensin; **Fig.1R**, sulfachloropyrazine sodium); more inflammatory cell infiltration was observed in the sulfachloropyrazine sodium group (**Fig.1R**) than that in the ShiYingZi-TH group (**Fig.1Q**); without infection, kidney showed the normal structure (**Fig.1I**).

Discussion

Coccidiosis is one of most economically important diseases, but in common used anticoccidiosis drugs often cause drug residue in meat and eggs [16]. This study provides a new herbal drug candidate “Shi Ying Zi” for treating coccidiosis, and the potency is equal to monensin and sulfamlopyrazine. Unlike other herbal medicine, “Shi Ying Zi” don’t need any extraction process and it is the powder of *Cnidium monnieri* (L.) Cuss, *Taraxacum mongolicum* Hand-Mazz and salt. Therefore, it is more financially acceptable, which is the one of the most important point for drugs used in poultry industry. This study revealed that “Shi Ying Zi” powder administrated through two routes, showed potent anticoccidial effect, suggesting that it could be used as prophylactic drug or therapeutic drug. For pretreatment, the recommended dosage of “Shi Ying Zi” powder is 10 g/kg; for treatment, it is 15g/kg.

Coccidiosis usually reduces body weight gain in broiler chicks as a result of reduced feed intake, digestibility and absorption of macronutrients [17]. It is accepted that weight gain is the more sensitive variable to coccidiosis and anticoccidial treatments [18]. When infective sporozoites enter the caecum mucosa by penetrating villus epithelial cells, leading to extensive destruction of the caecum epithelium, hemorrhagic feces output and a large number of oocysts excretion [19-20]. In this study, infected chicks were dull and depressed with ruffled feather and less feed intake, which may be due to altered gut homeostasis that leads to poor feed intake, metabolism and thus decreased weight gains [21, 22]. “Shi Ying Zi” powder can alleviate the histopathological changes of caecum, and the number of oocysts and mucosa cell necrocytosis in caecum has decreased. Therefore, the relative weight gain rate of “Shi Ying Z” groups were also improved. The anti-coccidial index is a common index to evaluate the anticoccidial activity of drugs. The ACI was 165 in the ShiYingZi-pretreated group at the dose of 10 g/kg, which is higher than positive control monensin. These results suggested that “Shi Ying Zi” powder is moderate-potency anticoccidial drug.

The blood biochemical analysis reflected alterations of functional organs and some enzyme activities are often used as indicators of the site and the extent of pathological injury [23-24]. Infection of coccidiosis can affect the body's liver function, which leads to the decrease of triglyceride content in serum [5]. The nutrient malabsorption, hepatocellular damage, haemorrhagic enteritis, kidney dysfunction and inappetence might be lead to the decrease of serum albumin and total protein content[21, 25] and increase of glutamic-pyruvic transaminase and aspartate amino transferase contents in serum[26]. Similarly, there was a statistically significant decrease in the contents of albumin, total protein and triglyceride and significant increase in the contents of glutamic-pyruvic transaminase and aspartate amino transferase after infection. Pretreatment or treatment with “Shi Ying Zi” powder, these changes was recovered to a degree. In histopathology findings, serious liver damage after *E. tenella* infection can be observed. While “Shi Ying Zi” powder can alleviate these symptoms. These results suggested that coccidiosis could affect the body's liver function, and “Shi Ying Zi” could protect and alleviate the liver damage.

Creatinine is a metabolite of muscle creatine and phosphate, which is not affected by the food protein content and protein metabolism. The content of creatinine in the body is relatively constant and only reflected by the renal clearance and renal function [27-28]. When the renal insufficiency, creatinine accumulates in the body and becomes a toxin that is harmful to the body, so that creatinine content can respond to the damage to renal parenchyma [29]. There was a significant increase in creatinine after infection, which was consistent with the report [30]. The content of creatinine in ShiYingZi-treated group are significantly lower. These results showed that “Shi Ying Zi” powder could protect the kidney damage caused by coccidiosis.

Conclusion

The traditional Chinese medicines formula “Shi Ying Zi” powder can prevent and treat *E.tenella* infection in broiler chickens. “Shi Ying Zi” powder could be the alternative control measures for *E.tenella* infection.

List Of Abbreviations

“Shi Ying Zi”	the powder of the mixture of *Cnidium monnieri* (L.) Cuss, *Taraxacum mongolicum* Hand-Mazz. and salt in the ratio of 55:40:5 (g/g/g)
ShiYingZi-PL	the “Shi Ying Zi”-pretreated group at the dose of 5g/kg
ShiYingZi-PM	the “Shi Ying Zi”-pretreated group at the dose of 10g/kg
ShiYingZi-PH	the “Shi Ying Zi”-pretreated group at the dose of 15g/kg
ShiYingZi-TL	the “Shi Ying Zi”-treated group at the dose of 5g/kg
ShiYingZi-TM	the “Shi Ying Zi”-treated group at the dose of 10g/kg
ShiYingZi-TH	the “Shi Ying Zi”-treated group at the dose of 15g/kg

Declarations

Ethics approval and consent to participate

All procedures involving animals and their care in this study were approved by the Ethics Committee of Sichuan Agricultural University according to The Regulation of Experimental Animal Management (State Scientific and Technological Commission of the People's Republic of China, No.2, 1988)

and The Interim Measures of Sichuan Province Experimental Animal Management (Science and Technology Bureau of Sichuan, China, No.25, 2013).

Consent for publication

Not applicable

Availability of data and materials

All data generated or analysed during this study are included in this published article.

Competing interests

The authors declare that they have no competing interests.

Funding

This research was financially supported by the Sichuan Veterinary Medicine and Drug Innovation Group of China Agricultural Research System (CARS-SVDIP), the Science and Technology Project of Sichuan Province (Grant Nos. 2018NZ0043 and 2018NZ0064). The funding body don't have any roles in the design of the study and collection, analysis, and interpretation of data and in writing the manuscript.

Authors' contributions

SX, SC, LY, YZ designed and conducted this study. JR, HY, YT collected the samples. ZY, LL, ZX, LC, YG, ZL analyzed and interpreted the data. SF, YL performed the histological examination. All authors read and approved the final manuscript

Acknowledgements

Not applicable

References

1. Fatoba AJ, Adeleke MA. Diagnosis and control of chicken coccidiosis: a recent update. J Parasit Dis. 2018; 4: 483-93.
2. Morris GM, Gasser RB. Biotechnological advances in the diagnosis of avian coccidiosis and the analysis of genetic variation in Eimeria. Biotechnol Adv. 2006; 6: 590-603.
3. Shirley MW, Smith AL, Blake DP. Challenges in the successful control of the avian coccidia. Vaccine. 2007; 30: 5540-7.
4. Yim D, Kang SS, Kim DW, Kim SH, Lillehoj HS, Min W. Protective effects of Aloe vera -based diets in Eimeria maxima -infected broiler chickens. Exp. Parasitol. 2011; 1: 322-5.
5. Akhtar M, Hai A, Awais MM, Iqbal Z, Muhammad F, ul Haq A, Anwar MI. Immunostimulatory and protective effects of Aloe vera against coccidiosis in industrial broiler chickens. Vet Parasitol. 2012; 186: 170-7.
6. El-Abasy M, Motobu M, Na KJ, Shimura K, Nakamura K, Koge K, Onodera T, Hirota Y. Protective Effects of Sugar Cane Extracts (SCE) on Eimeria tenella Infection in Chickens. J Vet Med Sci. 2003; 65: 865-71.
7. Debry RW. Identifying conflicting signal in a multigene analysis reveals a highly resolved tree: the phylogeny of Rodentia (Mammalia). Syst Biol. 2003; 52: 604-17.
8. Youn HJ, Noh JW. Screening of the anticoccidial effects of herb extracts against Eimeria tenella. Vet parasitol. 2001; 96: 257-63.
9. Nweze NE, Obiwulu IS. Anticoccidial effects of Ageratum conyzoides. J Ethnopharmacol. 2009; 122: 6-9.
10. Quiroz-Castaneda RE, Dantan-Gonzalez E. Control of avian coccidiosis: future and present natural alternatives. Biomed Res Int. 2015; 2015:430-610.
11. Li YM, Jia M, Li HQ, Zhang ND, Wen X, Rahman K, Zhang QY, Qin LP. Cnidium monnieri: a review of traditional uses, phytochemical and ethnopharmacological properties. Am J Chin Med. 2015; 43: 835-77.
12. Ma C, Zhu L, Wang J, He H, Chang X, Gao J, Shumin W, Yan T. Anti-inflammatory effects of water extract of Taraxacum mongolicum hand.-Mazz on lipopolysaccharide-induced inflammation in acute lung injury by suppressing PI3K/Akt/mTOR signaling pathway. J Ethnopharmacol. 2015; 168: 349-355.
13. Johnson J, Reid WM. Anticoccidial drugs: lesion scoring techniques in battery and floor-pen experiments with chickens. Exp Parasitol. 1970; 28: 30-6.
14. Hodgson JN. Coccidiosis: oocyst counting technique for coccidiostat evaluation. Exp Parasitol. 1970;28:99–102.
15. De Pablos LM, dos Santos MF, Montero E, Garcia-Granados A, Parra A, Osuna A. Anticoccidial activity of maslinic acid against infection with Eimeria tenella in chickens. Parasitol Res. 2010; 107: 601–4.
16. Pop LM, Varga E, Coroian M, Nedișan ME, Mircean V, Dumitrache MO, Farczádi L, Fülöp I, Croitoru MD, Fazakas M, Györke A. Efficacy of a commercial herbal formula in chicken experimental coccidiosis. Parasit Vectors. 2019; 12: 343.

17. Adams C, Vahl HA, Veldman A. Interaction between nutrition and Eimeria acervulina infection in broiler chickens: diet compositions that improve fat digestion during Eimeria acervulina infection. Br J Nutr. 1996; 75: 875-80.
18. Gerhold RW, Fuller AL, McDougald LR. Coccidiosis in the chukar partridge (Alectoris chukar): a survey of coccidiosis outbreaks and a test of anticoccidial drugs against Eimeria kofoidi. Avian Dis. 2016; 60: 752-757.
19. Kawazoe U, Fabio JD. Resistance to diclazuril in field isolates of Eimeria species obtained from commercial broiler flocks in Brazil. Avian Pathol. 1994; 23: 305-11.
20. Dutta GP, Mohan A, Tripathi R. Study of the Gametocytocidal/Sporontocidal Action of Qinghaosu (Artemisinin) by Electron Microscopy. J Parasitol. 1990; 76: 849-52.
21. Kettunen H, Tiihonen K, Peuranen S, Saarinen MT, Remus JC. Dietary betaine accumulates in the liver and intestinal tissue and stabilizes the intestinal epithelial structure in healthy and coccidia-infected broiler chicks. Comp Biochem Physiol A Mol Integr Physiol. 2001; 130: 759-69.
22. Hosseini-Mansoub N, Bahrami Y. Influence of dietary fish oil supplementation on humoral immune response and some selected biochemical parameters of broiler chickens. J Agrobiol. 2011; 28: 67-77.
23. Flora SJ, Dubey R, Kannan GM, Chauhan RS, Pant BP, Jaiswal DK. Meso 2,3-dimercaptosuccinic acid (DMSA) and monoisoamyl DMSA effect on gallium arsenide induced pathological liver injury in rats. Toxicol Lett. 2002; 132: 9-17.
24. Cerrato P, Lentini A, Baima C, Grasso M, Azzaro C, Bosco G, Destefanis E, Benna P, Bergui M, Bergamasco B. Hypogeusia and hearing loss in a patient with an inferior collicular infarction. Neurology. 2005; 65: 1840-1.
25. Mondal DK, Chattopadhyay S, Batabyal S, Bera A K, Bhattacharya D. Plasma biochemical indices at various stages of infection with a field isolate of Eimeria tenella in broiler chicken. Vet World. 2011; 4: 404-9.
26. Jafari R A, Razi-Jalali M, Kiani R. Effect of fresh dietary garlic powder on some of the serum biochemical parameters in broiler chicks. Compara Clin Pathol. 2011; 20: 295-7.
27. Hirani ND, Hasnani JJ, Dhami AJ, Khanna K. Haemato-biochemical profile of broilers affected with coccidiosis. J Vet Parasitol. 2007; 21: 25-8.
28. Dwyer BK, Gorman M, Carroll IR, Druzin M. Urinalysis vs urine protein-creatinine ratio to predict significant proteinuria in pregnancy. J Perinatol. 2008; 28: 461-7.
29. Liu KD, Thompson BT, Ancukiewicz M, Steingrub JS, Douglas IS, Matthay MA, Wright P, Peterson MW, Rock P, Hyzy RC, Anzueto A, Truwit JD. Acute kidney injury in patients with acute lung injury: impact of fluid accumulation on classification of acute kidney injury and associated outcomes. Crit Care Med. 2011; 39: 2665-71.
30. Dar SA, Verma P, Ashfaque M, Mir IA. Effect of garlic extract on haematobiochemical changes in Eimeria tenella infected broiler chicken. Natl Acad Sci Lett. 2014; 37: 311-316.

Tables

Table 1 Mortality in different groups from 4dpi to 8dpi

Groups	4dpi	5dpi	6dpi	7dpi	8dpi
Normal	0	0	0	0	0
Untreatment	2	2	1	0	0
ShiYingZi-PL	0	1	0	0	0
ShiYingZi-PM	0	0	0	0	0
ShiYingZi-PH	1	0	0	0	0
Monensin	0	0	0	0	0
ShiYingZi-TL	1	1	0	0	0
ShiYingZi-TM	0	1	0	0	0
ShiYingZi-TH	0	0	0	0	0
Sulfachloropyrazine sodium	0	0	0	0	0

Table 2 Hemorrhagic fecal score from 4dpi to 8dpi

Groups	4dpi	5dpi	6dpi	7dpi	8dpi
Normal	0	0	0	0	0
Untreatment	0	2	3	3	1
ShiYingZi-PL	1	2	3	2	1
ShiYingZi-PM	0	2	2	2	0
ShiYingZi-PH	1	2	3	3	0
Monensin	0	2	2	2	0
ShiYingZi-TL	0	2	3	2	0
ShiYingZi-TM	0	1	2	1	1
ShiYingZi-TH	1	2	2	2	0
Sulfachloropyrazine sodium	0	1	2	1	0

Table 3 The number of oocysts per gram of feces ($\times 10^6$)

Groups	4dpi	5dpi	6dpi	7dpi	8dpi
Normal	0	0	0	0	0
Untreatment	0.27	2.78	1.93	1.54	1.15
ShiYingZi-PL	0.09	2	1.71	0.85	0.55
ShiYingZi-PM	0.14	2.13	1.24	1.03	0.60
ShiYingZi-PH	0	3.12	1.75	1.06	0.83
Monensin	0	1.56	1.69	0.75	0.42
ShiYingZi-TL	0.21	2.17	1.78	1.13	0.90
ShiYingZi-TM	0.33	2.33	1.51	1.23	0.95
ShiYingZi-TH	0.25	2.49	1.88	1.07	0.46
Sulfachloropyrazine sodium	0.19	2.12	1.25	0.99	0.78

Table 4 Anti-coccidiasis index

Indicators	Normal	Untreatment	Protective effect				Therapeutic effect			
			ShiYingZi-PL	ShiYingZi-PM	ShiYingZi-PH	Monensin	ShiYingZi-TL	ShiYingZi-TM	ShiYingZi-TH	Sulfachloropyrazine sodium
average initial weight/g	165	157	164	155	160	146	160	152	149	159
average final weight/g	225	189	210	205	209	192	204	189	190	207
Relative weight gain rate	100%	53%	77%	86%	82%	77%	74%	71%	77%	80%
survival rate	100%	75%	95%	100%	95%	100%	90%	95 %	100%	100%
Gross lesions score	0	35	14	11	13	9	19	15	13	11
caecum oocyst index	0	40	20	10	10	10	20	20	20	10
ACI	-	-	139	165	154	159	125	131	144	159
therapeutic evaluation	-	-	low	medium	low	low	low	low	low	low

Table 5 Total protein content

Groups	1dpi	4dpi	8dpi
Normal	24.56±1.43^{a}	25.26±1.16^{c}	25.48±1.23^{b}
Untreatment	25.48±2.35^{a}	21.58±1^{a}	20.94±0.98^{a}
ShiYingZi-PL	24.8±1.02^{a}	23.52±0.82^{b}	27.4±2.33^{bc}
ShiYingZi-PM	23.66±2.19^{a}	24.28±1.01^{bc}	28.62±1.42^{c}
ShiYingZi-PH	24.3±0.92^{a}	25.22±1.35^{c}	28.08±1.98^{c}
Monensin	23.6±1.98^{a}	23.64±1.43^{b}	28.14±0.8^{c}
ShiYingZi-TL	23.67±2.23 ^{a}	20.67±1.72 ^{a}	24.13±1.43 ^{b}
ShiYingZi-TM	23.1±0.95 ^{a}	21.73±1.40 ^{a}	23.63±1.68 ^{b}
ShiYingZi-TH	24.40±0.92 ^{a}	21.47±3.00 ^{a}	25.23±1.22 ^{b}
Sulfachloropyrazine sodium	24.27±3.40 ^{a}	22.67±0.57 ^{a}	25.80±2.19 ^{b}

^{a,b,c} Significant differences exist when there are not the same letters on each column (P<0.05).

Table 6 The albumin content

Groups	1dpi	4dpi	8dpi
Normal	11.78±0.79[a]	12.34±0.84[c]	13.74±1.03[c]
Untreatment	11.78±1.11[a]	4.64±0.61[a]	4.82±1.36[a]
ShiYingZi-PL	10.9±1.51[a]	6.1±0.68[b]	10.42±0.87[b]
ShiYingZi-PM	10.48±2.02[a]	7.44±0.8[b]	11.04±0.87[b]
ShiYingZi-PH	11.3±0.89[a]	7.24±1.39[b]	11.26±0.63[b]
Monensin	10.8±0.99[a]	6.6±1.44[b]	11.46±1.33[b]
ShiYingZi-TL	10.73±1.58 [a]	4.10±0.92 [a]	8.40±0.92 [b]
ShiYingZi-TM	10.90±0.56 [a]	4.57±0.61 [a]	7.80±0.61 [b]
ShiYingZi-TH	11.67±1.80 [a]	6.00±1.25 [a]	7.20±1.25 [b]
Sulfachloropyrazine sodium	11.53±2.87 [a]	6.20±1.00 [a]	9.43±1.00. [b]

[a,b,c] Significant differences exist when there are not the same letters on each column (P<0.05).

Table 7 The globulin content

Groups	1dpi	4dpi	8dpi
Normal	12.78±0.85[a]	12.92±0.69[a]	11.76±0.87[a]
Untreatment	12.78±0.86 [a]	16.94±1.38[b]	16.10±0.58[b]
ShiYingZi-PL	13.9±2.09[a]	17.42±0.53[b]	16.98±1.65[b]
ShiYingZi-PM	13.18±1.45[a]	16.84±0.3[b]	17.58±0.89[b]
ShiYingZi-PH	13.00±0.74[a]	17.96±0.8[b]	16.82±1.5[b]
Monensin	12.8±1.31[a]	17.04±0.78[b]	16.68±0.9[b]
ShiYingZi-TL	12.93±1.77 [a]	16.57±2.57 [b]	15.73±1.65 [b]
ShiYingZi-TM	12.20±0.46 [a]	17.17±0.83 [b]	15.83±2.94 [b]
ShiYingZi-TH	12.70±1.97 [a]	15.47±1.76 [b]	18.03±0.80 [b]
Sulfachloropyrazine sodium	12.73±1.83 [a]	16.47±1.56 [b]	16.37±0.86 [b]

[a,b,c] Significant differences exist when there are not the same letters on each column (P<0.05).

Table 8 The glutamic-pyruvic transaminase content

Groups	1dpi	4dpi	8dpi
Normal	4.18±0.31[a]	4.08±0.22[a]	4.14±0.23[a]
Untreatment	4.08±0.53[a]	5.6±0.5[b]	6.06±0.21[c]
ShiYingZi-PL	4.1±0.37[a]	4.66±0.15[a]	4.78±0.23[b]
ShiYingZi-PM	4.34±0.49[a]	4.64±0.32[a]	4.34±0.15[a]
ShiYingZi-PH	4.14±0.45[a]	4.66±0.21[a]	4.34±0.15[a]
Monensin	4.16±0.54[a]	4.5±0.25[a]	4.24±0.26[a]
ShiYingZi-TL	4.30±0.78 [a]	5.53±0.32 [b]	5.13±0.15 [b]
ShiYingZi-TM	4.16±0.35 [a]	5.16±0.67 [b]	4.93±0.35 [b]
ShiYingZi-TH	4.57±0.61 [a]	5.33±0.41 [b]	4.80±0.60 [a]
Sulfachloropyrazine sodium	4.60±0.35 [a]	5.03±067 [b]	4.83±0.60 [a]

[a,b,c] Significant differences exist when there are not the same letters on each column (P<0.05).

Table 9 The aspartate aminotransferase content

Groups	1dpi	4dpi	8dpi
Normal	220.46±11.77[a]	223.22±12.06[a]	230.62±23.95[a]
Untreatment	222.56±14.18[a]	263.46±9.28[b]	275.9±10.79[c]
ShiYingZi-PL	216.3±13.94[a]	256.66±11.08[b]	259.28±7.49[b]
ShiYingZi-PM	214.38±17.06[a]	254.54±7.25[b]	250.12±5.36[b]
ShiYingZi-PH	214.1±14.39[a]	251.3±7.11[b]	251.32±12.03[b]
Monensin	224.34±8.5[a]	263.3±11.9[b]	253.08±6.31[b]
ShiYingZi-TL	224.20±9.78 [a]	258.33±10.69 [b]	264.03±9.18 [b]
ShiYingZi-TM	232.33±8.88 [a]	263.73±16.22 [b]	267.37±20.15 [b]
ShiYingZi-TH	220.50±11.05 [a]	264.50±9.97 [b]	264.43±21.63 [b]
Sulfachloropyrazine sodium	230.50±9.10 [a]	263.43±19.90 [b]	254.07±0.36 [b]

[a,b,c] Significant differences exist when there are not the same letters on each column (P<0.05).

Table 10 The creatinine content

Groups	1dpi	4dpi	8dpi
Normal	18.02±2.27[a]	17.48±1.28[a]	17.08±2.16[a]
Untreatment	17.98±2.16[a]	26.62±3.46[c]	28±3.17[c]
ShiYingZi-PL	18.34±1.4[a]	23.1±3.49[b]	22.36±1.67[b]
ShiYingZi-PM	18.34±1.78[a]	22.18±2.04[b]	20.98±1.2[b]
ShiYingZi-PH	18.18±2.53[a]	21.4±1.78[b]	21.36±1.53[b]
Monensin	18.52±1.43[a]	23.42±1.54[b]	21.04±1.23[b]
ShiYingZi-TL	17.50±1.90 [a]	25.03±1.77 [b]	22.73±1.71 [b]
ShiYingZi-TM	19.13±1.72 [a]	24.86±3.22 [b]	23.66±1.59 [b]
ShiYingZi-TH	18.56±2.00 [a]	24.46±1.60 [b]	23.70±1.83 [b]
Sulfachloropyrazine sodium	19.76±1.04 [a]	25.40±2.52 [b]	21.56±2.33 [b]

[a,b,c] Significant differences exist when there are not the same letters on each column (P<0.05).

Table 11 Triglyceride content

Groups	1dpi	4dpi	8dpi
Normal	0.57±0.06[a]	0.59±0.04[c]	0.57±0.07[c]
Untreatment	0.57±0.08[a]	0.38±0.04[a]	0.34±0.05[a]
ShiYingZi-PL	0.56±0.03[a]	0.44±0.03[b]	0.47±0.03[b]
ShiYingZi-PM	0.54±0.05[a]	0.49±0.04[b]	0.48±0.03[b]
ShiYingZi-PH	0.56±0.07[a]	0.47±0.04[b]	0.47±0.04[b]
Monensin	0.57±0.06[a]	0.48±0.05[b]	0.45±0.04[b]
ShiYingZi-TL	0.55±0.05 [a]	0.39±0.04 [a]	0.40±0.06 [ab]
ShiYingZi-TM	0.54±0.06 [a]	0.36±0.03 [a]	0.41±0.03 [ab]
ShiYingZi-TH	0.53±0.09 [a]	0.38±0.07 [a]	0.46±0.04[b]
Sulfachloropyrazine sodium	0.56±0.05 [a]	0.37±0.04 [a]	0.45±0.04[b]

[a,b,c] Significant differences exist when there are not the same letters on each column (P<0.05).

Figures

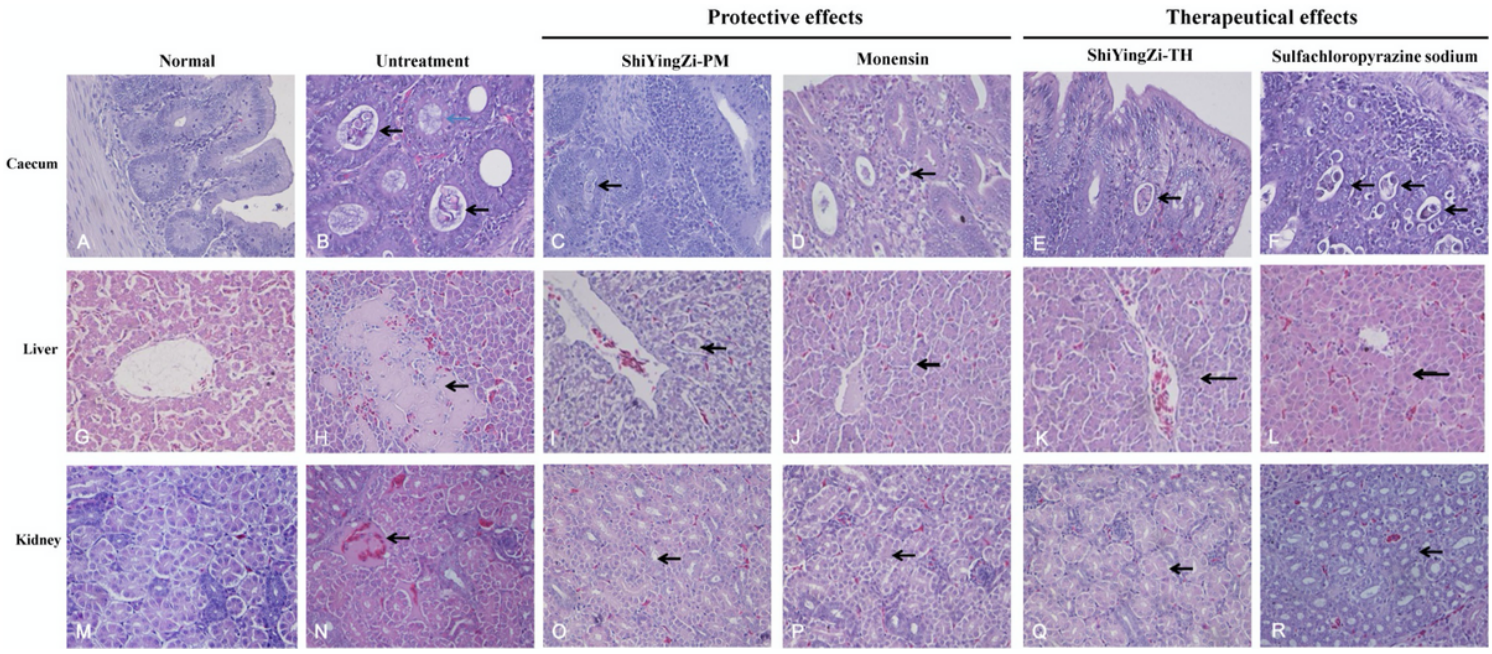

Figure 2

Histopathological examination of protective admininstration. In the caecum (A-F), oocysts invaded caecum mucosa and intestinal gland (B, denoted by arrowhead) and serious karyopyknosis and necrocytosis were detected in caecum mucosa cell; In the ShiYingZi-PM group (C), ShiYingZi-TH group (E) and positive control groups (D, monensin; F, sulfachloropyrazine sodium), few oocysts were observed in caecum mucosa cell (denoted by arrowhead), and the caecum mucosa cell appeared granular and vacuolar degeneration; A, normal group. In the liver (G-L), E.tenella infection induced serious hepatocyte necrosis and inflammatory cell infiltration (H, denoted by arrowhead); granular and vacuolar degeneration (denoted by arrowhead) appeared in the ShiYingZi-PM group (I), positive control group (J, monensin; L, sulfachloropyrazine sodium) and ShiYingZi-TH group (K); G, the normal structure of the liver. In the kidney (M-R), serious granular and vacuolar degeneration and cell necrosis were observed in the untreated group (N, denoted by arrowhead); few granular and vacuolar degeneration (denoted by arrowhead) were observed in the ShiYingZi-PM group (O), ShiYingZi-TH group (Q) and positive control group (P, monensin; R, sulfachloropyrazine sodium); in the threapeutical effects, more inflammatory cell infiltration was observed in the positive control group (R) than that in the ShiYingZi-TH group (Q) ; M, normal group.

Supplementary Files

This is a list of supplementary files associated with this preprint. Click to download.

- Tables111.zip
- Tables111.zip