Hindawi
Andrologia
Volume 2023, Article ID 6631345, 10 pages
https://doi.org/10.1155/2023/6631345

Research Article

Protective Effect of *Hedeoma drummondii* against Formaldehyde-Induced Testicular Toxicity and Genotoxicity in Wistar Rats

Nadia Denys Betancourt-Martínez,[1] **Pilar Carranza-Rosales**,[2] **Ezequiel Viveros-Valdez**,[3] **Nancy Elena Guzmán-Delgado**,[4] **Maritza Argelia Macias-Corral**,[5] **Irma Edith Carranza-Torres**,[3] **Lydia Enith Nava-Rivera**,[1] **María Soñadora Niño Castañeda**,[1] **and Javier Morán-Martínez**[1]

[1]*Departamento de Biología Celular y Ultraestructura, Facultad de Medicina, Universidad Autónoma de Coahuila, Avenida Morelos 900-Oriente, Primero de Cobián Centro, Torreón, Coahuila 27000, Mexico*
[2]*Departamento de Biología Celular y Molecular, Centro de Investigación Biomédica del Noreste, Instituto Mexicano del Seguro Social, Monterrey, Nuevo León 64720, Mexico*
[3]*Facultad de Ciencias Biológicas, Universidad Autónoma de Nuevo León, San Nicolás de los Garza, Nuevo León 64460, Mexico*
[4]*División de Investigación en Salud, Hospital de Cardiología No. 34 "Dr. Alfonso J. Treviño Treviño" del Centro Médico Nacional del Noreste, Unidad Médica de Alta Especialidad, Instituto Mexicano del Seguro Social, Monterrey, Nuevo León 64360, Mexico*
[5]*Facultad de Medicina, Universidad Autónoma de Coahuila, Avenida Morelos 900-Oriente, Primero de Cobián Centro, Torreón, Coahuila 27000, Mexico*

Correspondence should be addressed to Javier Morán-Martínez; javiermoranmartinez@uadec.edu.mx

Received 4 June 2023; Revised 18 September 2023; Accepted 23 September 2023; Published 19 October 2023

Academic Editor: Muhammad Babar Khawar

Copyright © 2023 Nadia Denys Betancourt-Martínez et al. This is an open access article distributed under the Creative Commons Attribution License, which permits unrestricted use, distribution, and reproduction in any medium, provided the original work is properly cited.

Formaldehyde (FA) is an oxidative stress inducer and a known carcinogen. *Hedeoma drummondii* has been shown to have potential as a chemopreventive agent. The aim of this study was to assess the protective effect of *H. drummondii* on FA-induced genotoxic damage, sperm quality parameters, and histological changes of the testis. The male Wistar rats used were divided into the following groups: (G1) 100 mg/kg *H. drummondii*; (G2) 10 mg/kg FA; (G3) 100 mg/kg *H. drummondii* + 10 mg/kg FA; (G4) phosphate-buffered saline; (G5) 100 mg/kg α-tocopherol; (G6) 100 mg/kg α-tocopherol + 10 mg/kg FA; and (G7) soybean oil. The results showed a sperm concentration of 23.66 ± 1.52 versus 33.67 cells/mL ($p = 0.02$), and a percentage of motility of 29.66 ± 1.51 versus 33.33 ($p = 0.620$), for groups G3 and G6, respectively. Histopathological (H&E) and immunohistochemical analysis of superoxide dismutase showed damage in the germinal epithelium (GE) in G2. While in groups G3 and G6, the histological structure was preserved. A protective effect on sperm DNA fragmentation was also observed for treated groups (G3 and G6, $p < 0.0001$ vs. G2). While in groups G3 and G6 the histological structure was preserved. A protective effect on sperm DNA fragmentation was also observed for treated groups (G3 and G6). In conclusion, FA exposure significantly reduces sperm quality parameters, causes sperm DNA damage, and alters GE in the testis, while *H. drummondii* has a protective effect against FA-induced sperm genotoxic damage, similar to α-tocopherol.

1. Introduction

Formaldehyde (FA) is a chemical product mainly used for resins, wood, plastics, coatings, and textile productions [1]. It is an environmental pollutant classified as carcinogenic to humans since its inclusion in the 14th report about carcinogens in 2016. Abnormalities in sperm quality and male fertility are strongly associated with environmental pollution [2]. Studies about occupational exposure to FA have reported low sperm motility in exposed workers [3], and some other animal studies have shown negative effects on sperm quality, atrophy and decreased testicular weight, differences in serum testosterone

levels, and deteriorations in tubular diameter and height of the seminiferous epithelium, after FA exposure [4–8]. Likewise, studies in rats exposed intraperitoneally to FA found changes in cells of the germinal epithelium (GE), decreased motility and sperm concentration, and increased sperm DNA fragmentation [9–11]. Furthermore, it has been reported that FA can increase reactive oxygen species production; molecules that play a central role in oxidative stress induction and cell damage [12–14]. Oxidative stress plays a critical role in testicular damage, however, one alternative for its prevention is the increase of dietary intake of antioxidants through the consumption of herbal infusions, mainly those obtained from the infusion of herbal species belonging to the Lamiaceae family. These are characterized by having a large number of antioxidants such as phenols and flavonoids [15, 16]. These compounds could be responsible for modulating and protecting against testicular damage induced by chemical agents [17]. Little is currently known about some species from the Lamiaceae family, such as *Hedeoma drummondii*; an aromatic plant with a strong and pleasant mint flavor consumed in infusions and as a soups and meats seasoning by people from northeastern Mexico and southern USA [18].

In recent years, FA has generated great controversy due to the large number of harmful health effects that have been reported [19]. As an alternative to reduce FA toxicity, the use of extracts obtained from natural products has been proposed. For example, it has already been reported that the ethanolic extracts of *Matricaria chamomilla* and *Ganoderma lucidum* attenuate the damage induced by FA in neurons and hepatocytes [16, 20], while the methanolic extract of *Syzygium cumini* fruits showed a potent anti-inflammatory effect induced by the toxicant [21]. Likewise, the protective effect of the extracts of common fig (*Ficus carica*) leaves has already been reported on sperm and testis parameters of FA-intoxicated mice [22]. Broccoli methanolic extract, ginger, and origanum aqueous extracts are other natural extracts reported with relevant activity to protect testicular function by antioxidant-related mechanisms [23–25].

Previously, we reported the chemopreventive potential of *H. drummondii*; the proven extract exhibited relevant antioxidant activity and antiproliferative effect on tumor cell lines [26, 27]. Therefore, in this study, we assessed the protective effect of *H. drummondii* on testicular damage induced by FA through sperm quality parameters, sperm DNA fragmentation, and histological and immunohistochemical analysis in testicular tissue of Wistar rats.

2. Materials and Methods

2.1. Plant Collection. Poleo (*H. drummondii*, *Lamiaceae*), was collected from May to July of 2020 from Atongo de Abajo in the municipality of Allende, Nuevo León, Mexico (25°21′9″N, 99°59′22″W) by a random sampling of a 100×100 m area. The taxonomic identification was carried out by Dr. Marcela González Álvarez, from the herbarium of the Faculty of Biological Sciences of the Autonomous University of Nuevo León (voucher number: 024244).

2.2. Plant Extraction. Once the aerial part of *H. drummondii* was dried and crushed, it was subjected to a solid–liquid extraction with 70% ethanol (ETOH) using the maceration technique at room temperature. A 1 : 10 ratio of plant material/solvent was used, including solvent changes every 24 hr for three consecutive days. Subsequently, the extract was filtered using Whatman grade 1 filter paper, then the organic solvent was removed from the filtrate using a rotary evaporator at reduced temperature and pressure. Finally, the residual water was removed by lyophilization. Previous studies by our group characterized components of *H. drummondii*, where the main antioxidant compounds isolated and identified were rosmarinic acid, chlorogenic acid, and caffeic acid [27].

2.3. Animals and Treatments. Twenty-one adult male Wistar rats (215–230 g) were used. Rats were provided by the bioterium of the Faculty of Medicine at the Autonomous University of Coahuila and were kept under controlled temperature conditions (25–26°C), with a light–dark cycle of 12 hr, and receiving food and water ad libitum.

The rats were divided into seven groups of three animals each, with the following treatments: Group 1 (G1) orally received 100 mg/kg of *H. drummondii* dissolved in phosphate-buffered saline (PBS) 1%, every third day for 15 days. Group 2 (G2) intraperitoneally administered with 10 mg/kg of FA (Sigma–Aldrich, St. Louis, USA), every third day for 15 days; Group 3 (G3) orally received 100 mg/kg of *H. drummondii* dissolved in PBS 1%, every third day during 15 days, after an intraperitoneal administration of 10 mg/kg of FA, every third day for 15 days. Group 4 (G4) orally received 1% PBS every third day for 15 days. Group 5 (G5) orally received 100 mg/kg of α-tocopherol (Sigma–Aldrich T3251, St. Louis, USA) dissolved in soybean oil, every third day for 15 days. Group 6 (G6) orally received 100 mg/kg of α-tocopherol dissolved in soybean oil every third day for 15 days, after an intraperitoneal administration of 10 mg/kg of FA. Group 7 (G7) orally received soybean oil every third day for 15 days. After the exposure period, the animals were sacrificed by cervical dislocation carried out by a certified veterinary (certification card MR-0716-33-001-16). The testicles were removed and fixed in fresh Bouin's solution for subsequent histopathological analysis, and sperm cells were obtained from the epididymis.

2.4. Spermatozoa Extraction from the Epididymis and Sperm Quality. The epididymis was punctured, and the content was eluted with 4 mL of physiological solution to obtain the spermatozoa. Ten microliters of the obtained suspension were placed on a slide and observed at 40× magnification, where 200 cells per sample were analyzed and the motility percentage was obtained. The sperm count was measured according to the described in the Manual of the World Health Organization [28].

2.5. Sperm DNA Fragmentation Analysis. For this analysis, we follow the technique called sperm chromatin dispersion described by Fernández et al. [29]: 1×10^5 spermatozoa suspended with 1% of low melting point agarose were placed on a pretreated slide (with 0.65% normal melting point agarose), followed by a 25 min treatment in a lysis solution (0.4 M Tris, 0.8 M DTT, 1% SDS, 50 mM EDTA, 2 M NaCl), two consecutive washing periods with Tris-borate-EDTA solution for

Table 1: Sperm quality parameters among the groups.

Group	Sperm concentration (1×10^6/mL)	Sperm motility (%)
G1 (*Hedeoma drummondii*)	39.66 ± 2.08	40.66 ± 1.15
G4 (PBS)	37.66 ± 2.51	36.55 ± 1.52
G5 (α-tocoferol)	42.33 ± 2.51	41.33 ± 2.08
G7 (soyabean oil)	35 ± 2	36.6 ± 3.21

2 min each, and 70%, 90%, and 100% ethanol washes for 2 min each. Finally, slides were stained with Wright stain, and analyzed under bright field microscopy at 100× magnification.

2.6. Histopathological Analysis. Testicle tissues were processed using the conventional histological technique, included in paraffin blocks, subsequently cut into 5 μm sections, stained with Hematoxylin and Eosin (H&E) and finally analyzed under light microscopy.

2.7. Immunohistochemical Expression of Superoxide Dismutase in the Testis. Analysis of superoxide dismutase (SOD 1) expression was carried out on paraffin sections using the methods described by the Dako LSAB System-HRP from Leica and the Cu/Zn SOD (rat) Polyclonal Antibody (No. 10011387) from Cayman Chemical. Histological sections of 5 μm thickness were mounted on silanized slides previously deparaffinized with xylene, followed by dehydration through an ethanol gradient and incubated in recovery solution at pH 9.0. Subsequently, immunohistochemical staining was performed following the manufacturer's instructions (Dako North America, Inc). Finally, a hematoxylin counterstain was performed, followed by a 2-min wash in deionized water and dehydration in ethanol and xylene series. Negative and positive controls for SOD 1 antibody were added to each slide.

2.8. Ethical Considerations. A veterinary certified by the SAGARPA (Servicio Nacional de Sanidad, Inocuidad y Calidad Agroalimentaria, key code: MR-0716-33-001-1), was responsible for the proper animal care. This study was assessed according to the Official Mexican Standard NOM-062-ZOO-1999, for the production, care, and use of laboratory animals. The protocol was approved by the CICUAL (Comité Interno para el Cuidado y Uso de los Animales de Laboratorio, SAGARPA-key code: AUT-B-C-0318-042) from the School of Medicine of the Autonomous University of Coahuila.

2.9. Statistical Analysis. Analysis was performed in the SPSS statistical package version 22.0 for Windows. Data are shown as mean and standard deviation, ANOVA analysis was performed with Tukey as a post hoc test, all values were statistically significant with $p < 0.05$.

3. Results

3.1. Plant Material. A green residue (extract) was obtained after plant material processing with a yield of 13.5% in dry weight.

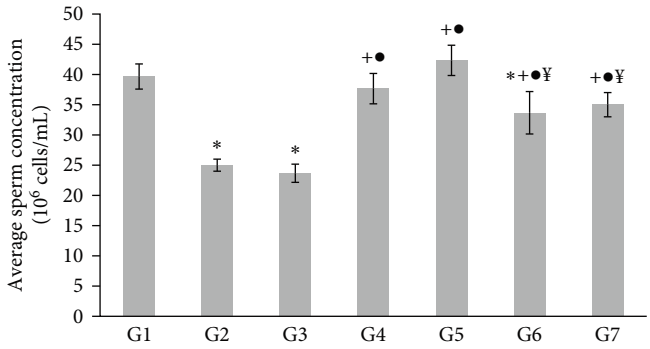

Figure 1: Comparison of sperm concentrations between groups: mean ± standard deviation. In contrast to: (*) G1 with $p < 0.0001$ (+) G2 with $p < 0.01$, (●) G3 with $p < 0.005$, and (¥) G5 with $p < 0.005$.

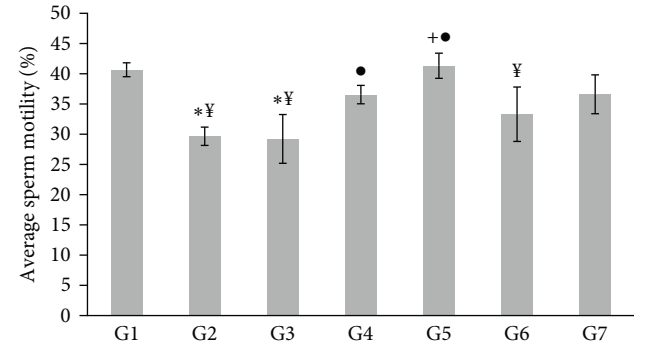

Figure 2: Comparison of motility percentages between groups: mean ± standard deviation. In contrast to: (*) G1 with $p < 0.05$, (+) G2 with $p < 0.05$, (●) G3 with $p < 0.05$, and (¥) G5 with $p < 0.05$.

3.2. Sperm Quality

3.2.1. Sperm Concentration. Epididymal spermatozoa were analyzed, the concentration was expressed in 1×10^6 cells/mL. After analysis, we found that FA significantly reduces sperm concentration. Besides, we obtained homogeneity in the sperm quality parameters between negative-damage control groups (G1, G4, G5, and G7; Table 1), on the other hand, the treatment with *H. drummondii* (G3) was not effective on sperm parameters ($p = 0.989$) as α-tocopherol (G6) that showed a protective effect against the FA-induced damage in contrast to the damage group (G2) ($p < 0.01$). Figure 1 shows comparisons between the studied groups.

3.2.2. Sperm Motility. Regarding the percentage of sperm motility, we observed a similar trend to that of the sperm concentration (Figure 2), since no significant differences

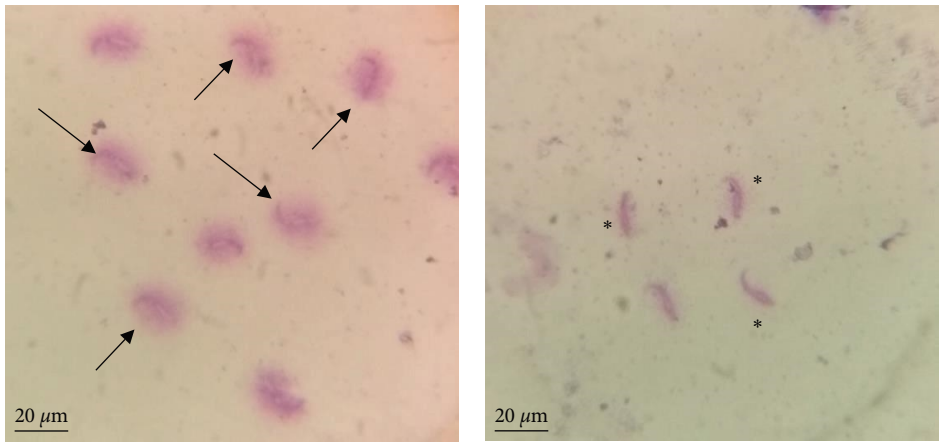

(a) (b)

Figure 3: DNA fragmentation in rat sperm. (a) Fragmented sperm DNA and (b) unfragmented sperm DNA. Wright's stain, 100× magnification.

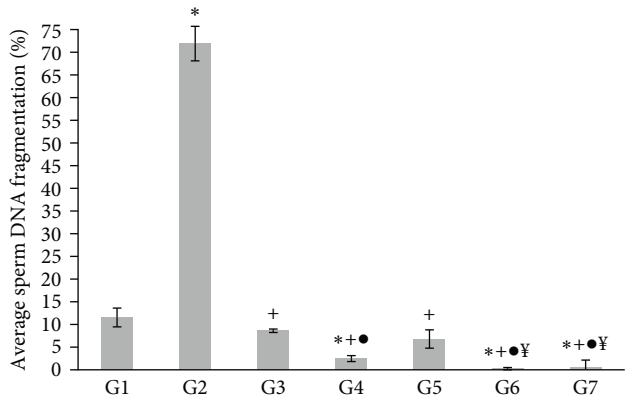

Figure 4: Fragmentation level comparison among the groups. Error bars: standard deviation. In contrast to: (*) G1 with $p < 0.0001$, (+) G2 with $p < 0.0001$, (●) G3 with $p < 0.0001$, and (¥) G5 with $p < 0.0001$.

were obtained between negative damage groups (G1, G4, G5, and G7). However, no significant differences were found between the percentages obtained for G3 versus G2 ($p = 1.000$) and G6 versus G2 ($p = 0.702$).

3.3. Sperm DNA Fragmentation. Figure 3 shows sperm cells with fragmented DNA (black arrow) and unfragmented DNA (asterisk). Figure 4 shows percentages of DNA-fragmented sperm cells, 0% indicates that chromatin is intact in all the cells. In group 2 (G2), treated with FA, the percentage of fragmentation was 72.25 ± 3.84, while in groups 3 (G3) and 6 (G6) the values were 8.6 ± 0.38 and 0.25 ± 0.25, respectively, being statistically significant compared to G2 ($p < 0.0001$); indicating an important protective effect in the group treated with *H. drummondii* and α-tocopherol. We must highlight the importance of these results since the *H. drummondii* extract used was an alcoholic extract and not a pure compound.

3.4. Histopathological Analysis. Effect of FA on tissue. The histopathological analysis of the liver, kidney, brain, and lungs from the various experimental groups did not reveal any significant histological damage. However, systemic vascular congestion was observed in the groups treated with different concentrations of FA, as compared to the organs from the controls. However, the testicular tissue was notably sensitive to the toxic effect of FA. Mild to moderate morphological alterations were observed in animals treated with 5 and 10 mg of FA/kg body weight, while a marked decrease in sperm count and altered morphology of most seminiferous tubules were found in animals treated with 30 mg of FA/kg body weight (Figure 5). Figure 5 provides a detailed description and highlights representative morphological findings of the toxic effect of FA on testicular tissue.

A normal structure of the seminiferous tubules with an intact basement membrane (BM), GE layers with normal maturation, Leydig cells (LC) between each tubule, and an adequate amount of sperm cells (*) in the tubular lumen (L), was observed in control group (Figure 5(a)). The same was found for the group administered with *H. drummondii* (Figure 5(b)), in which preserved structures of the seminiferous tubules with adequate maturity of the GE and spermatogenesis were observed. On the contrary, in the group treated with FA (Figure 5(c)), cellular atypia and disorganization of the GE, presence of several large vacuoles (V), intraluminal necrotic cells (arrowheads), decrease in the diameter of the lumen of the tubules, and a considerable decrement of sperm cells was observed. The administration of the ethanolic extract of *H. drummondii* after treatment with FA prevented the morphological damage to the testicular tissue induced by FA, as compared to the control group without treatment. GE with adequate maturity, preserved spermatogenesis, and an adequate number of intraluminal spermatozoa can be observed in the group treated with *H. drummondii* + FA (Figure 5(d)). Figure 5(e), shows the normal germinal epithelial layers and an adequate number of spermatozoa in the tubular lumen, observed in the group treated only with α-tocopherol as a control. On the other hand, a protective effect was also observed in the group treated with α-tocopherol + FA (Figure 5(f)). However, the protective effect was lower compared to the *H. drummondi*. This

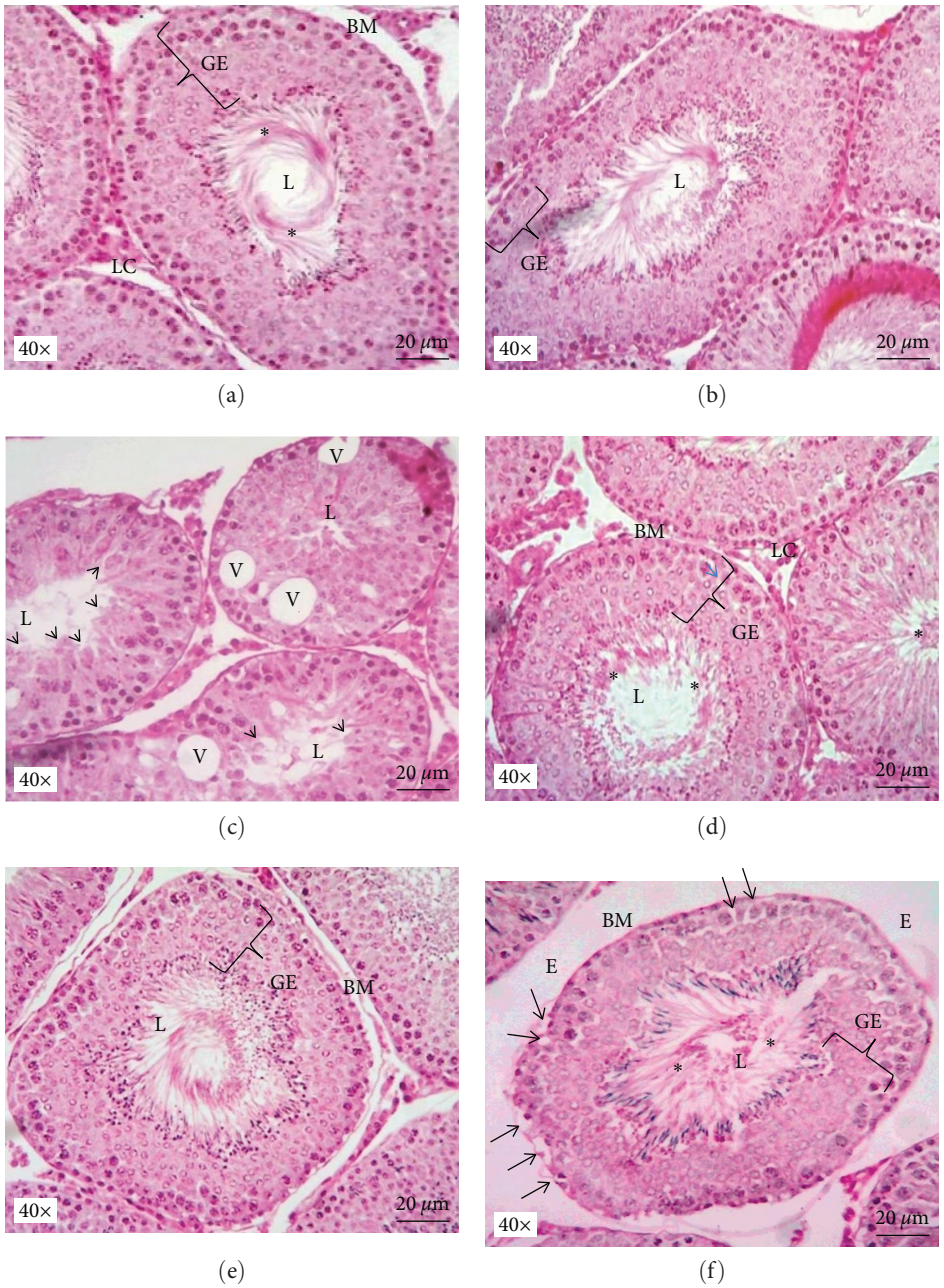

Figure 5: Histological section of the testis. (a) PBS, (b) 100 mg/kg *Hedeoma drummondii*, (c) 10 mg/kg formaldehyde, (d) *Hedeoma drummondii* + FA, (e) α-tocopherol, and (f) 100 mg/kg α-tocopherol + FA (40× magnification, H&E stain).

is because small abnormal vacuoles were observed at the BM (arrows), as well as a greater separation space (E) between the seminiferous tubules in all the α-tocopherol treated groups. Regardless, the maturity of the germ cells layers of the epithelium inside the tubule besides the spermatogenesis were preserved in both groups.

3.5. SOD 1 Immunohistochemical Analysis in the Testis. Figure 6 shows the findings from the immunohistochemical analysis, where a deleterious effect of FA can be observed in contrast to the control groups which show normal structures as well as those treated only with the extract of *H. drummondii*. The control group without treatment (PBS) (Figure 6(a)) shows the normal structure of the seminiferous tubules with their intact BM and negative staining. A negative staining is also observed in the *H. drummondii* group (Figure 6(b)). On the contrary, FA positivity (+++) is observed in the cytoplasm of GE cells, as well as the persistence of intraepithelial vacuoles (V) (Figure 6(c)). Moreover, *H. drummondii* + FA group showed GE with adequate maturity, but weak (+) staining was present (Figure 6(d)). A negative stain was observed for the α-tocopherol control group (Figure 6(e)) and for the group previously treated with α-tocopherol (Figure 6(e)). In the group previously treated with α-tocopherol (Figure 6(f)), the protective effect against FA toxicity at the administered dose was lower compared to *H. drummondii*, since SOD

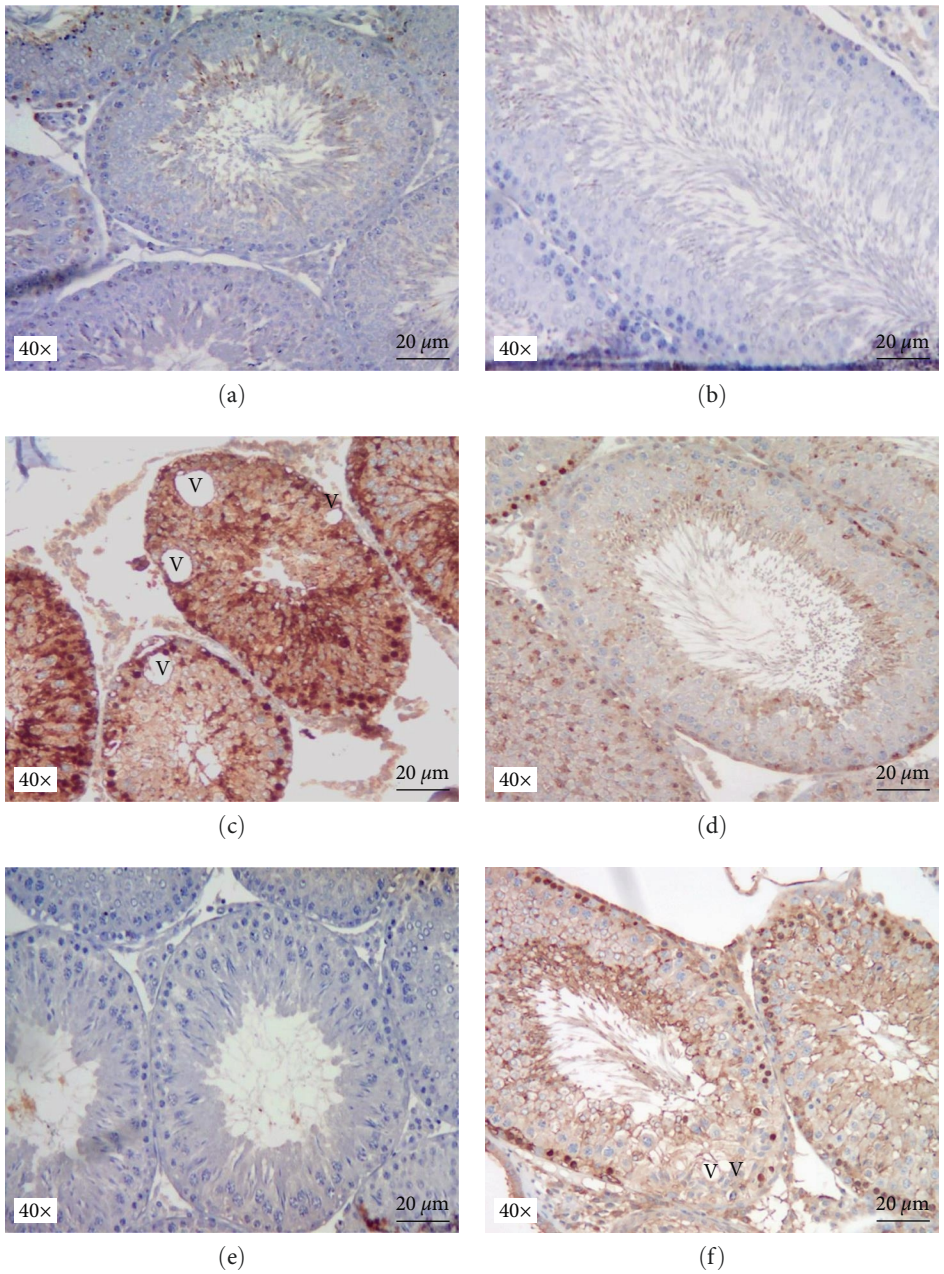

Figure 6: SOD 1 immunohistochemical analysis in testicle tissue of treated groups. (a) PBS, (b) 100 mg/kg *Hedeoma drummondii*, (c) 10 mg/kg formaldehyde, (d) *Hedeoma drummondii* + FA, (e) 100 mg/kg α-tocopherol, and (f) α-tocopherol + FA.

expression was moderate (++) and persisted small abnormal vacuoles (V) at the junction of the BM.

4. Discussion

FA is a genotoxic agent that induces oxidative stress followed by DNA damage [19, 30]. Occupational exposure is one of the main exposure types to FA due to its use in many industries [1, 31]. In the present study, the protective effect of *H. drummondii* on altered sperm parameters, sperm DNA fragmentation, and germinal epithelial degeneration produced by intraperitoneal intoxication with low doses of FA was demonstrated in a rat model. Previous studies have reported about negative effects of FA on sperm quality parameters, for instance, a reduction in concentration and sperm motility [32–34]. In this experiment, the group treated with FA had lower sperm concentration and decreased motility percentage. Dietary inclusion of natural products or natural origin commercial supplements with antioxidant properties is very common nowadays because it has been shown that numerous diseases can appear due to the oxidative stress process. For example, vitamin E has been proposed as a beneficial food supplement to counteract the FA-induced effects or by other xenobiotics due to its multiple antioxidant qualities [35]. Some authors have published important findings about vitamin E, highlighting its effect

on sperm parameters improvement (motility, viability, and concentration) [36–38]. A similar effect was found in this study since α-tocopherol treatment resulted in the highest concentration and sperm motility.

Previous studies have shown that FA causes damage because of oxidative stress production, therefore, the use of natural extracts with antioxidant potential can be useful as a treatment, due to its capacity to reduce damage caused by genotoxic agents [39, 40]. A study carried out by Bakar et al. [41], evaluated the protective effect of proanthocyanidins (PA) compared to vitamin E treatment on FA-induced rat kidney damage. PA significantly decrease total sialic acid levels, malondialdehyde, and alterations in the SOD 1 and myeloperoxidase activity, compared to vitamin E treatment.

On the other hand, because of FA-generated damage is strongly related to oxidative stress [42], SOD has been shown to play a key role in the removal of intracellular superoxide anion [43]. The superoxide anion generated by the inner mitochondrial membrane is metabolized to hydrogen peroxide by Mn-SOD present in the mitochondrial matrix and by Cu/Zn-SOD in the cytosol. In turn, hydrogen peroxide is removed by GPX [44]. Therefore, tissues with high levels of SOD would be subjected to strong damage generated by oxidative stress, so that in those tissues where this effect was attenuated, levels close to basal levels would occur.

In this study, the activity of SOD 1 in testicular tissue was measured. Interestingly, the *H. drummondii* treatment after FA exposure resulted in a greater protective effect compared to the group treated with α-tocopherol (Figure 6).

Other studies report adverse effects due to the administration of natural extracts. For instance, Atere and Akinloye [45], reported a higher cadmium-induced damage in the rat group treated with the higher dose of *Costus afer* (CAME), due to the effect of this extract over the antioxidant system (GST, GSH, CAT). However, in the group treated with the lowest dose, CAME extract was harmless. In addition, no difference was found between the control group and the group treated only with CAME. Similarly, we found that the ethanolic extract of *H. drummondii* counteracted the deleterious effect of FA, and the group treated only with this extract showed no adverse effects on the evaluated parameters. Likewise, we can attribute the induced damage to the oxidative stress pathway activated by FA [14] and highlight the fact that the *H. drummondii* extract components were able to protect the testicular epithelium since not damage was observed.

In another study published by David et al. [46] where they evaluated the anti-infertility effect finding that the methanolic extract of *Asplenium dalhousiae Hook*, significantly decreased the activity of CAT and SOD, negatively impacting viability and sperm motility. Besides, this effect was dosage dependent. In our study, the evaluation shown in Figure 6 demonstrates that the damage caused by AF may be due to oxidative stress production, since the group treated with this xenobiotic showed a +++ staining of SOD 1, while the ethanolic extract administered previously to the FA showed antioxidant potential. In agreement with our findings, a group of researchers found an improvement in sperm quality parameters and fertility in senescent rats treated with an *Alchornea cordifolia* extract [47]. It has been reported the therapeutic effect of curcumin and pumpkin seed oil on the oxidative damage caused in male Albino–Wistar rats and Swiss Albino mice, respectively, after FA exposure. Curcumin reduces FA-incremented serum levels of MDA [48], while pumpkin seed oil reduces FA-incremented brain, liver, and kidney levels of MDA [49]. These findings are similar to those obtained in this study, in which a protective effect of *H. drummondii* was observed, possibly due to the presence of caffeic and rosmarinic acids, which can provide an antioxidant effect [26].

The identification of human health problems associated with occupational or environmental exposure has been strongly supported by studies carried out on experimental animals. This enables the proposal of novel strategies for treatment. For example, Aydin et al. [50], experimented with Sprague rats—Dawley exposed to different inhaled doses of FA to evaluate the effect of carnosine on oxidant and antioxidant levels in serum, kidney, and lung tissues. They found that carnosine can reduce oxidative stress and restore histopathological and biochemical damage. One important finding in our study was the protective effect of *H. drummondii* on testicular tissue compared to α-tocopherol (Figure 1). It has been reported the effect of vitamin E on FA-altered SOD, GSH-Px, and GSH levels, on the improvement of sperm parameters, and on the histological changes, also induced by FA exposure. Some histological abnormalities reported were atrophy of the seminiferous tubules, germ cells degeneration and azoospermia. In the group treated with vitamin E + FA, the seminiferous tubules had partially recovered. However, the number of spermatozoa in the lumen was lower than in the control group [36]. Similar results were obtained in the present study, where sperm quality parameters (concentration and motility) showed better results in the group administered with α-tocopherol + FA compared to the group treated with FA alone, although histologically, we observed a greater protective effect in the *H. drummondii* treated group (Figure 5).

In the present study, the α-tocopherol treated group was selected as the reference control group, since some authors demonstrating its protective effect against damage induced by different xenobiotics at a reproductive level [37, 38, 51]. In a similar approach, other authors have studied the effects of different antioxidants, such as vitamin E (α-tocopherol) and different natural products on testicular tissue damage. For instance, in the study carried out by Jahan et al. [52], the effect of vitamin E, sulforaphane, and the extract of *Ficus religiosa* was evaluated in cadmium-intoxicated rats. They found that exposure to cadmium caused a significant decrease in antioxidant enzymes (CAT, POD, SOD, GSR) in addition to dystrophy in the GE. While treatments with antioxidants turned out to be effective in reversing this Cd-induced toxicity, being a possible therapeutic agent against this xenobiotic. In another study, the protective effect of rose oil against the testicular damage induced by FA vapors was evaluated in a rat model. This resulted in increased testosterone serum levels, sperm count, and motility compared to the

FA group. Histologically, in the FA-exposed group, an increased number of LC with damaged nuclei was observed compared to the group treated with rose oil. The authors concluded that rose oil has protective effects against FA-induced damage [53]. Being similar to our findings using *H. drummondii* extract.

5. Conclusion

FA exposure resulted in reduced sperm quality, sperm DNA damage, and altered structure of the GE in Wistar rats. Administering an extract of *H. drummondii* has a protective effect against FA-induced genotoxic damage in sperm cells, similarly to α-tocopherol, and in the level expression of superoxide dismutase. The pleasant aroma and flavor of *H. drummondii* could help its easy incorporation into a complementary therapy aimed at the prevention and/or treatment of people exposed to FA, thus giving value to the commercialization and use of the natural resource.

Data Availability

The data that support the findings of this study are available from the corresponding authors upon reasonable request.

Conflicts of Interest

The authors declare no conflict of interest.

Authors' Contributions

Nadia Denys Betancourt Martínez, Pilar Carranza Rosales, and Javier Morán Martínez planned and designed conceptualization and project administration. Lydia Enith Nava Rivera, Maritza Macias Corral, and Nancy Elena Guzmán Delgado wrote the original draft preparation and participated and performed data analysis. Irma Edith Carranza Torres, Maria Soñadora Niño Castañeda, and Ezequiel Viveros Valdez performed the methodology and the experiments. All authors have read and agreed to the published version of the manuscript.

Acknowledgments

Many thanks to the National Council of Science and Technology (CONACYT), for the scholarship awarded to NDBM (Scholarship number: 16334).

References

[1] IARC, "Formaldehyde," in *IARC Monographs on the Evaluation of Carcinogenic Risks to Humans. Formaldehyde, 2-Butoxyethanol and 1-tert-Butoxypropan-2-ol*, vol. 88, pp. 39–325, International Agency for Research on Cancer, Lyon, France, 2012.

[2] H. Levine, N. Jørgensen, A. Martino-Andrade et al., "Temporal trends in sperm count: a systematic review and meta-regression analysis," *Human Reproduction Update*, vol. 23, no. 6, pp. 646–659, 2017.

[3] H.-X. Wang, H.-C. Li, M.-Q. Lv et al., "Associations between occupation exposure to formaldehyde and semen quality, a primary study," *Scientific Reports*, vol. 5, no. 1, Article ID 15874, 2015.

[4] W.-G. Chung, I.-J. Yu, C.-S. Park, K.-H. Lee, H.-K. Roh, and Y.-N. Cha, "Decreased formation of ethoxyacetic acid from ethylene glycol monoethyl ether and reduced atrophy of testes in male rats upon combined administration with toluene and xylene," *Toxicology Letters*, vol. 104, no. 1-2, pp. 143–150, 1999.

[5] O. A. Ozen, M. Yaman, M. Sarsilmaz, A. Songur, and I. Kus, "Testicular zinc, copper and iron concentrations in male rats exposed to subacute and subchronic formaldehyde gas inhalation," *Journal of Trace Elements in Medicine and Biology*, vol. 16, no. 2, pp. 119–122, 2002.

[6] M. J. Golalipour, R. Azarhoush, S. Ghafari, A. M. Gharravi, S. A. Fazeli, and A. Davarian, "Formaldehyde exposure induces histopathological and morphometric changes in the rat testis," *Folia Morphologica*, vol. 66, no. 3, pp. 167–171, 2007.

[7] E. Uluçam and E. Bakar, "The effect of proanthocyanidin on formaldehyde-induced toxicity in rat testes," *Turkish Journal of Medical Sciences*, vol. 46, no. 1, pp. 185–193, 2016.

[8] M. Askaripour, A. Hasanpour, F. Hosseini et al., "The effect of aqueous extract of *Rosa damascena* on formaldehyde-induced toxicity in mice testes," *Pharmaceutical Biology*, vol. 56, no. 1, pp. 12–17, 2018.

[9] P. K. Majumder and V. L. Kumar, "Inhibitory effects of formaldehyde on the reproductive system of male rats," *Indian Journal Physiology and Pharmacology*, vol. 39, no. 1, pp. 80–82, 1995.

[10] M. Tang, Y. Xie, Y. Yi, and W. Wang, "Effects of formaldehyde on germ cells of male mice," *Journal of Hygiene Research*, vol. 32, no. 6, pp. 544–548, 2003.

[11] N. D. Betancourt-Martínez, J. Jiménez-Villarreal, P. Carranza-Rosales et al., "Sperm chromatin dispersion by formaldehyde in Wistar rats," *Genetics and Molecular Research*, vol. 14, no. 3, pp. 10816–10826, 2015.

[12] A. Gurel, O. Coskun, F. Armutcu, M. Kanter, and O. A. Ozen, "Vitamin E against oxidative damage caused by formaldehyde in frontal cortex and hippocampus: biochemical and histological studies," *Journal of Chemical Neuroanatomy*, vol. 29, no. 3, pp. 173–178, 2005.

[13] S. Zhang, H. Chen, J. Zhang, J. Li, H. Hou, and Q. Hu, "The multiplex interactions and molecular mechanism on genotoxicity induced by formaldehyde and acrolein mixtures on human bronchial epithelial BEAS-2B cells," *Environment International*, vol. 143, Article ID 105943, 2020.

[14] N. Mohammed, S. A. Ahmed, N. I. Hegazy, and K. Kashishy, "Ameliorative effects of hesperidin and *N*-acetylcysteine against formaldehyde-induced-hemato- and genotoxicity," *Toxicology Research*, vol. 10, no. 5, pp. 992–1002, 2021.

[15] I. A. Siddiqui, F. Afaq, V. M. Adhami, N. Ahmad, and H. Mukhtar, "Antioxidants of the beverage tea in promotion of human health," *Antioxidants and Redox Signaling*, vol. 6, no. 3, pp. 571–582, 2004.

[16] Z. Sayyar, A. Yazdinezhad, M. Hassan, and I. J. Anarkooli, "Protective effect of *Matricaria chamomilla* ethanolic extract on hippocampal neuron damage in rats exposed to formaldehyde," *Oxidative Medicine Cell Longevity*, vol. 2018, Article ID 6414317, 10 pages, 2018.

[17] H. Sebai, S. Selmi, K. Rtibi, N. Gharbi, and M. Sakly, "Protective effect of *Lavandula stoechas* and *Rosmarinus officinalis* essential oils against reproductive damage and oxidative stress in alloxan-induced diabetic rats," *Journal of Medicinal Food*, vol. 18, no. 2, pp. 241–249, 2015.

[18] S. Foster and C. Hobbs, *The Peterson Field Guide, Western Medicinal Plants and Herbs*, p. 202, Houghton Mifflin Co, New York, 2002.

[19] L. Bernardini, E. Barbosa, M. F. Charão, and N. Brucker, "Formaldehyde toxicity reports from in vitro and in vivo studies: a review and updated data," *Drug and Chemical Toxicology*, vol. 45, no. 3, pp. 972–984, 2022.

[20] B. O. Adetuyi, T. O. Okeowo, O. A. Adetuyi et al., "*Ganoderma lucidum* from red mushroom attenuates formaldehyde-induced liver damage in experimental male rat model," *Biology (Basel)*, vol. 9, no. 10, Article ID 313, 2020.

[21] M. Qamar, S. Akhtar, T. Ismail et al., "*Syzygium cumini* (L.), Skeels fruit extracts: in vitro and in vivo anti-inflammatory properties," *Journal of Ethnopharmacology*, vol. 271, Article ID 113805, 2021.

[22] M. Naghdi, M. Maghbool, M. Seifalah-Zade et al., "Effects of common fig (*Ficus carica*) leaf extracts on sperm parameters and testis of mice intoxicated with formaldehyde," *Evidence-Based Complementary and Alternative Medicine*, vol. 2016, Article ID 2539127, 9 pages, 2016.

[23] M. Raeeszadeh, B. Shokrollahi, N. Khademi, and A. Akbari, "Superior effect of broccoli methanolic extract on control of oxidative damage of sperm cryopreservation and reproductive performance in rats: a comparison with vitamin C and E antioxidant," *Theriogenology*, vol. 181, pp. 50–58, 2022.

[24] M. Raeeszadeh, M. Fallah, and E. S. Naghani, "The comparison of the effect of origanum vulgar aqueous extract and vitamin C on the control of cadmium chloride damage in testicular tissue in male rats," *Journal of Babol University of Medical Sciences*, vol. 20, no. 8, pp. 44–50, 2028.

[25] N. Li, Y. Xing, A. H. Sultan, M. Raeeszadeh, A. Akbari, and H. Liu, "Ginger (*Zingiber officinale* Roscoe) improves ethanol-induced reproductive dysfunction by enhancing steroidogenesis and inhibiting oxidative stress and inflammation," *Biological and Applied Sciences*, vol. 64, 2021.

[26] E. Viveros-Valdez, C. Rivas-Morales, P. Carranza-Rosales, S. Mendoza, and G. Schmeda-Hirschmann, "Free radical scavengers from the Mexican herbal tea "poleo" (*Hedeoma drummondii*)," *Journal of Biosciences*, vol. 63, no. 5-6, pp. 341–346, 2008.

[27] E. Viveros-Valdez, C. Rivas-Morales, A. Oranday-Cárdenas, J. Castro-Garza, and P. Carranza-Rosales, "Antiproliferative effect from the Mexican Poleo (*Hedeoma drummondii*)," *Journal of Medicinal Food*, vol. 13, no. 3, pp. 740–742, 2010.

[28] World Health Organization, *WHO Laboratory Manual for the Examination of Human Semen and Sperm-Cervical Mucus Interaction*, Cambridge University Press, Cambridge, 5th edition, 2010.

[29] J. L. Fernández, L. Muriel, M. T. Rivero, V. Goyanes, R. Vazquez, and J. G. Alvarez, "The sperm chromatin dispersion test: a simple method for the determination of sperm DNA fragmentation," *Journal of Andrology*, vol. 24, no. 1, pp. 59–66, 2003.

[30] Report on Carcinogens, "U.S. Department of Health and Human Services Public Health Service, National Toxicology Program," Formaldehyde, 2011.

[31] D. Adamović, Z. Čepić, S. Adamović et al., "Occupational exposure to formaldehyde and cancer risk assessment in an anatomy laboratory," *International Journal of Environmental Research and Public Health*, vol. 18, no. 21, Article ID 11198, 2021.

[32] D. Zhou, J. Zhang, and H. Wang, "Assessment of the potential reproductive toxicity of long-term exposure of adult male rats to low-dose formaldehyde," *Toxicology and Industrial Health*, vol. 27, no. 7, pp. 591–598, 2011.

[33] S. Vosoughi, A. Khavanin, and M. Salehnia, "Adverse effects of formaldehyde vapor on mouse sperm parameters and testicular tissue," *International Journal of Fertility and Sterility*, vol. 6, no. 4, pp. 250–267, 2013.

[34] Z.-J. Zang, Y.-Q. Fang, S.-Y. Ji et al., "Formaldehyde inhibits sexual behavior and expression of steroidogenic enzymes in the testes of mice," *The Journal of Sexual Medicine*, vol. 14, no. 11, pp. 1297–1306, 2017.

[35] X. Liu, Y. Zhang, and X. Yang, "Vitamin E reduces the extent of mouse brain damage induced by combined exposure to formaldehyde and PM2.5," *Ecotoxicology and Environmental Safety*, vol. 172, pp. 33–39, 2019.

[36] D.-X. Zhou, S.-D. Qiu, J. Zhang, H. Tian, and H.-X. Wang, "The protective effect of vitamin E against oxidative damage caused by formaldehyde in the testes of adult rats," *Asian Journal of Andrology*, vol. 8, no. 5, pp. 584–588, 2006.

[37] R. Kutlubay, E. O. Oğuz, B. Can, M. C. Güven, Z. Sinik, and O. L. Tuncay, "Vitamin E protection from testicular damage caused by intraperitoneal aluminium," *International Journal of Toxicology*, vol. 26, no. 4, pp. 297–306, 2007.

[38] R. M. Vigueras-Villaseñor, I. Ojeda, O. Gutierrez-Pérez et al., "Protective effect of α-tocopherol on damage to rat testes by experimental cryptorchidism," *International Journal of Experimental Pathology*, vol. 92, no. 2, pp. 131–139, 2011.

[39] B. Saygin, M. Esrefoglu, N. Bayindir et al., "Protection with thymoquinone against formaldehyde-induced neurotoxicity in the rats," *Bratislavské Lekárske Listy*, vol. 119, no. 11, pp. 726–730, 2018.

[40] B. Oluwafemi Adetuyi, T. Olamide Okeowo, O. Adefunke Adetuyi et al., "*Ganoderma lucidum* from red mushroom attenuates formaldehyde-induced liver damage in experimental male rat model," *Biology*, vol. 9, no. 10, Article ID 313, 2020.

[41] E. Bakar, E. Ulucam, and A. Cerkezkayabekir, "Protective effects of proanthocyanidin and vitamin E against toxic effects of formaldehyde in kidney tissue," *Biotechnic and Histochemistry*, vol. 16, pp. 1–10, 2014.

[42] P. Wei, X. Li, S. Wang et al., "Silibinin ameliorates formaldehyde-induced cognitive impairment by inhibiting oxidative stress," *Oxidative Medicine and Cellular Longevity*, vol. 16, Article ID 5981353, 13 pages, 2022.

[43] M. G. Buffone, J. C. Calamera, S. Brugo-Olmedo et al., "Superoxide dismutase content in sperm correlates with motility recovery after thawing of cryopreserved human spermatozoa," *Fertility and Sterility*, vol. 97, no. 2, pp. 293–298, 2012.

[44] J. G. Alvarez and B. T. Storey, "Role of glutathione peroxidase in protecting mammalian spermatozoa from loss of motility caused by spontaneous lipid peroxidation," *Gamete Research*, vol. 23, no. 1, pp. 77–90, 1989.

[45] T. G. Atere and O. A. Akinloye, "High dose of standardised extract of *Costus afer* leaves potentiates cadmium reproductive toxicity in Wistar rats," *Andrologia*, vol. 51, no. 9, Article ID e13360, 2019.

[46] M. David, Q. U. Ain, M. Ahmad, W. Zaman, and S. Jahan, "A biochemical and histological approach to study antifertility effects of methanol leaf extract of *Asplenium dalhousiae* Hook. in adult male rats," *Andrologia*, vol. 51, no. 6, Article ID e13262, 2019.

[47] M. I. Ngaha Njila, D. Massoma Lembè, B. L. Koloko et al., "Sperm parameters quality and reproductive effects of methanolic

extract of *Alchornea cordifolia* leaves on senescent male rats," *Andrologia*, vol. 51, no. 9, Article ID e13359, 2019.

[48] G. Ciftci, A. Aksoy, S. Cenesiz et al., "Therapeutic role of curcumin in oxidative DNA damage caused by formaldehyde," *Microscopy Research Technique*, vol. 78, no. 5, pp. 391–395, 2015.

[49] M. Paul, M. S. U. Sohag, A. Khan, R. K. Barman, M. I. I. Wahed, and M. R. I. Khan, "Pumpkin (*Cucurbita maxima*) seeds protect against formaldehyde-induced major organ damages," *Heliyon*, vol. 6, no. 8, Article ID e04587, 2020.

[50] S. Aydin, M. Ogeturk, T. Kuloglu, A. Kavakli, and S. Aydin, "Effect of carnosine supplementation on apoptosis and irisin, total oxidant and antioxidants levels in the serum, liver and lung tissues in rats exposed to formaldehyde inhalation," *Peptides*, vol. 64, pp. 14–23, 2015.

[51] H. Khosravanian, M. Razi, F. Farokhi, and N. Khosravanian, "Simultaneous administration of dexamethasone and vitamin E reversed experimental varicocele-induced impact in testicular tissue in rats; correlation with Hsp70-2 chaperone expression," *International Brazilian Journal of Urology*, vol. 41, no. 4, pp. 773–790, 2015.

[52] S. Jahan, A. Zahra, U. Irum, N. Iftikhar, and H. Ullah, "Protective effects of different antioxidants against cadmium induced oxidative damage in rat testis and prostate tissues," *Systems Biology in Reproductive Medicine*, vol. 60, no. 4, pp. 199–205, 2014.

[53] E. Köse, M. Sarsılmaz, U. Taş et al., "Rose oil inhalation protects against formaldehyde-induced testicular damage in rats," *Andrologia*, vol. 44, no. 1, pp. 342–348, 2012.