Original Research

Saffron (*Crocus sativus* L.) based protection against Aflatoxin B1 induced haematological and organ damages in rats

Hayat Ashi [1,2], Enas A. Hamed [3], Bassem Refaat [4], Shakir Idris [4], Latifa Khayyat [1,2], Tasahil S. Albishi [1,2], Leena A. Neyaz [1,2], Outour Tariq Alami [1,2], Fatimah Al-Rahmani [5], Shirin Aashi [6], Abdulaziz A. Alamri [6], Ghazi H. Abduljawad [6], Ayman A. Alobaidi [6], Fahad A. Alburberry [6], Saleh H. Alsalhi [6], Rayyan M. Wali [6], Khaled Elbanna [1,2,7], Hussein H. Abulreesh [1,2*]

Abstract

Saffron is well-known for its anti-apoptotic, anti-inflammatory, and antioxidant properties. Saffron's nutritional and medicinal properties support its numerous uses as a flavouring and herbal remedy. This study investigated the protective efficacy of saffron administration against aflatoxin B1 (AFB1)-induced toxicity in adult male Wistar albino rats during an experimental period of 21 days. Aflatoxin B1 (AFB1) is a common mycotoxin of soils and foodstuffs. Thirty-two rats were divided into four groups (Control group, AFB1 group, Saffron group, and AFB1+ Saffron group), and their body weights were measured on days 1, 7, 14, and 21. Blood samples were collected on the 21st day for haematological and biochemical studies (testosterone, kidney and liver function tests, and oxidative stress markers). Tissue samples from testes, liver, and kidney were subjected to histological examinations. The results depicted a significant decrease in the body weights after 7, 14, and 21 days of Saffron, AFB1, and AFB1+ Saffron treatments in comparison to control. Haematological investigations showed that basophils, platelets, monocytes, lymphocytes, and eosinophils greatly increased compared to the control group, whereas neutrophils and eosinophils dramatically decreased. There was a significant rise in the serum levels of uric acid, creatinine, aspartate transaminase, alkaline phosphatase, nitric oxide, and malondialdehyde. Contrarily, testosterone levels notably reduced in AFB1-

1 Department of Biology, Faculty of Science, Umm Al-Qura University, Makkah 21955, Saudi Arabia

2 Research Laboratories Unit, Faculty of Science, Umm Al-Qura University, Makkah 21955, Saudi Arabia

3 Department of Medical Physiology, Faculty of Medicine, Assiut University, Assiut, Egypt

4 Department of Clinical Laboratory Sciences, Faculty of Applied Medical Sciences, Umm Al-Qura University, Makkah 21955, Saudi Arabia

5 Department of Chemistry, Faculty of Science, Umm Al-Qura University, Makkah 21955, Saudi Arabia

6 College of Pharmacy, King Abdulaziz University, Jeddah, Saudi Arabia

7 Department of Agricultural Microbiology, Faculty of Agriculture, Fayoum University, Fayoum 63514, Egypt

administered rats as compared to controls. AFB1 group exhibited several histological modifications in testes, liver, and kidney tissues. Oxidative stress biomarkers, testosterone, kidney and liver functions, and haematological parameters of the AFB1+ Saffron group remained similar to the control group. Kidney and liver tissues of Saffron-treated rats also displayed normal structure similar to the control group, which confirmed its protective efficacy against AFB1-induced toxicity. Saffron's bioactive components and antioxidant and pharmacological properties might have contributed to its promising anti-AFB1-toxicity potential.

Keywords

Aflatoxin B1, Antioxidant, Hemotoxicity, Hepatotoxicity, Nephrotoxicity, Saffron, Testosterone, Oxidative stress.

* **Corresponding author:**
E-mail address: hhabulreesh@uqu.edu.sa

Citation: Ashi, H., Hamed, E. A., Refaat, B., Idris, S., Khayyat, L., Albishi, T. S., Neyaz, L. A., Alami, O. T., Al-Rahmani, F., Aashi, S., Alamri, A. A., Abduljawad, G. H., Alobaidi, A. A., Alburberry, F. A., Alsalhi, S. H., Wali, R. M., Elbanna, K., Abulreesh H. H., (2024). Saffron (*Crocus sativus* L.) based protection against Aflatoxin B1 induced haematological and organ damages in rats. Acta Biologica Slovenica 67 (3)

Received: 14.06.2024 / **Accepted:** 06.09.2024 / **Published:** 17.09.2024

https://doi.org/10.14720/abs.67.3.18966

This article is an open access article distributed under the terms and conditions of the Creative Commons Attribution (CC BY SA) license

Žafran (*Crocus sativus* L.) kot zaščita pred poškodbami organov in hematološkimi spremembami pri podganah zaradi aflatoksina B1

Izvleček

Žafran je znan po svojih anti-apoptotičnih, protivnetnih in antioksidativnih lastnostih. Prehranske in zdravilne lastnosti žafrana podpirajo njegovo številno uporabo kot začimbe in zeliščnega zdravila. V tej študiji je bila raziskana zaščitna učinkovitost žafrana pred delovanjem aflatoksina B1 (AFB1), pri odraslih samcih podgan Wistar albino v poskusnem obdobju 21 dni. Aflatoksin B1 (AFB1) je pogost mikotoksin v tleh in živilih. V poskusu smo 32 podgan razdelili v štiri skupine (kontrolna skupina, skupina z AFB1, skupina z žafranom in skupina z AFB1 + žafran). Njihovo rast smo spremljali preko telesne teže 1., 7., 14. in 21. dan. Ob zaključku poskus smo 21. dan odvzeli vzorce za hematološke in biokemične analize (testosteron, testi delovanja ledvic in jeter ter markerji oksidativnega stresa). Vzorci tkiva semenčic, jeter in ledvic so bili predmet histoloških preiskav. Rezultati so pokazali znatno zmanjšanje telesne teže po 7, 14 in 21 dneh zdravljenja z žafranom, AFB1 in AFB1+ žafranom v primerjavi s kontrolo. Hematološke preiskave so pokazale, da so se bazofili, trombociti, monociti, limfociti in eozinofili močno povečali v primerjavi s kontrolno skupino, medtem ko so se nevtrofilci in eozinofilci močno zmanjšali. V serumu so se znatno povečale vrednosti sečne kisline, kreatinina, aspartatne transaminaze, alkalne fosfataze, dušikovega oksida in malondialdehida. Nasprotno pa se je raven testosterona pri podganah, ki so prejemale AFB1, v primerjavi s kontrolami opazno zmanjšala. Pri skupini z AFB1 so se pokazale številne histološke spremembe v testisih, jetrih in ledvicah. Biomarkerji oksidativnega stresa, testosteron, delovanje ledvic in jeter ter hematološki parametri skupine z AFB1+ žafranom so ostali podobni kontrolni skupini. Tudi ledvična in jetrna tkiva podgan, zdravljenih z žafranom, so imela normalno strukturo, podobno kontrolni skupini, kar je potrdilo njegovo zaščitno učinkovitost pred toksičnostjo, povzročeno z AFB1. Bioaktivne sestavine žafrana ter njegove antioksidativne in farmakološke lastnosti so morda prispevale k njegovemu obetavnemu potencialu proti toksičnosti AFB1.

Ključne besede

Aflatoksin B1, antioksidanti, hemotoksičnost, hepatotoksičnost, nefrotoksičnost, žafran, testosteron, oksidativni stres

Introduction

Mycotoxin pollution has emerged as a global phenomenon in recent years. Hazardous aflatoxins (AF) of *Aspergillus parasiticus* and *A. flavus* can infect agricultural produce during harvesting, storage, and processing. Airborne particulate matter can also spread aflatoxin during the storage and processing of contaminated cereal crop products, which increases the aflatoxin exposure risk in animals and humans. Aflatoxin can also be found in food products such as milk, eggs, and ruminant meat that are fed on contaminated diets (Rushing and Selim, 2019). A. parasiticus produces four types of aflatoxins (B1, B2, G1, and G2), whereas A. flavus produces two types of aflatoxins (B1 and B2) (Mtimet et al., 2015).

Aflatoxin B1 (AFB1) is highly detrimental that can cause growth retardation, mutagenesis, and carcinogenesis (Shabeer et al., 2022). The genotoxicity of AFB1 can also impair the testes, kidneys, heart, and liver. However, its toxicity mechanisms require further elucidation (Dai et al., 2017). Aflatoxins' purity in the foodstuff could reveal the mechanism of its successful growth in target organs. For instance, in the liver as a primary target, the toxin purity might also affect heart cells, kidneys, and lungs (Karmanov et al., 2021).

Crocus sativus L., a perennial herb of the Iridaceae family, is grown in various countries such as Mexico, China, France, Morocco, Iran, Turkey, Azerbaijan, Egypt, Greece, Spain, India, and Italy. There are three primary saffron constituents such as (a) crocin, the main colouring agent (mono- and diglycosyl esters of a polyene dicarboxylic acid known as crocetin), (b) glycoside picrocrocin, the safranal precursor, adds bitter taste, and (c) safranal, a monoterpene aldehyde (deglycosylated picrocrocin), that produces distinctive saffron aroma (Rezaee and Hosseinzadeh, 2013). The dried stigma of the C. sativus plant (saffron) is a commonly used spice and culinary colouring agent (Rezaee and Hosseinzadeh, 2013). Recent pharmacological studies have revealed that saffron and its bioactive components can reduce male erectile dysfunction and possess antioxidant, anti-inflammatory, and antinociceptive characteristics (Hosseinzadeh and Shariaty, 2007). This study elaborated on the protective effects of oral saffron extract administration (21 days) against hazardous impacts of AFB1 on the haematological parameters, liver, kidneys, and testes of adult male Wistar albino rats.

Materials and Methods

Animals

Thirty-two healthy adult male Wistar albino rats (180–200g, 7-8 weeks old) were obtained from King Fahd Medical Research Centre, King Abdulaziz University, Jeddah, Saudi Arabia. The rats were kept in clean, sterile polypropylene cages and exposed to a 12-hour light/dark cycle during the experimental period (4 weeks). To acclimatize, the rats were housed in air-conditioned rooms (21-23°C and 60-65% humidity) for one week before the initiation of experimental procedures. The rats had free access to a basic chow diet and tap water. The experiment protocol was approved by the Ethical Committee of King Fahd Medical Research Centre, Jeddah, Saudi Arabia (Approval # 163-19). ARRIVE guidelines were followed to carefully handle the experimental rats.

Reference fungal isolate

Aflatoxin-producing *Aspergillus flavus* CYA reference strain (AUMC 9779) was provided by Professor Ahmed Y. Abdelmalek, Moubasher Mycological Centre, Assiut University, Egypt. The isolate was inoculated on Potato Dextrose agar (PDA) slants and stored at five °C for short-period preservation (10-20 days) and -80°C (cryogenic temperature) for long-term preservation (more than six months).

Local fungal isolate

To obtain a local Saudi Arabian isolate, a loopful of spores was scrapped off from mouldy bread and cultured on PDA plates. PDA was prepared by adding freshly prepared potato extract (4.0g), glucose (20 g) (BDH Chemicals Ltd, England), and agar (20 g) (MOLEQULE-ON, New Zealand) to distilled water (1000 ml). The mixture was boiled to dissolve the agar, sterilized, and poured into plates. The isolate was also retrieved in parallel by using Sabouraud dextrose agar (SDA) (HiMedia, India). Both media (PDA and SDA) were incubated for 5 to 7 days at 25±2 °C (Fakruddin et al., 2015; Ashi et al., 2023 a, b). Then, a cork pourer was used to inoculate the fungal disk on *Aspergillus* differential agar [tryptone (15 g), yeast extract (10 g), ferric citrate (0.5 g), agar (15 g), and distilled water (1000 ml)]. The media was boiled and autoclaved before usage (Sreekanth et al., 2011; Ashi et al., 2023a, b).

Maintaining and storage of the isolates

The long-duration storage of isolates was carried out by culturing A. flavus isolate on SDA plates and incubating (25 ± 2 °C) for 5 to 7 days. Then, A. flavus colonies were inoculated into a sterile glycerol solution (15%) in sterile microfuge tubes (250 µl). These tubes were preserved at -80 °C to maintain fungal spores' vitality (Nielsen and Smedsgaard, 2003).

Preparation of broth media

A 500 ml of Sabouraud dextrose broth (SDB) (HiMedia) was prepared by following the manufacturer's guidelines. SDB aliquots (150 ml) were autoclaved (121 °C, 15 min, and 1.5 atmospheric pressure) in 250 ml flasks. The flasks were kept in the refrigerator until utilized.

Production, extraction, and determination of aflatoxin from *A. flavus*

A. flavus isolate was cultivated (25±2°C) in SDB under aerobic and shaking conditions for 5 to 14 days. Then, a sterile funnel was used to filter the culture through sterile filter papers (MN 615 - ∅ 150 mm) into a flask. The filtrates were transferred to sterile conical tubes (15ml) (Plastilab) and left overnight at cryogenic -80°C to weaken the fungal cell walls. It helped in better solvent penetration into the cell for secondary products' extraction (Saldan et al., 2018; Ashi et al., 2023a, b). The contents were transferred to a methanol-containing (15 ml) hydrophilic bottle and subjected to ultrasonic vibration for 30 min (Nielsen and Smedsgaard, 2003; Ashi et al., 2023a, b). Then, it was placed in an orbital shaker (100 rpm, 30 min), and the step was repeated several times. Finally, the extract was filtered through micropore (Bedford, USA) filter paper in a sterile glass funnel. The filtrate was evaporated under a nitrogen flow. This concentrated extract was dissolved in methanol (1.5 ml) and subjected to Gas Chromatography (GC) (Shimadzu, Kyoto, Japan) and high-performance liquid chromatography (HPLC) (Shimadzu, Kyoto, Japan) (Bertrand et al., 2013; Ashi et al., 2023a, b). Aflatoxin presence was confirmed by comparing with standard crude AFB1 extract (Ashi et al., 2023a, b).

Confirmation of aflatoxin production

A. flavus-based aflatoxin production was quickly confirmed according to the Ammonia vapour method, which turned toxin-secreting colonies to pink on PDA and SDA culture plates. Ammonia solution (25%) was prepared by adding ammonia (25 ml) into distilled water (75 ml). This solution (0.2 ml) was added to the Petri dish followed by incubation (24 hours, 25°C), which yielded a red colour at the bottom of fungal colonies (Saito and Machida, 1999; Ashi et al., 2023a, b).

Preparation of saffron extract

Dried saffron threads were purchased from Afghanistan Saffron Co. (Herat, Afghanistan). Saffron extract was prepared by adding saffron (90 mg) to distilled water (200 ml) at 80°C. The solution was left for five minutes and filtered.

Experimental design

Thirty-two adult male Wistar rats were randomly divided into four groups of eight rats. The first group was orally administered a basal diet, which served as the negative control. The second group was orally administered with saffron extract (80 mg/kg) for 21 days and fed on the basal diet (Mashmoul et al., 2016). The third group was orally administered with Aflatoxin B1 (1 mg/ kg) for 21 days and fed on the basal diet (Rotimi et al., 2019). The fourth group was orally administered with aflatoxin + saffron extract (AFB1 1 mg/ kg + Saffron 80 mg/kg) for 21 days and fed on the basal diet (Türk et al., 2008).

Biological and biochemical studies

Rats' body weight was measured on the 1st, 7th, 14th, and 21st days using a digital scale. After the completion of the experimental period, the rats were anaesthetized (isoflurane) and sacrificed by cervical dislocation. Blood samples (6 ml) were collected following the procedure for orbital sinus blood samples collection (Parasuraman et al. 2010) in two tubes (a plain tube and an EDTA (ethylenediaminetetraacetic acid-containing tube). Briefly, the animals were scruffed with the thumb and forefinger of the non-dominant hand and the skin around the eye was pulled taut. A capillary was inserted into the medial canthus of the eye around 30 30-degree angles to the nose; with slight thumb pressure, the capillary entered the plexus/sinus, allowing the blood to flow into the tube (Parasuraman et al. 2010). Blood samples in plain tubes were centrifuged (6000xg, four °C) for 10 minutes. The serum was aliquoted and immediately frozen at -80°C until further analysis. Sera were used to analyze

liver functions [albumin, alkaline phosphatase (ALP), and aspartate transferase (AST)], kidney functions [urea and uric acid, creatinine using rat-specific ELISA kits (Bender Med-Systems GmbH, Wien, Austria) following the manufacturer's procedure, oxidative stress biomarkers [nitric oxide (NO), and malondialdehyde (MDA)] were determined using colourimetric nitric oxide assay kit (Thermo Fisher Scientific, Waltham, Massachusetts, USA) and rat malondialdehyde ELISA kit (Antibodies.com, Cambridge, UK) according to the manufacturers' instruction. Testosterone hormone was determined using a testosterone rat/mouse ELISA kit (Rocky Mountain Diagnostics Inc., Colorado Springs, USA) as described in the manufacturers' guidelines. Blood samples in EDTA tubes were examined for the complete blood count (CBC), haemoglobin, red blood cells (RBCs), platelets, mean corpuscular haemoglobin concentration (MCHC), mean corpuscular volume (MCV), mean corpuscular haemoglobin (MCH), white blood cells (WBCs), neutrophils, monocyte, lymphocyte, basophil, and eosinophil using Dymin DH36 Auto Hematology Analyzer (Wuhan Aliroad Medical Equipment Co. Ltd., Wuhan, China).

Histological examinations

The rats were sacrificed at the end of the experimental period. The abdomen and pelvis were dissected, whereas the testes, kidneys, and liver were excised, followed by cleaning with distilled water. A neutral formalin solution (10%) was initially used to fix the specimens, which were subjected to gradual ethanol (50–100%) dehydration and xylene-based cleansing, followed by paraffin embedding. Sections of 5mm thickness were cut and stained with eosin and hematoxylin. An experienced histopathologist examined the organ slices under a light microscope to assess the tissue alterations.

Determination of total phenolic and flavonoid contents in saffron

A standard HPLC system (maximum pressure < 400 bar) (Shimadzu, Kyoto, Japan) was employed to determine phenolic compounds in saffron. The procedure of Manchón et al. (2010) was followed to select the mobile phases, which revealed a much lower system back pressure as compared to other solvents such as methanol. It assisted in rapid analysis with a standard HPLC system. UV spectra were recorded between 210 and 800 nm, whereas chromatograms were registered at 280 and 380 nm.

Statistical Analysis

The experimental data was expressed as mean ± standard error of means (SEM) or mean ± standard deviation (SD). SPSS version 22 (Statistical Package for Social Sciences, IBM Corp., USA) was used for the data analysis. Shapiro-Wilk test revealed the normal value distributions. One-way ANOVA was performed to examine the data variance, whereas the means of the different groups were compared through Tukey's test at a significance level of P <0.05.

Results

Total phenolic and flavonoid contents

Table 1 presents the saffron contents. The total phenolics were calculated according to the methodology of Folin-Ciocalteu. Saffron (*C. sativus*) samples exhibited high content of phenolics, anthocyanins, and flavonoids. The presence of phenolics and anthocyanins was noted to be higher than flavonoids (Table 1 and Figure 1).

Identification of phenolic, flavonoid, and anthocyanin compounds in saffron

The compounds such as gallic acid, kaempferol-3-o-glucoside, gentisitic acid, syringic acid, catechol, and vanillin were identified in saffron samples (Table 2). The identified compounds presented a maximum absorption within a range of 272–380nm. Molecular formula and chemical structures of major identified compounds are shown in Table 2 and Fig. 2.

2,2-diphenyl-1-picrylhydrazyl (DPPH) radical scavenging activity

The purple-coloured DPPH can exist as a stable free radical at an absorbance wavelength of 520 nm. The interaction of antioxidants converts DPPH to a non-radical form, and the alteration of colour from purple to yellow confirms the antioxidant activity. The acceptance of electrons reduces the absorbance of DPPH with the conversion into a non-radical form. Fig. 3 exhibits the alterations in DPPH radical scavenging impacts of saffron and Beautlated hydroxy anisol (BHA) at various concentrations (0.1, 0.25, 0.50, and 0.75 mg/ml). The results depicted a higher DPPH radical scavenging efficiency of saffron than BHA.

Table 1. Total phenolic, flavonoid, and anthocyanin compounds in saffron samples (mean ±SD).

Tabela 1. Skupni fenoli, flavonoidi in antociani v vzorcih žafrana (povprečje ±SD).

Sample	Phenolic Content (mg gallic acid EQ/100g DW)	Flavonoid Content (mg catechine EQ/100g DW)	Anthocyanin content (mg cyanidin EQ/ 100g DW)
Saffron (0.25 mg)	1144.1 ± 93.45	104 ± 43.84	1109.11±87.37
Saffron (0.50 mg)	1353 ± 135.22	326.09±75.70	1435.09±152.24
Saffron (0.75 mg)	1876 ± 246.28	657±98.32	1690.11±387.62

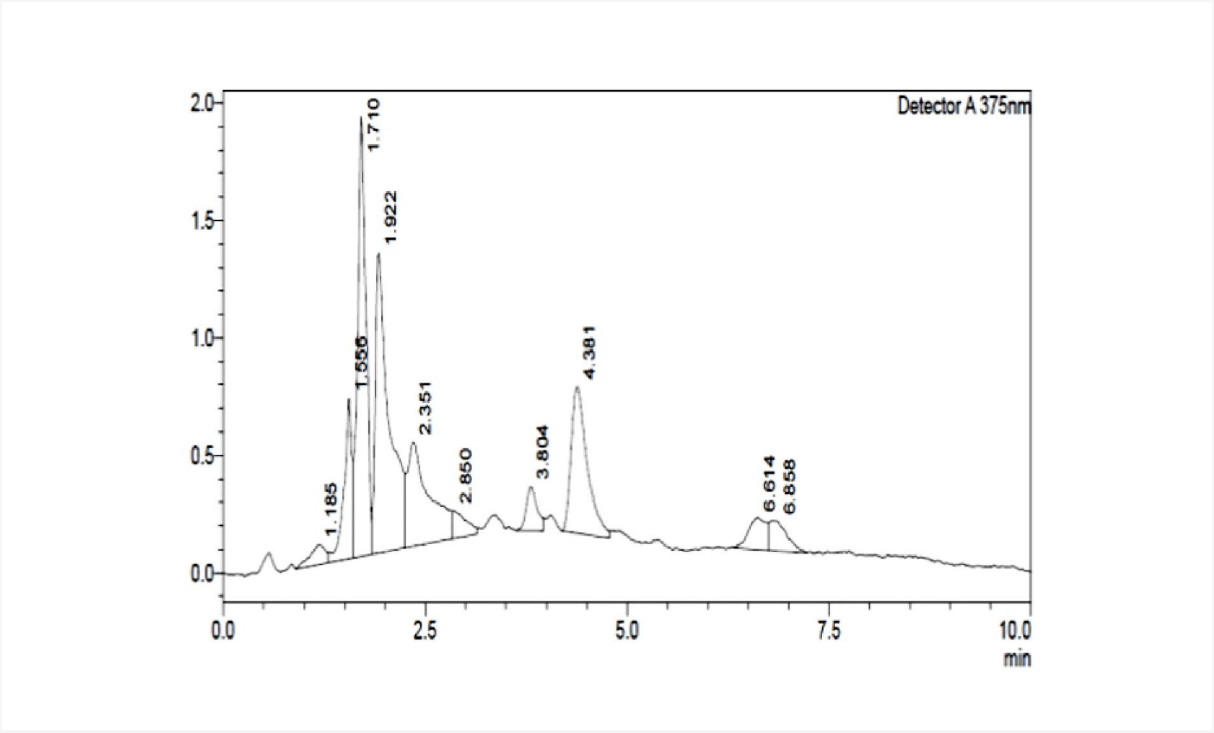

Figure 1. Identified compounds in saffron.

Slika 1. Identificirane snovi v žafranu.

Table 2. HPLC-MS-ESI based detection of major saffron compounds.

Tabela 2. HPLC-MS-ESI detekcija poglavitnih snovi v žafranu.

No.	Assignment compounds	(min)	UV data	$[M-H]^-$	Molecular formula
1	Gallic acid	1.71	380	169.9	$C_7H_6O_5$
2	Kaempferol-3-o-Glucoside	1.92	380	447.4	$C_{21}H_{19}O_{11}$
3	Gentisitic acid	2.35	380	154.12	$C_7H_6O_4$
4	Syringic acid	3.80	380	198.17	$C_9H_{10}O_5$
5	Catechol	4.38	380	110.11	$C_6H_6O_2$
6	Vanillin	6.61	380	152.14	$C_8H_8O_3$

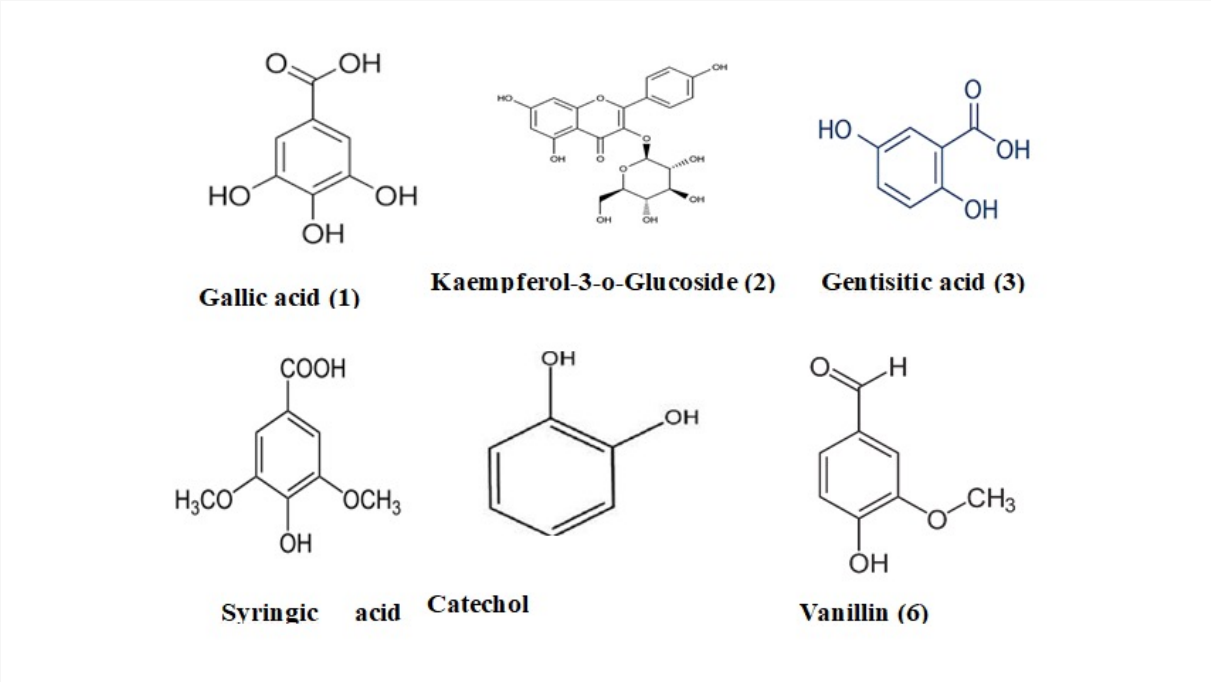

Figure 2. Chemical structures of major identified compounds in saffron.

Slika 2. Kemijska struktura pogavitnih identificiranih snovih v žafranu.

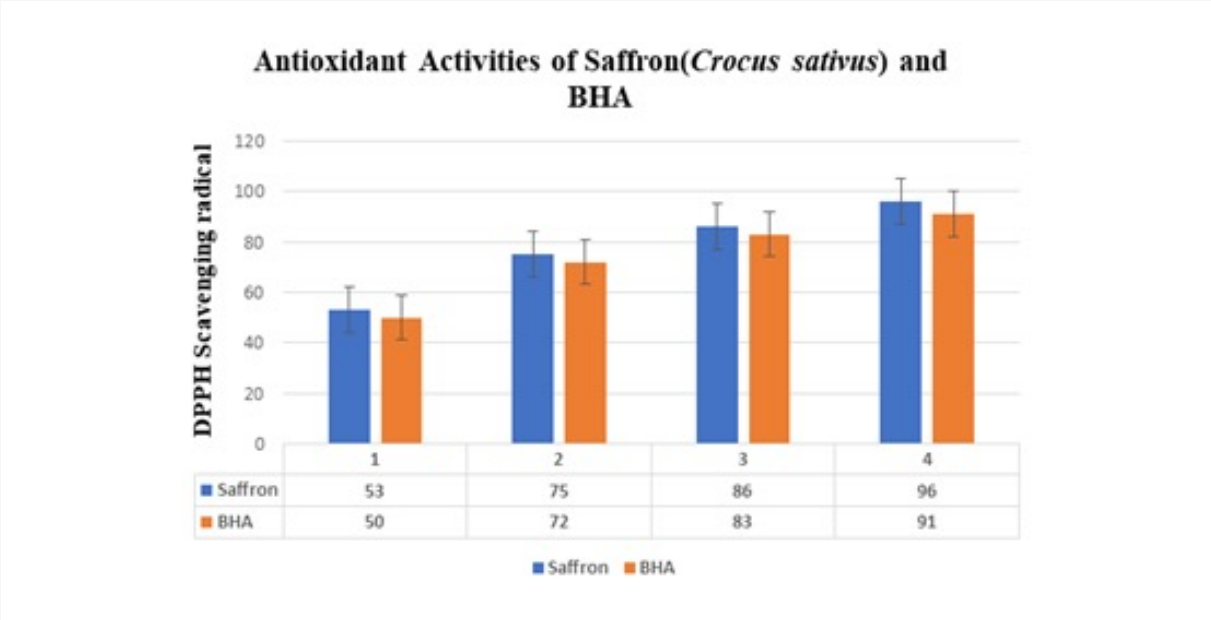

Figure 3. DPPH radical scavenging activity of saffron and BHA at 0.1, 0.25, 0.50, and 0.75 mg/ml. Each value represents mean ± SD of triplicate (n = 3) measurements. Means were compared using an unpaired t-test (* = $p < 0.05$, ns = non-significant).

Slika 3. Aktivnost DPPH v ekstrktu žafrana in BHA pri 0,1, 0,25, 0,50 in 0,75 mg/ml. Vsaka vrednost predstavlja povprečje ± SD meritev v treh ponovitvah (n = 3). Srednje vrednosti so bile primerjane z neparnim t-testom (* = $p < 0,05$, ns = nepomembno).

Animal weight

Table 3 reveals the impacts of Saffron, AFB1, and AFB1 + Saffron treatments on rat's body weight on the 1st, 7th, 14th, and 21st days. The body weight significantly decreased after 7, 14, and 21 days of treatment with Saffron ($P < 0.010$), AFB1 ($P < 0.0001$), and AFB1 + Saffron ($P < 0.0001$) in comparison to the control group. The highest rise in total body weight from 1st to the 21st day was noted in controls (9.97%) followed by the AFB1 group (4.34%), AFB1 + Saffron group (1.14%), and Saffron group (0.99%).

Haematological parameters

The results depicted insignificant changes in RBCs, MCV, MCH, and MCHC counts and haemoglobin content among Saffron, AFB1, and AFB1+ Saffron groups as compared to the control group. Meanwhile, platelet count was significantly increased in the AFB1 group than in the control ($P <0.010$), Saffron ($P <0.010$), and AFB1 + Saffron ($P <0.050$) groups. AFB1 group presented a significant rise in lymphocytes, monocytes, and basophil count in comparison to the control and Saffron groups ($P <0.001$). Contrarily, neutrophil and eosinophil counts significantly decreased in the AFB1 group as compared to the control and Saffron groups ($P <0.001$). AFB1 with Saffron combination improved neutrophil, lymphocytes, and eosinophil counts in comparison to the AFB1 group ($P <0.001$). However, neutrophil count was significantly reduced in the AFB1 group than in the control group ($P <0.001$), whereas a significant rise was noted in monocytes and basophils as compared to the control group ($P <0.001$ and $P <0.010$). Table 4 demonstrates the protective efficacy of saffron against blood toxicity.

Table 3. Rat body weight in response to Saffron, AFB1, and AFB1 + Saffron administrations after 7, 14, and 21 days of treatment.

Tabela 3. Telesna teža podgan glede na dodatek žafrana, AFB1 oz. AFB1 + žafran po 7, 14 in 21 dneh od tretiranja.

Variables	Control	Saffron	AFB1	AFB1 + Saffron
Body weight on 1st day (grams)	286.00±3.49	291.75±1.53	282.50±5.90	284.50±8.92
Body weight on 7th day (grams)	300.00±4.71	290.00±7.56†**	246.25±6.78†***	255.00±5.35†***
Body weight on 14thday (grams)	313.25±4.05	285.00±7.62†**	279.25±1.73†***	263.75±5.57†***
Body weight on 21st days (grams)	314.50±5.04	294.63±2.14 †**	294.75±3.64†**	287.75±4.08 †***
The ratio of the total increase in body weight (%)	9.97%	0.99%	4.34%	1.14%

Data is expressed as mean ± SEM. †: Significance versus control. *: $P <0.050$, **: $P <0.010$, ***: $P <0.0001$. The ratio of increase in total body weight (%) = Final body weight – initial body weight/ initial body weight X 100.

Table 4. Impact of Saffron, AFB1, and AFB1+ Saffron administrations (21 days) on rats' complete blood count (CBC).

Tabela 4. Vpliv žafrana, AFB1 in AFB1 + žafrana na krvne parametre po 21. dneh.

Variables	Control	Saffron	AFB1	AFB1 + Saffron
RBCs (X106/µL)	8.62±0.18	8.21±0.10	8.5±0.07	8.76±0.16
Hemoglobin (g/dL)	15.81±0.16	15.71±0.20	16.38±0.12	16.15±0.66
MCV (fL)	51.89±0.85	54.24±0.56	54.49±0.75	54.36±1.36
MCH (pg/dL)	18.49±0.39	19.04±0.27	19.18±0.13	18.51±0.33
MCHC (g/dL)	35.61±0.34	35.15±0.56	35.23±0.35	34.05±0.30
Platelets ($X10^3$/µL)	752.38±60.79	721.75±45.59†**	823.75±62.61‡**	799.63±43.62†*
WBCs ($X10^3$/µL)	10.15±1.32	10.70±0.52	10.82±1.23	10.93±1.13
Neutrophil ($X10^3$/µL)	12.88±0.17	12.65±0.16†***	6.59±0.06‡***	11.14±0.13‡***,†**
Lymphocytic ($X10^3$/µL)	8.03±2.04	8.60±3.79†***	9.41±0.54‡***	8.96±1.68†***
Monocyte ($X10^3$/µL)	1.50±0.05	1.45±0.08†***	8.26±2.11‡***	3.58±2.61†***
Eosinophil ($X10^3$/µL)	0.56±0.33	0.53±0.57	0.30±0.02‡***	0.84±0.22†***
Basophil ($X10^3$/µL)	0.72±0.11	0.25±0.04	2.21±0.23‡***	1.64±0.21‡**

Data is expressed as mean ± SEM.†: Significance versus Aflatoxin B1 ‡: Significance versus control; *: $P <0.050$; **: $P <0.010$; ***: $P <0.001$.

Kidney function test

A significant decrease was noted in the creatinine serum level of AFB1 + Saffron treated group than in the control and AFB1 treated groups (P <0.0001 and P <0.050). Serum levels of uric acid significantly increased in the AFB1 group as compared to the control and AFB1 + Saffron groups (P <0.0001). Contrarily, albumin serum levels significantly decreased in the Saffron, AFB1, and AFB1 + Saffron groups in comparison to the control group (P <0.050). The results depicted a significant rise in AST serum levels of the AFB1 group than in the control and AFB1 + Saffron groups (P <0.0001) (Table 5).

Serum testosterone levels and oxidative stress markers

The level of testosterone hormone was measured in serum to assess the testes' function. AFB1 and AFB1 + Saffron treatments caused a significant reduction in testosterone serum levels as compared to the control group (P <0.0001). Contrarily, a significant rise was noted in MDA and NO serum levels of the AFB1-treated group in comparison to the control and AFB1 + Saffron groups (P <0.0001) (Table 6).

Protective effects of saffron against aflatoxin-induced organ damage

The negative control and Saffron-treated rats presented normal renal histology (Fig. 4A, Fig. 4B). AFB1 administration caused drastic glomerular and tubular damage (Fig. 4C). It also induced severe hepatic injuries characterized by marked congestion, leucocytic infiltration, enlarged central veins, and large numbers of apoptotic/necrotic cells in comparison to the negative control and Saffron-treated groups (Fig. 5A, Fig. 5B, Fig. 5C). Moreover, AFB1 administered rats exhibited significant testicular damage that was characterized by interstitial degeneration, atrophy, and seminiferous tubules' disintegration with reduced number of cells (germ, Leydig, and Sertoli) as compared to the negative control and Saffron-administered groups (Fig. 6A, Fig. 6B, Fig. 6C). The co-administration of saffron and AFB1 effectively mitigated the renal (Fig. 4D), hepatic (Fig. 5D), and testicular (Fig. 6D) toxicities.

Table 5. Impact of Saffron, AFB1, and AFB1 + Saffron administrations (21 days) on kidney and liver functions of albino rats.

Tabela 5. Vpliv žafrana, AFB1 in AFB1 + žafrana na funkcije ledvic in jeter albino podgan po 21. dneh.

Variables	Control	Saffron	AFB1	AFB1 + Saffron
Kidney function tests				
Urea (mmol/L)	9.24±0.65	7.08±0.44	7.14±0.49	7.83±0.75
Creatinine (µmol/L)	48.23±1.77	50.18±2.17	44.43±0.74	37.19±1.41‡***,‡*
Uric acid (µmol/L)	57.30±7.00	52.53±3.04	117.76±7.32†***	67.93±3.33†***
Liver function tests				
Albumin (g/L)	38.63±0.46	32.75±1.11‡*	33.13±1.92‡*	32.38±1.49‡*
AST (U/L)	94.00±5.71	95.25±6.47	169.75±9.57‡***	94.38±7.20†***
ALP (U/L)	130.38±6.07	139.63±5.18	143.38±8.74	141.13±4.65

Data is expressed as mean ± SEM. †: Significance versus Aflatoxin B1 ‡: Significance versus control; *: P <0.050; **: P <0.010. ***: P <0.001.

Table 6. Impact of Saffron, AFB1, and AFB1 + Saffron administrations (21 days) on testosterone hormone and oxidative stress markers in male rats.

Tabela 6. Vpliv žafrana, AFB1 in AFB1 + žafrana na testosteron in markerje oksidativnega stresa pri podganjih samcih 21. dan po tretiranju.

Variables	Control	Saffron	AFB1	AFB1 + Saffron
Testosterone (nmol/L)	15.57±1.13	9.97±1.19	2.68±0.33‡***	3.80±00.18‡***
Oxidative stress markers				
MDA (µmol/L)	0.31±0.02	0.33±0.03	1.72±0.11‡***	0.39±0.06†***
NO (µmol/L)	27.75±0.41	28.38±1.05	83.00±4.06†***	28.38±0.73†***

Data is expressed as mean ±SEM. †: Significance versus Aflatoxin B1 ‡: Significance versus control; ***: P <0.001.

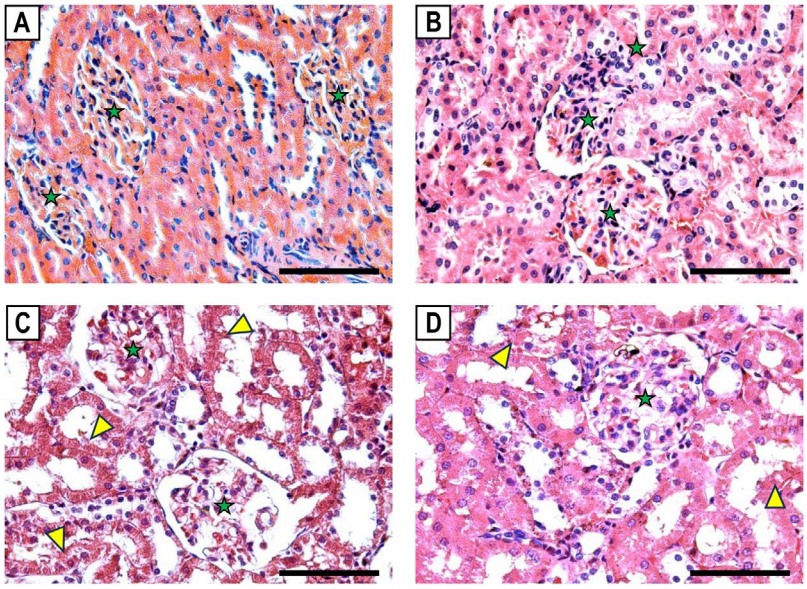

Figure 4. H&E staining of renal tissue sections of (A) negative control, (B) Saffron, (C) AFB1, and (D) AFB1 + Saffron groups (40× objective; scale bar = 10 µm; green star = glomerulus; yellow arrowhead = tubular damage).

Slika 4. H&E barvanje ledvičnega tkiva (A) negativne kontrole in tretmaja z (B) žafranom, (C) AFB1 ter (D) AFB1 + žafran (40x objektiv; črta označuje 10µm; zelena zvezda = glomerul; rumena puščica = poškodbe tubularnega tkiva).

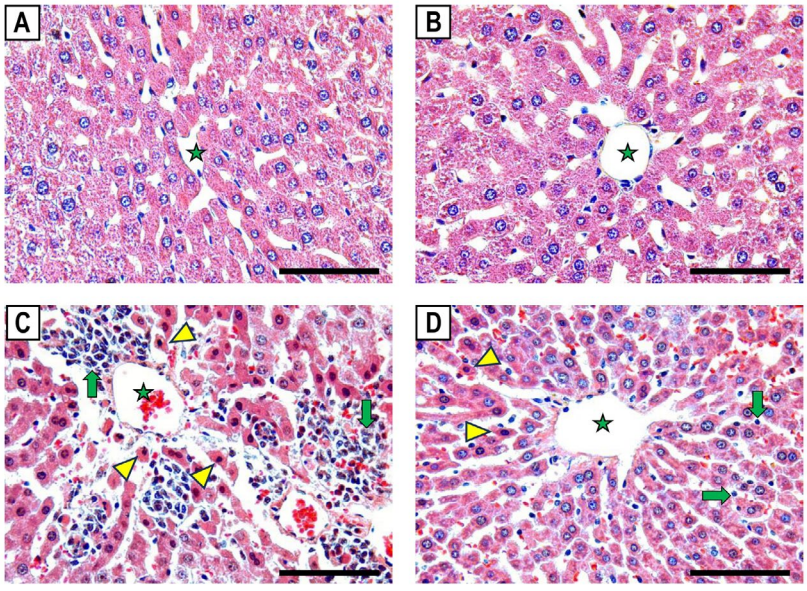

Figure 5. H&E staining of hepatic tissue sections of (A) negative control, (B) Saffron, (C) AFB1, and (D) AFB1 + Saffron groups (40× objective; scale bar = 10 µm; green star = central vein; green arrow = lymphocytic infiltration; yellow arrowhead = apoptotic/necrotic cells).

Slika 5. H&E barvanje jetrnega tkiva (A) negativne kontrole in tretmaja z (B) žafranom, (C) AFB1 ter (D) AFB1 + žafran (40x objektiv; črta označuje 10µm; zelena zvezda = osrednjo veno; zelena puščica = infiltracija limfocitov; umena puščica = apoptotične/nekrotične celice).

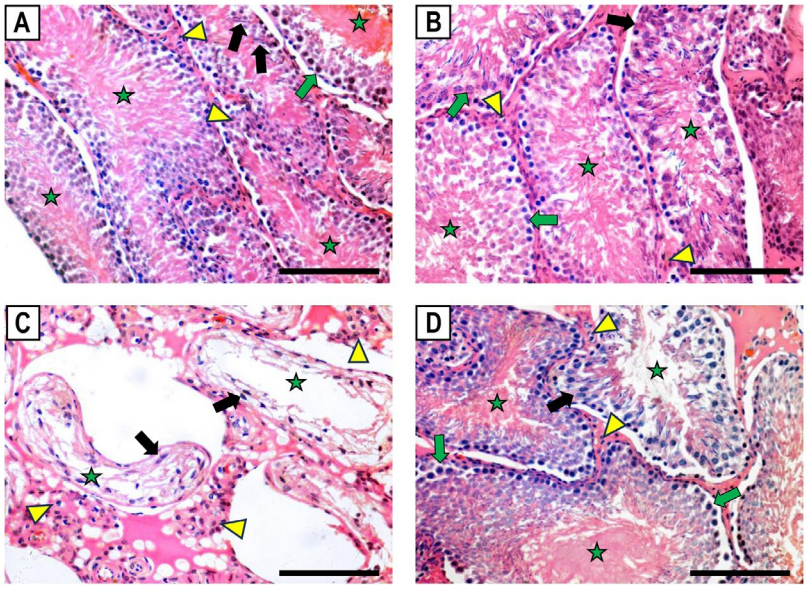

Figure 6. H&E staining of testicular tissue sections of (A) negative control, (B) Saffron, (C) AFB1, and (D) AFB1 + Saffron groups (40× objective; scale bar = 10 µm; green star = seminiferous tubules; green arrow = spermatogonia; black arrow = Sertoli cells; yellow arrowhead = Leydig cells).

Slika 6. H&E barvanje tkiva testisov (A) negativne kontrole in tretmaja z (B) žafranom, (C) AFB1 ter (D) AFB1 + žafran (40x objektiv; črta označuje 10µm; zelena zvezda = tubuli seminiferi; zelena puščica = spermatogonija; črna puščica = Sertolijeve celice; rumena puščica = Leydigove celice).

Discussion

Highly toxic aflatoxins are widely detected in human food and animal feed. The toxic impacts of aflatoxins can be mitigated by the use of medicinal plants. This study investigated the protective effect of the saffron extract on AFB1 toxicity in haematological parameters and multiple organs of male Wistar albino rats. Moreover, the protective efficacy of oral Saffron administration (21 days) against AFB1-induced toxicity was also elaborated. The data demonstrated a significant weight reduction in the AFB1-treated group after 7 and 14 days compared to the control group. There was a 4.34% increase in the total body weight ratio of the AFB1 group from the 1st to the 21st day. A significant body weight reduction has been reported in AFB1-treated (10, 20, or 50 mg/kg) rats (Supriya et al., 2014). Ahamad et al. (2015) reported duration and dose-dependent reduction in body weight in response to long-term AFB1 administration. Khaled and Thalij (2021) revealed that feeding AFB1-contaminated corn for 21 days decreased rats' body weight and ratio of weight gain.

During this study, the Saffron and AFB1+ Saffron groups experienced a significant decrease in body weight after 7, 14, and 21 days of treatment compared to the control group. However, there was a rise in the total body weight ratio from the 1st to 21st day in the Saffron (0.99%) and AFB1 + Saffron (1.14%) groups. Multiple studies have reported decreased rat appetite in response to ethanolic saffron stigma extract treatment, which resulted in significantly reduced body weight (Noorbala et al., 2005; Akhoundzadeh et al., 2008). Hariri et al. (2010) stated that crocin and safranal administrations remained unable to protect or suppress diazinon intake-related weight loss (Hariri et al., 2010). Thomson et al. (2009) reported insignificantly different rat body weights after four weeks of feeding on saffron water (3 mg/L) in comparison to the control group (Thomson et al., 2009).

The current results demonstrated insignificant haematological changes (WBCs, RBCs, haemoglobin content, MCV, MCHC, and MCH) in AFB1-treated as compared to the control group. A significant alleviation was noted in neutrophil and eosinophil counts of the AFB1 group, whereas platelet, lymphocytes, monocytes, and basophil counts were significantly higher in the AFB1 group than in the control group. A high count of lymphocytes and monocytes represented the

AFB1-associated inflammation and toxicity, which stimulated the body's immune responses. Husain et al. (2014) have also reported reduced RBC count and haemoglobin content and high WBC count in AFB1-contaminated diet-fed (1mg/kg) rats. Another study revealed that AFB1 feeding decreased the RBC count and haemoglobin content while simultaneously increasing the WBCs in laboratory animals (Ramamurthy and Rajakumar, 2016). Khaled and Thalij (2021) also reported a significant reduction in blood parameters (haemoglobin contents and RBC count) of AFB1-fed rats (39.5 µg/kg), whereas only insignificant differences were found at lower AFB1 concentrations (32.7, 37.9, and 29.0 µg/kg). They noted significantly increased WBCs in AFB1-fed rats (39.5, 32.7, 37.9, and 29.0 µg/kg). A low RBC count in AFB1-treated rats could be associated with anaemia because of the down-regulation of liver and kidney-secreted erythropoietin hormone activity. Similarly, a low erythrocyte volume is caused by defective heme-biosynthesis in bone marrow or a low erythropoietin formation rate, which results in lower haemoglobin levels. Contrarily, higher WBC count (mainly neutrophils) could be attributed to the cellular inflammatory response. The varying results of the current study from previous reports studies might be due to different AFB1 doses, treatment periods, and animal types.

The haematological parameters of the Saffron group remained similar to the control group during the experimental period. The AFB1 group experienced a significant rise in platelet, lymphocyte, monocyte, and basophil counts, whereas a significant reduction was noted in neutrophil and eosinophil counts compared to the Saffron group. These findings are in line with a previous study, which revealed that the injection of saffron aqueous extract (50, 100, and 200 mg/kg) thrice a week for four weeks didn't affect rats' CBC (Moallem et al., 2014). The combination of AFB1 + Saffron improved the platelet, monocyte, lymphocyte, and basophil counts as compared to the AFB1-treated group. The neutrophil count significantly decreased; however, a significant rise was noted in monocytes and basophils in the AFB1 + Saffron group compared to the control group. Babaei et al. (2014) reported that i.p injection of saffron petal extract (75, 150, 225, and 450 mg/kg) for 14 days did not alter the haemoglobin content, RBCs, MCH, MHCH, and MCV. However, a significantly increased WBC count indicated the immunomodulatory potential of saffron petals. The present study also indicated the beneficial impacts of saffron in protecting adult male rats' blood against AFB1-induced toxicity.

AFBI toxicity mainly affects the kidneys and liver (Yilmaz et al., 2018). The results depicted a significant rise in liver enzyme activities and renal parameters, whereas albumin was significantly reduced in the AFB1-treated group as compared to the control group. Kheir Eldin et al. (2008) confirmed a considerable increase in ALP, AST, and ALT serum levels in AFB1-administered rats (250 mg/kg/day for two weeks), which indicated the liver cells' dysfunction. Several studies have reported similarly high levels of ALP, AST, ALT, bilirubin, urea, and creatinine in AFB1-administered rats in comparison to controls (Rotimi et al., 2019; Khaled and Thalij, 2021; Karaca et al., 2021). The reason for the increase in liver enzyme activity can be because of the liver exposure to AFB1-induced damage to hepatocytes and increased membrane permeability that stimulates the release of liver enzymes into the bloodstream leading to high serum levels (Wang et al., 2020). The degeneration of the biliary system and hepatic tissues is indicated by higher levels of transaminases, bilirubin, and alkaline phosphatase (Owumi et al., 2019).

The results of this study demonstrated improved liver and kidney functions in AFB1 + Saffron-administered rats than in the AFB1 group. Moreover, uric acid, AST, creatinine, and albumin serum levels remained similar to the control group, which confirmed the protective efficacy of saffron against AFB1-induced hepato-renal toxicity. A study evaluated the hepatoprotective effects of saffron extract against acetaminophen toxicity in male Wistar rats. Saffron lowered AST, ALT, and bilirubin levels and significantly increased total protein and albumin (Omidi et al., 2014). Saffron's crocin and crocetin content contribute to its protective role against AFB1-induced DNA damage and hepatotoxicity by reducing hepatic injury markers [γ-GGT, ALP, AST, and ALT)] and enhancing hepatic glutathione peroxidase (GPX), glutathione S transferase (GST), and glutathione (GSH) in animal models (Giaccio, 2004). Anlin et al. (2000) reported the curative efficacy of saffron extract against carbon tetrachloride (CCl4) and alcohol-linked liver toxicities in rats. Shati and Alamri (2010) reported reduced aluminium (AlCl3)-induced hepatotoxicity in response to saffron treatment with significantly improved lipid peroxidation and liver biochemical markers (γ-GGT, triglycerides, cholesterol, ALT, AST, and ALP levels) (Shati and Alamri, 2010). Saffron's hepatoprotective effects against CCl-4-related liver damage could be due to (a) hepatic cell membrane fixation, (b) radical scavenging and antioxidant properties, and (c) alleviated CCl-4 metabolic activity via cytochrome

P450 inhibition (Iranshahi et al., 2011). The crocin content of saffron is also well known for protection against kidney damage (Yuan et al., 2014; Altinoz et al., 2015; Yarijani et al., 2017). Mahmoudzadeh et al. (2017) demonstrated that saffron extract treatment effectively reduced ischemia/reperfusion (I/R)-associated acute kidney injury.

This study detected the presence of gallic acid, vanillin, kaempferol-3-o-glucoside, syringic acid, gentisitic acid, and catechol in saffron. Esmaeili et al. (2011) have reported similar compounds in saffron through thin-layer chromatography (TLC). Moreover, Pandita (2021) has established phenolics-based antioxidant properties of saffron, which confirms their protection impacts against toxicity. Multiple studies have attributed the pharmacological and biological activities of saffron extract to its bioactive ingredients. Crocin is considered the main component that contributes to its pharmacological activity. Other saffron metabolites (terpenes, anthocyanins, flavonoids, and carotenoids) are also known for their pharmacological properties such as hypolipidemic, antioxidant, satiety enhancer, anti-inflammatory, hypoglycemic, antitumor, antihypertensive, neuroprotective, antidepressant, anti-diabetic, and antianxiety (Bolhassani, 2018; Lahmass et al., 2021). During this study, AFB1 administration (21 days) significantly enhanced the NO and MDA serum levels compared to the control, which are associated with continuous free radical production and incapacitated protection against antioxidants. Similarly, a study has linked the AFB1-related enhanced MDA and NO levels with DNA damage and mitochondrial dysfunction (Karaca et al., 2021).

The phenolic compounds of saffron (gallic acid, syringic acid, kaempferol-3-o-glucoside, and gentisitic acid) detected during this study might be responsible for the antioxidant, anti-inflammatory, and anti-toxicity properties. Mirhadi et al. (2020) have also reported bioactive components in saffron (Safranal, Crocin, Picrocrocin, and Crocetin) and their antioxidant properties. During the current study, AFB1+ Saffron treatment significantly mitigated the oxidative stress biomarkers, NO, and MDA as compared to the AFB1 group. NO and MDA levels appeared to be similar to the control group, which confirmed saffron's protection against AFB1-induced oxidative stress. Daryoush and Yousef (2012) stated that the ethanolic extract of saffron reduced lipid peroxidation and improved the antioxidant enzyme activities (CAT, SOD, and GSH) in cisplatin-treated rats' liver (Daryoush and Yousef, 2012). Pan et al. (2013) suggested that saffron regulates protein oxidation to reduce hepatic injury. Koul and Abraham (2017) demonstrated saffron-associated reduced lipid peroxidation with a concomitant rise in antioxidants (TAC, GSH, GST, and GPX) (Koul and Abraham, 2017). Harchegani et al. (2019) revealed that the administration of high saffron extract concentration (1mg/kg) for eight weeks alleviated the hepatic injury and MDA level with significantly increased TAC level (Harchegani et al., 2019). Giaccio (2004) reported that crocetin in saffron protects against AFB1-related oxidative damage and hepatotoxicity with increased GST levels in rats.

The results of this study depicted a significant reduction in testosterone serum levels in the AFB1-treated group in comparison to the control group, which confirmed the AFB1 toxicity on testes. Testosterone, produced in Leydig cells, is crucial for testicular function and spermatogenesis. Supriya et al. (2014) reported that rat exposure to different AFB1 concentrations (10, 20, or 50 mg/kg) considerably alleviated serum testosterone levels. Thus, AFB1 can disrupt testicular testosterone production, which facilitates sperm development in adult males (Abdel-Aziem et al., 2011; Adedara et al., 2014). Another study has reported enhanced cholesterol levels in AFB1-treated mice testes, which could be due to partially impaired steroidogenesis or partial cholesterol utilization (Verma and Nair, 2002). During the study, testosterone serum level was also significantly reduced in the AFB1+ Saffron group compared to the control group, which indicated that the saffron was unable to protect it from AFB1 toxicity.

The histopathological examinations of the liver, kidneys, and testes revealed several changes in the AFB1-treated group as compared to the normal control group. AFB1-induced hepatic injuries were characterized by amalgamated and hypertrophied hepatocytes with granular vacuolated cytoplasm, deeply stained pyknotic nuclei, and cell necrosis. The central vein and hepatic sinusoids appeared congested, whereas the portal area was dilated by the infiltration of immune and Kupffer cells. Several studies have reported AFB1-associated histopathological alterations in hepatocytes with massive cell necrosis, vacuolar degeneration, sinusoidal endothelium damage, invasion of Disse space with hyperactive immune and Kupffer cells (Ali et al., 2022; Li et al., 2022). Rotimi et al. (2019) also noticed that AFB1 toxicity led to hepatic sinusoid and vesicular (micro and macro) degeneration, proliferation of bile ductules, inflammation of the central vein, and infiltration of inflammatory cells.

The histopathology of the kidneys revealed several AFB1-induced abnormalities, such as glomerular capil-

laries' congestion and atrophy within Bowman's capsule, renal tubules' congestion, bleeding, and capsular wall degeneration, leading to wider spaces between capsule and glomerulus. The epithelial cell lining of the renal tubule appeared swollen with narrow tubular lumen and fine granular cytoplasm, whereas other renal tubules presented blood congestion and damaged walls. Yilmaz et al. (2018) reported AFB1-associated serious kidney damage, including vacuolization, renal cell necrosis, and exfoliation. Popescu et al. (2022) noticed glomerular tufts atrophy and modified Bowman's capsule in AFB1-treated animals. Inflammatory cell aggregation was also noted between tubules and glomeruli, along with the focal congested areas in the medullary region of blood vessels, whereas collagen proliferation mainly occurred at tubular injury sites (Popescu et al., 2022). Li et al. (2011) also demonstrated AFB1 toxicity in mouse kidneys, which involved downstream apoptosis factors (cleaved Caspase-3, Bax, and Bcl-2) and upstream regulator proline dehydrogenase (PRODH).

During the current study, the histological examination of testes displayed severe damage and a complete absence of spermatozoa, spermatogonia, spermatids, primary spermatocytes, and secondary spermatocytes in the AFB1-treated group. Moreover, seminiferous tubules' necrosis and atrophy were characterized by Leydig cell degeneration, deep staining of pyknotic nuclei, and thickened basement membrane. Kudayer et al. (2019) have reported excessive testicular cell vacuolation and spermatogenesis suppression after AFB1 administration for seven days (Kudayer et al., 2019). Another study has reported AFB1-induced necrosis and degeneration of seminiferous tubules' epithelium lining, changes in sperm mitochondria, and outer dense fibre extrusion (Faisal et al., 2008). Multiple studies have reported a significant reduction in testes index (sperm quality and concentration) and changes in spermatozoa production and testicular function after AFB1 treatments (Abu El-Saad and Mahmoud, 2009; Cao et al., 2017). The mechanism of AFB1 cytotoxicity involves either direct toxicity or oxidative stress on biological macromolecules (Towner et al., 2002). Due to the presence of highly enriched polyunsaturated fatty acid, the spermatozoa and testes are prone to oxidative stress. Oxidative stress reduces sperm quality, which is a widely accepted AFB1-toxicity to testes (Abdel-Aziem et al., 2011).

Sakr et al. (2014) described that saffron extract ameliorated sperm count, abnormalities, and testicular destruction caused by valproate treatment (Sakr et al., 2014). Asadi et al. (2014) also reported improved semen parameters (sperm motility, concentration, and viability in cauda epididymis) in cadmium-exposed rats after saffron treatment. Heidary et al. (2008) further elaborated that saffron intake in non-smoking infertile males suffering from oligospermia could enhance the sperms' average number and motility (Heidary et al., 2008). Modaresi et al. (2008) reported that saffron administration (100 mg/kg) for 20 days could elevate the follicle-stimulating hormone, testosterone, and luteinizing hormone levels in mice (Modaresi et al., 2008).

Conclusions

This study establishes the protective impacts of saffron and its bioactive components on blood parameters, liver, kidneys, and testes against AFB1-induced toxicity. Thus, saffron can effectively serve as a natural food additive and novel pharmacological compound for the alleviation of oxidative stress. However, further studies are necessary to evaluate the efficacy of saffron in protecting against toxins and related oxidative stress. Moreover, other beneficial components of saffron should also be investigated to improve toxins-related health issues.

Author Contributions

Research designing, H.A., L.K., K.E., H.H.A.; Conducting experiments, H.A., O.T.A., F.A.-R., S.A., A.A.Ala., G.H.A., A.A.Alo., F.A.A., S.H.A., R.M.W.; Data curation and analysis, L.K., E.A.H., B.R., S.I., T.S.A.; Writing-first draft, H.A., H.H.A.; Writing-final draft and editing, H.H.A., L.A.N. All authors have read and agreed to the published version of the manuscript.

Funding

This work did not receive any funding.

Ethical Approval

The experiment protocol was approved by the Ethical Committee of King Fahd Medical Research Centre, Jeddah, Saudi Arabia (Approval # 163-19). The care and handling of experimental animals were performed according to ARRIVE guidelines for the care and use of laboratory animals.

Conflicts of Interest

The authors declare no conflict of interest.

References

Abdel-Aziem, S.H., Hassan, A.M., Abdel-Wahhab, M.A., 2011. Dietary supplementation with whey protein and ginseng extract counteracts oxidative stress and DNA damage in rats fed an aflatoxin-contaminated diet. Mutation Research/Genetic Toxicology and Environmental Mutagenesis, 723, 65-71. DOI:10.1016/j.mmrgentox.2011.04.007.

Abu El-Saad, A.S., Mahmoud, H.M., 2009. Phytic acid exposure alters aflatoxinB1-induced reproductive and oxidative toxicity in albino rats (*Rattus norvegicus*). Evidence-Based Complementary and Alternative Medicine, 6, 331-341. DOI:10.1093/ecam/nem173.

Adedara, I.A., Nanjappa, M.K., Farombi, E.O., Akingbemi, B.T., 2014. Aflatoxin B1 disrupts the androgen biosynthetic pathway in rat Leydig cells. Food and Chemical Toxicology 65, 252-9. DOI:10.1016/j.fct.2013.12.027.

Ahamad, D.B., Sharma, A., Dwivedi, P., 2015. Aflatoxin B1 induced carcinogenicity in Wistar rats: Clinical signs and growth performance. Shanlax International Journal of Veterinary Science, 3, 2321-6387.

Akhoundzadeh, B.A., Ghoreyshi, S., Nourbala, A., Akhoundzadeh, S., Rezazadeh, S.(2008).Petal and stigma of *Crocus sativus* L.in the treatment of depression: a pilot double-blind randomized trial. Progress in Neuro-Psychopharmacology and Biological Psychiatry 31, 439-442. DOI:10.1016/j.pnpbp.2006.11.010.

Ali, A., Khatoon, A., Almohaimeed, H.M., Al-Sarraj, F., Albiheyri, R., Alotibi, I., Abidin, Z.U., 2022. Mitigative potential of novel *Lactobacillus plantarum* TISTR 2076 against the aflatoxins-associated oxidative stress and histopathological alterations in liver and kidney of broiler chicks during the entire growth period. Toxins, 14, 689. DOI:10.3390/toxin14100689.

Altinoz, E., Oner, Z., Elbe, H., Cigremis, Y., Turkoz, Y., 2015. Protective effects of saffron (its active constituent, crocin) on nephropathy in streptozotocin-induced diabetic rats. Human, Experimental Toxicology, 34, 127-134. DOI:10.1177/0960327114538989.

Asadi, M.H., Zafari, F., Sarveazad, A., Abbasi, M., Safa, M., Koruji, M., Yari, A., Alizadeh Miran, R., 2014. Saffron improves epididymal sperm parameters in rats exposed to cadmium. Nephro-Urology Monthly 6, e12125. DOI:10.5812/numonthly.12125.

Ashi, H., Almalki, M., Hamed, E.A., Makhlouf, M.M.M., Alsulami, F.S., Alharbi, A.S., Alharbi, A.F., Alami, O.T., Alqethami, N., Al-Rahmani, F., Thabit, M.A., Aashi, S., Alzahrani, Y.A., Elbanna, K., Abulreesh, H.H., 2023a. Effect of aflatoxin B1 on the haematology, testes, and lungs of adult male rats: a physiologal and histological study. Animal Science and Genetics 19, 93-114. DOI:https://doi.org/10.5604/01.3001.0053.9337.

Ashi, H., Almalki, M.H., Hamed, E.A., Ramadan, W.S., Alahmadi, T.F., Alami, O.T., Arafa, S.H., Alshareef, A.K., Alsulami, F.S., Alharbi, A.F., Al-Harbi, M.S., Alqurashi, E.H., Aashi, S., Alzahrani, Y.A., Elbanna, K., Abulreesh, H.H., 2023b.Protective and therapeutic effects of lactic acid bacteria against aflatoxin B1 toxicity to rat organs. Microorganisms 11, 1703. DOI:https;//doi.org/10.3390/microorganisms11071703.

Babaei, A., Arshami, J., Haghparast, A., Mesgaran, M.D., 2014. Effects of saffron (*Crocus sativus*) petal ethanolic extract on hematology, antibody response, and spleen histology in rats. Avicenna journal of phytomedicine, 4, 103.

Bertrand, S., Schumpp, O., Bohni, N., Bujard, A., Azzollini, A., Monod, M., Gindro, K., Wolfender, J.L., 2013. Detection of metabolite induction in fungal co-cultures on solid media by high-throughput differential ultra-high pressure liquid chromatography-time-of-flight mass spectrometry fingerprinting. Journal of Chromatography A, 1292, 219-28. DOI:10.1016/j.chroma.2013.01.098.

Bolhassani, A., 2018. Bioactive components of saffron and their pharmacological properties. Studies in Natural Products Chemistry, 58, 289-311. DOI:10.1016/B978-0-444-640056-7.00010-6.

Cao, Z., Shao, B., Xu, F., Liu, Y., Li, Y., Zhu, Y., 2017. Protective effect of selenium on aflatoxin b1-induced testicular toxicity in mice. Biological Trace Elemement Research 180, 233-238. DOI:10.1007/s12011-017-0997-z.

Dai, Y., Huang, K., Zhang, B., Zhu, L., Xu, W., 2017. Aflatoxin B1-induced epigenetic alterations: An overview. Food and Chemical Toxicology 109, 683-689. DOI:10.1016/j.fct.2017.06.034.

Daryoush, M., Yousef, D., 2012. Protective effect of ethanolic extracte of *Crocus sativus* L.[Saffron] stigma against Cisplatin induced hepatotoxicity in rats. Medical Sciences 21, 251-261.

Esmaeili, N., Ebrahimzadeh, H., Abdi, K., Safarian, S., 2011. Determination of some phenolic compounds in *Crocus sativus* L. corms and its antioxidant activities study. Pharmacognosy Magazine, 7, 74. DOI:10.4103/0973-1296.75906.

Faisal, K., Periasamy, V., Sahabudeen, S., Radha, A., Anandhi, R., Akbarsha, M., 2008. Spermatotoxic effect of aflatoxin B1 in rat: extrusion of outer dense fibres and associated axonemal microtubule doublets of sperm flagellum. Reproduction, 135, 303-310. DOI:10.1530/REP--07-0367.

Fakruddin, M., Chowdhury, A., Hossain, M.N., Ahmed, M.M., 2015. Characterization of aflatoxin producing *Aspergillus flavus* from food and feed samples. Springerplus, 4, 159. DOI:10.1186/s40064-015-097-1.

Giaccio, M., 2004. Crocetin from saffron: an active component of an ancient spice. Critical Reviews in Food Science and Nutrition, 44, 155-172. DOI:10.1080/10408690490441433.

Harchegani, A.B., Abolfazl, K., Mahdiyeh Mirnam, N., Kaboutaraki, H.B., Shirvani, H., Shahriary, A., 2019. The hepatoprotective and antioxidative effect of saffron stigma alcoholic extract against vincristine sulfate induced toxicity in rats. Interdisciplinary Toxicology, 12, 186. DOI:10.2478/intox-2019-0023.

Hariri, A.T., Moallem, S.A., Mahmoudi, M., Memar, B., Hosseinzadeh, H., 2010. Sub-acute effects of diazinon on biochemical indices and specific biomarkers in rats: protective effects of crocin and safranal. Food and Chemical Toxicology, 48, 2803-2808. DOI:10.1016/j.fct.2010.07.010.

Heidary, M., Vahhabi, S., Reza Nejadi, J., Delfan, B., Birjandi, M., Kaviani, H., Givrad, S., 2008. Effect of saffron on semen parameters of infertile men.Urology Journal 5, 255-9.

Hosseinzadeh, H., Shariaty, V.M., 2007. Anti-nociceptive effect of safranal, a constituent of *Crocus sativus* (saffron), in mice. Pharmacologyonline, 2, 498-503.

Https://Www.Istockphoto.Com/Vector/Structure-of-Aspergillus-Gm1222027247-358441161.[Accessed 20 Feb., 2024].

Husain, A.S., Thalij, K.M., Dheeb, B.I., 2014. Effects of interaction between Aflatoxins (AFs) and functional materials FM in the hematological, biochemical parameters and enzyme activity in Rats. Egyptian Academic Journal of Biological Sciences, B. Zoology, 6, 17-22.

Iranshahi, M., Khoshangosht, M., Mohammadkhani, Z., Karimi, G., 2011. Protective effects of aqueous and ethanolic extracts of saffron stigma and petal on liver toxicity induced by carbon tetrachloride in mice. Pharmacologyonline, 1, 203-212.

Karaca, A., Yilmaz, S., Kaya, E., Altun, S., 2021. The effect of lycopene on hepatotoxicity of aflatoxin B1 in rats. Archives of Physiology and Biochemistry, 127, 429-436. DOI:10.1080/13813455.2019.1648516.

Karmanov, A.P., Kanarsky, A.V., Kocheva, L.S., Semenov, E.I., Belyy, V.A., 2021. In vitro study of adsorption efficiency of natural lignins towards aflatoxin B2. Reactive and Functional Polymers, 167, 105033. DOI:10.1016/j.reactfunctpolym.2021.105033.

Khaled, M.Q., Thalij, K.M., 2021. Effect of aflatoxin B1 contaminated corn and their products on some physiology parameters in laboratory rats. IOP Conference Series: Earth and Environmental Science, IOP Publishing, 012103.

Kheir Eldin, A.A., Motawi, T.M., Sadik, N.A., 2008. Effect of some natural antioxidants on aflatoxin B1-induced hepatic toxicity. EXCLI Journal, 7, 119-131.

Koul, A., Abraham, S.K., 2017. Intake of saffron reduces γ-radiation-induced genotoxicity and oxidative stress in mice. Toxicology Mechanisms and Methods, 27, 428-434. DOI:10.1080/15375616.2017.1307476.

Kudayer, A.M., Alsandaqchi, A.T., Saleh, F.M., Alwan, N.A., 2019. Toxic effect of aflatoxin B1 on heart, lung, and testis of male albino rats: histopathology study. IOP Conf.Series: Materials Science and Engineering, 571, 012055.

Lahmass, I., El Khoudri, M., Ouahhoud, S., Lahmass, M., Khoulati, A., Benyoussef, S., Mamri, S., Meziane, M., Saalaoui, E., 2021. Biological effects and pharmacological activities of saffron of Crocus sativus. Arabian Journal of Medicinal and Aromatic Plants, 7, 254-68.

Li, M., Kong, Y., Guo, W., Wu, X., Zhang, J., Lai, Y., Kong, Y., Niu, X., Wang, G., 2022. Dietary aflatoxin B1 caused the growth inhibition, and activated oxidative stress and endoplasmic reticulum stress pathway, inducing apoptosis and inflammation in the liver of northern snakehead (*Channa argus*). Science of The Total Environment, 850, 157997. DOI:10.1016/j.scitotenv.2022.157997.

Li, P., Zhang, Q., Zhang, D., Guan, D., Liu, D.X., Fang, S., Wang, X., Zhang, W., 2011. Aflatoxin measurement and analysis. In: Torres-Pacheco I.(Ed.), Aflatoxins-Detection, Measurement and Control.Pp.183-208, IntechOpen, Croatia.

Modaresi, M., Messripour, M, Asadi, M., Marghmaleki,, Hamadanian, M.K., 2008. Effect of saffron [*Crocus sativus*] extract on level of FSH, LH and testosterone in mice. Journal of Zanjan University of Medical Sciences and Health Services, 16, 11-17.

Mahmoudzadeh, L., Najafi, H., Ashtiyani, S.C., Yarijani, Z.M., 2017. Anti-inflammatory and protective effects of saffron extract in ischaemia/reperfusion-induced acute kidney injury. Nephrology, 22, 748-754.

Manchón, N., D'arrigo, M., García-Lafuente, A., Guillamón, E., Villares, A., Ramos, A., Martínez, J., Rostagno, M., 2010. Fast analysis of isoflavones by high-performance liquid chromatography using a column packed with fused-core particles. Talanta, 82, 1986-1994.

Mashmoul, M., Azlan, A., Mohtarrudin, N., Mohd Yusof, B.N., Khaza'ai, H., Khoo, H.E., Farzadnia, M., Boroushaki, M.T., 2016. Protective effects of saffron extract and crocin supplementation on fatty liver tissue of high-fat diet-induced obese rats.BMC Complementary and Alternative Medicine, 16, 401. DOI:10.1186/s112906-016-1381-9.

Mirhadi, E., Nassirli, H., Malaekeh-Nikouei, B., 2020. An updated review on therapeutic effects of nanoparticle-based formulations of saffron components (safranal, crocin, and crocetin). Journal of Pharmaceutical Investigation, 50, 47-58.

Moallem, S.A., Hariri, A.T., Mahmoudi, M., Hosseinzadeh, H., 2014. Effect of aqueous extract of Crocus sativus L.(saffron) stigma against subacute effect of diazinon on specific biomarkers in rats. Toxicology and Industrial Health, 30, 141-146. DOI:10.1177/0748233712452609.

Mtimet, N., Walke, M., Baker, D., Lindahl, J., Hartmann, M., Grace, D., 2015. Kenyan awareness of aflatoxin: An analysis of processed milk consumers. International Conference of Agricultural Economists, Milan, Italy.

Nielsen, K.F., Smedsgaard, J., 2003. Fungal metabolite screening: database of 474 mycotoxins and fungal metabolites for dereplication by standardised liquid chromatography-UV-mass spectrometry methodology. Journal of Chromatography A, 1002, 111-36.

Noorbala, A., Akhondzadeh, S., Tahmacebi-Pour, N., Jamshidi, A., 2005. Hydro-alcoholic extract of *Crocus sativus* L.versus fluoxetine in the treatment of mild to moderate depression: a double-blind, randomized pilot trial. Journal of Ethnopharmacology, 97, 281-284.

Omidi, A., Riahinia, N., Torbati, M.B.M., Behdani, M.-A., 2014. Hepatoprotective effect of *Crocus sativus* (saffron) petals extract against acetaminophen toxicity in male Wistar rats. Avicenna Journal of Phytomedicine, 4, 330.

Owumi, S.E., Danso, O.F., Effiong, M.E., 2019. Dietary quercetin abrogates hepatorenal oxidative damage associated with dichloromethane exposure in rats. Acta Biochimica Polonica, 66, 201-206. DOI:10.18388/abp.2018_2771.

Pan, T.L., Wu, T.H., Wang, P.W., Leu, Y.L., Sintupisut, N., Huang, C.H., Chang, F.R., Wu, Y.C., 2013. Functional proteomics reveals the protective effects of saffron ethanolic extract on hepatic ischemia-reperfusion injury. Proteomics, 13, 2297-2311.

Pandita, D., 2021. Saffron (*Crocus sativus* L.): Phytochemistry, therapeutic significance and omics-based biology. In: Aftab T., Hakeem K.R.(Eds.), Medicinal and Aromatic Plants. Pp.325-369. Academic Press, USA. DOI:10.1016/B978-0-12-819590-1.00014-8.

Parasuraman, S., Raveendran, R., Kesavan, R., 2010. Blood sample collection in small laboratory animals. Journal of Pharmacology, Pharmacotheraputics, 1, 87-93. DOI:10.4103/0976-500X.72350.

Popescu, R.G., Rădulescu, A.L., Georgescu, S.E., Dinischiotu, A., 2022. Aflatoxins in feed: types, metabolism, health consequences in swine and mitigation strategies. Toxins, 14, 853. DOI:10.3390/toxins14120853.

Ramamurthy, V., Rajakumar, R., 2016. Studies on ethanolic leaf extract of phyllanthus niruri and its effect on aflatoxin intoxicated male albino rats. International Journal of Zoology and Applied Biosciences, 1, 1-6.

Rezaee, R., Hosseinzadeh, H., 2013. Safranal: from an aromatic natural product to a rewarding pharmacological agent. Iranian Journal of Basic Medical Sciences, 16, 12.

Rotimi, O.A., Rotimi, S.O., Goodrich, J.M., Adelani, I.B., Agbonihale, E., Talabi, G., 2019. Time-course effects of acute aflatoxin B1 exposure on hepatic mitochondrial lipids and oxidative stress in rats. Frontiers in Pharmacology, 10, 467. DOI:10.3389/fphar.2019.00467.

Rushing, B.R., Selim, M.I., 2019. Aflatoxin B1: A review on metabolism, toxicity, occurrence in food, occupational exposure, and detoxification methods. Food and Chemical Toxicology, 124, 81-100. DOI:10.1016/j.fct.2018.11.047.

Saito, M., Machida, S., 1999. A rapid identification method for aflatoxin-producing strains of *Aspergillus flavus* and *A.parasiticus* by ammonia vapor. Mycoscience, 40, 205-208.

Sakr, S.A., Zowail, M.E., Marzouk, A.M., 2014. Effect of saffron (*Crocus sativus* L.) on sodium valporate induced cytogenetic and testicular alterations in albino rats. Anatomy and Cell Biology, 47, 171-9. DOI:10.5115/acb.2014.47.3.171.

Saldan, N.C., Almeida, R.T.R., Avíncola, A., Porto, C., Galuch, M.B., Magon, T.F.S., Pilau, E.J., Svidzinski, T.I.E., Oliveira, C.C., 2018. Development of an analytical method for identification of *Aspergillus flavus* based on chemical markers using HPLC-MS. Food Chemistry, 241, 113-121. DOI:10.1016/j.foodchem.2017.08.065.

Shabeer, S., Asad, S., Jamal, A., Ali A., 2022. Aflatoxin contamination, its impact and management strategies: an update review. Toxins, 14, 307. DOI:10.3390/toxins14050307.

Shati, A.A., Alamri, S.A., 2010. Role of saffron (*Crocus sativus* L.) and honey syrup on aluminum-induced hepatotoxicity. Saudi Medical Journal, 31, 1106-1113.

Sreekanth, C.N., Bava, S.V., Sreekumar, E., Anto, R.J., 2011. Molecular evidences for the chemosensitizing efficacy of liposomal curcumin in paclitaxel chemotherapy in mouse models of cervical cancer. Oncogene, 30, 3139-52. DOI:10.1038/onc.2011.23. DOI:10.1016/B978-0-12-818462-2.0001-2.

Supriya, C., Girish, B., Reddy, P.S., 2014. Aflatoxin B1-induced reproductive toxicity in male rats: possible mechanism of action. International Journal of Toxicology, 33, 155-161.

Thomson, M., Bou-Abbas, F., Alansary, A., Al-Qattan, K.K., Ali, M., 2009. Effect of saffron on levels of blood lipids in rats fed a high cholesterol diet. The FASEB Journal, 23, 901.4-901.4.

Towner, R.A., Mason, R.P., Reinke, L.A., 2002. In vivo detection of aflatoxin-induced lipid free radicals in rat bile. Biochimca et Biophysica Acta, 1573, 55-62.

Türk, G., Sönmez, M., Aydin, M., Yüce, A., Gür, S., Yüksel, M., Aksu, E.H., Aksoy, H., 2008. Effects of pomegranate juice consumption on sperm quality, spermatogenic cell density, antioxidant activity and testosterone level in male rats. Clinical Nutrition, 27, 289-96. DOI:10.1016/j.clnu.2007.12.006.

Verma, R., Nair, A., 2002. Effect of aflatoxins on testicular steroidogenesis and amelioration by vitamin E. Food and Chemical Toxicology, 40, 669-672.

Wang, D., Lindemann, M.D., Estienne, M.J.,2020. Effect of folic acid supplementation and dietary protein level on growth performance, serum chemistry and immune response in weanling piglets fed differing concentrations of aflatoxin. Toxins, 12, 651. DOI:10.3390/toxins12100651.

Yarijani, Z.M., Pourmotabbed, A., Pourmotabbed, T., Najafi, H., 2017. Crocin has anti-inflammatory and protective effects in ischemia-reperfusion induced renal injuries. Iranian Journal of Basic Medical Sciences, 20, 753.

Yilmaz, S., Kaya, E., Karaca, A., Karatas, O., 2018. Aflatoxin B1 induced renal and cardiac damage in rats: protective effect of lycopene. Research in Veterinary Science, 119, 268-275.

Yuan, G., Dai, S., Yin, Z., Lu, H., Jia, R., Xu, J., Song, X., Li, L., Shu, Y., Zhao, X., 2014. Toxicological assessment of combined lead and cadmium: acute and sub-chronic toxicity study in rats. Food and Chemical Toxicology, 65, 260-268. DOI:10.106/j.fct.2013.12.041.