Wiley
Andrologia
Volume 2026, Article ID 6620108, 17 pages
https://doi.org/10.1155/and/6620108

Research Article

Safeguarding Spermatogenesis: *Garcinia kola* Extract and Kolaviron Effectively Ameliorate Testicular Toxicity in Rats Treated With Bleomycin, Etoposide, and Cisplatin Combination Therapy

O. A. Ayedogba,[1] **O. E. Olorundare**,[1] **A. A. Adeneye**,[2] **A. M. Ajayi**,[3] **Y. C. F. Teles**,[4,5] **and A. A. Fatokun**[5]

[1]*Department of Pharmacology and Therapeutics, Faculty of Basic Clinical Sciences, College of Health Sciences, University of Ilorin, Ilorin, Kwara State, Nigeria*
[2]*Department of Pharmacology, Therapeutics and Toxicology, Faculty of Basic Clinical Sciences, Lagos State University College of Medicine, 1-5 Oba Akinjobi Way, G.R.A., Ikeja, Lagos State, Nigeria*
[3]*Department of Pharmacology and Therapeutics, Faculty of Basic Medical Sciences, University of Ibadan, Ibadan, Oyo State, Nigeria*
[4]*Department of Chemistry and Physics, Center of Agrarian Sciences, Federal University of Paraiba, Areia, PB58397-000, Brazil*
[5]*Centre for Natural Products Discovery (CNPD), School of Pharmacy and Biomolecular Sciences, Liverpool John Moores University, Byrom Street, Liverpool L3 3AF, UK*

Correspondence should be addressed to O. E. Olorundare; olufunke@unilorin.edu.ng and A. A. Fatokun; a.a.fatokun@ljmu.ac.uk

Received 22 September 2024; Revised 29 June 2025; Accepted 20 August 2025

Academic Editor: Sunny Okechukwu Abarikwu

Copyright © 2026 O. A. Ayedogba et al. Andrologia published by John Wiley & Sons Ltd. This is an open access article under the terms of the Creative Commons Attribution License, which permits use, distribution and reproduction in any medium, provided the original work is properly cited.

Background: Emerging evidence indicates that certain chemotherapeutic agents, particularly the bleomycin, etoposide, and cisplatin (BEP) regimen, exert deleterious effects on male reproductive function, including impaired spermatogenesis. Previous studies have demonstrated that *Garcinia kola* (GK) seed extract and its bioactive biflavonoid constituent, kolaviron (KV), exhibit beneficial properties in reproductive physiology. However, their potential protective effects against BEP-induced testicular toxicity remain underexplored. This study evaluated the chemopreventive efficacy of GK extract (GKE) and KV in attenuating BEP-mediated testicular damage in a preclinical rodent model.
Methods: Adult male Wistar rats ($n = 8$ per group) were subjected to three 21-day cycles of BEP chemotherapy (0.5 mg/kg bleomycin, 5 mg/kg etoposide, and 1 mg/kg cisplatin, administered intraperitoneally). Concurrently, treatment groups received oral supplementation with GKE (100 mg/kg), KV (100 mg/kg), silymarin (SLM; 10 mg/kg), or prednisolone (PRED; 5 mg/kg), with dosages determined via prior dose–response optimization. Post-treatment assessments included: sperm functional analysis (count, motility, morphology), serum reproductive hormone profiling [testosterone (TST), luteinizing hormone (LH), follicle stimulating hormone (FSH)], oxidative stress markers [glutathione (GSH), catalase (CAT), superoxide dismutase (SOD), glutathione-S-transferase (GST)], lipid peroxidation indicators [malondialdehyde (MDA), nitric oxide (NO)], inflammatory cytokines (TNF-α, IL-6), and apoptotic markers [caspase-3 (CAS-3) and caspase-9 (CAS-9)].
Results: BEP administration significantly impaired spermatogenic output, which was ameliorated by GKE, KV, SLM, and PRED co-treatment. Notably, TST levels remained stable in GKE- and KV-supplemented groups. All test compounds enhanced antioxidant capacity, suppressing lipid peroxidation (reduced MDA and NO). Furthermore, GKE and KV significantly attenuated BEP-induced elevations in pro-inflammatory cytokines (TNF-α, IL-6) and apoptotic mediators (CAS-3, CAS-9).
Conclusion: GKE and KV conferred substantial protection against BEP-induced testicular toxicity, primarily through mechanisms involving oxidative stress mitigation, anti-inflammatory action, and apoptosis suppression. Their efficacy paralleled that of established agents (SLM, PRED), suggesting potential utility as adjunctive therapies to preserve male fertility during chemotherapy. These findings warrant further clinical investigation to assess translational applicability.

Keywords: anticancer; bleomycin–etoposide–cisplatin combination therapy; *Garcinia kola*; gonadotoxicity; kolaviron biflavonoid complex; prednisolone; silymarin

1. Introduction

Cancer remains a preeminent global health challenge necessitating proactive therapeutic strategies. Among male reproductive malignancies, testicular germ cell tumors (TGCTs) represent the predominant neoplastic pathology, accounting for ~90%–95% of testicular cancers (TCs) [1]. Epidemiologic data reveal a concerning rise in cancer incidence among adolescents and young adults (15–40 years), with TC constituting the most prevalent solid tumor in this demographic [2–6]. Advances in multimodal therapies, including radiotherapy, radical orchiectomy, and cisplatin-based chemotherapy, have dramatically improved survival rates, with contemporary regimens achieving cure rates exceeding 95% [3, 6–8]. However, a critical clinical dilemma persists: many anticancer agents, particularly alkylating agents and platinum derivatives, exert gonadotoxic effects that compromise spermatogenesis and male fertility [9, 10].

The bleomycin, etoposide, and cisplatin (BEP) regimen is the cornerstone of TGCT treatment, achieving 5-year survival rates >95% across disease stages [9, 10]. Despite its efficacy, BEP chemotherapy induces multisystem toxicity, with the testes being particularly vulnerable due to the high mitotic activity of germ cells [11–13]. The triad of BEP agents synergistically disrupts testicular homeostasis through distinct yet complementary mechanisms: bleomycin generates DNA strand breaks via oxidative radical formation, precipitating germ cell apoptosis, seminiferous tubule atrophy, and Leydig cell dysfunction [14]; etoposide inhibits topoisomerase II, causing irreversible DNA double-strand breaks and cell cycle arrest in rapidly dividing spermatogonia [15]; and cisplatin forms DNA crosslinks and generates reactive oxygen species (ROS), inducing oxidative damage to Sertoli cells, spermatogonial stem cells (SSCs), and Leydig cells [16]. Cumulatively, these insults lead to spermatogenic arrest, oligospermia/azoospermia, and hypogonadism, with recovery contingent on SSC preservation [17–22]. Preclinical studies corroborate BEP-induced deficits in sperm motility, chromatin integrity, and flagellar function, underscoring the urgency for fertility-preserving adjuvants [23–28].

Emerging evidence provides the protective role of *Garcinia kola* (GK) seeds and its biflavanones extract kolaviron (KV) from drug-induced organ toxicities by ameliorating oxidative stress, inflammation [29–38] and apoptosis [39–41]. *Garcinia kola* (*G. kola*) (popularly known as bitter kola) is a dicotyledonous plant belonging to the family, *Guttiferae*. It is a perennial crop found distributed in the forest zone of Nigeria, Sierra Leone, Ghana, Cameroon and other West and Central African countries [42]. In Nigeria, it is common in the South Western States and Edo State [43]. It is commonly called "Orogbo" in Yoruba language, "Aku ilu" in Igbo language and "Namijin goro" in Hausa language [43]. One of the most studied and discussed components in GK seeds is the KV biflavonoid complex. This complex further consists of biflavanones GB1, GB2, and kolaflavanone [44–46]. The mitigating effect of these biflavanones in addition to ameliorating oxidative stress and apoptosis, also involve the downregulation of pro-inflammatory cytokines (e.g., TNF-α, IL-6) [47–52] and these mechanisms have been indicted in BEP-induced toxicities [17].

Similarly, *Silybum marianum* L. (milk thistle) (family: Asteraceae), a flavonolignan complex, exerts hepatoprotective and gonadal protective effects by modulating NF-κB and Nrf2 pathways and attenuating cisplatin-induced oxidative damage [53–55]. Silymarin (SLM) is the active component of this herb, which is a complex of other components, mainly silybin A, silybin B, isosilybin A, isosilybin B and also other flavonolignants such as silychristin, neosilyhermin, silyhermin, and silydianin, which exist in its fruit and seeds more than the other parts [56]. Prednisolone (PRED), a synthetic glucocorticoid, demonstrates anti-inflammatory and antioxidant properties in drug-induced organ toxicity models [57–59].

Despite documented benefits of GK extracts (GKE), KV, SLM, and PRED in other toxicity models, their efficacy against BEP-induced testicular damage remains unexplored. Therefore, this study evaluated the possible ameliorative potentials of GKE and its biflavanone extract, KV, in BEP-induced testicular toxicities in adult male Wistar rats. In addition, we evaluated the beneficial/mitigative potentials of SLM and PRED being the standard antioxidant and anti-inflammatory drugs used, respectively, on BEP-induced testicular toxicities in rats, by assessing reproductive hormones, testicular functions, oxidative stress, pro-inflammatory cytokines, and apoptosis markers in testis of rats exposed to BEP.

2. Materials and Methods

2.1. Material

2.1.1. Chemicals and Drugs. The following compounds were procured for this study: bleomycin (Metta Life Sciences Pvt Ltd G-040, Vikas Centre, 106 S.V. Road, Santacruz West, 400 054, India), cisplatin (Zuvius Lifesciences Pvt Ltd. B/108, 109 & 111, Kanara Business Centre, Link Road, Ghatkopar (East), Mumbai - 400075 India), etoposide (Zuvius Lifesciences Pvt Ltd, India), dimethyl sulphoxide (DMSO) (Sigma-Aldrich Corporation, St. Louis, MO, USA), methanol, petroleum ether, ethyl acetate, n-hexane (Sigma-Aldrich Corporation, St. Louis, MO, USA), the enzymes linked immunosorbent assay (ELISA) kits (ELABSCIENCE, Wuhan Elabscience Biotechnology Company Limited, No. 1 Shizishan Street, Hongshan District, Wuhan, Hubei, China), SLM (Silybon, Micro Labs Ltd. 27, Race Course Road., Bangalore, Karnataka, India - 560001), and PRED (Perilon, Hovid Bhd. 121, Jalan Tunku Abdul Rahman, 30010 Ipoh, Malaysia).

2.1.2. Plant Material. Fresh GK nuts were procured from Mushin Market, Lagos, Nigeria. Taxonomic authentication

was performed by a well-trained and certified botanist in the Department of Plant Biology, University of Ilorin, where a voucher specimen (UILH/001/1217/2023) was deposited in the departmental herbarium.

2.1.3. Extraction of the Methanol Crude Extracts of Gk and KV. The air-dried seeds of GK were pulverized and defatted with petroleum ether for 48 h and then macerated with methanol for 72 h and afterwards filtered. Thereafter, the filtrates were concentrated using a rotary vacuum evaporator at concentrated in a vacuum oven at temperature of 40°C and pressure of 600 mm Hg to obtain extracts of GK seeds. The methanolic extract GK seeds was further dissolved with water (H_2O) to produce a chalky solution. This solution was further partitioned with ethyl acetate and concentration to give a golden-brown substance, KV, which has been shown to be rich in Garcia biflavones GB-1, GB-2, and kolaflavanone [43, 60–62] as previously reported [63]. The GKE and KV were air-dried and stored in a refrigerator at 4°C. GKE and KV were dissolved separately in DMSO and then diluted with distilled water to reduce the DMSO concentration to 2% in the final suspension.

2.1.4. Phytochemical Analysis. Liquid chromatography coupled to mass spectrometry (LC/MS) was used to confirm the presence of the biflavones GB-1, GB-2, and kolaflavanone in KV (Figure 1).

The analysis was performed using the instrument HIRESESI-MS Agilent with OpenLab CDS Software. The solvents used were LC/MS grade methanol (MeOH) and Ultrapure water (18.2 M-cm). The sample was prepared in a concentration of 5 mg/mL in MeOH. The flow rate was 0.8 mL/min and the injection volume was 10 μL. The column used was a Phenomenex Gemini (C18, 5 μm, 4.6 × 150 mm).

The method consisted in a gradient using acidified water as solvent A (0.1% of formic acid) and acidified MeOH (0.1% of formic acid) as solvent B. The gradient started from 20% of B up to 100% of B in 30 min, followed by 7 min of 100% of B to flush the column. To obtain the mass of the compounds in the sample, the QTOF MS was run in negative mode, full scan, with collision energy set up as zero.

In the retention time (Rt) of 16.55 min a peak was found showing mass of 573.1010 for its molecular ion, and at Rt of 16.85 min another peak with molecular mass of 573.1008 suggested the presence of the compounds GB1 and GB2, respectively. They were confirmed by comparison to the internal metabolites library PCDL Agilent METLIN Metabolomics database (Figure 1A–C). At Rt of 18.80 min another peak showed mass of 587.1168 for its molecular ion $(M\text{-}H)^-$ attributed to Kolaflavanone, also confirmed by comparison to PCDL Agilent METLIN Metabolomics database (Figure 1D).

2.1.5. Care and Use of Experimental Animals. A cohort of 64 young adult male Wistar rats (mean body weight: 150–160 g) was procured from a certified breeder in Ogbomosho, Oyo State, Nigeria. Following acquisition, the animals were acclimatized for 7 days under controlled laboratory conditions, housed in standard polypropylene cages at an ambient temperature of 28–30°C with a 12-h light/dark cycle. The rats were provided ad libitum access to a standard commercial pellet diet (Chikun Feeds Limited, Ibadan, Nigeria) and filtered water. All experimental procedures strictly adhered to the National Institutes of Health (NIH) Guidelines for the Care and Use of Laboratory Animals [64] and were approved by the University of Ilorin Ethical Review Committee (Approval No. UERC/ASN/2024/2769).

2.1.6. Treatment Protocol: BEP, GKE, KV, SLM, and PRED. To ensure optimal pharmacokinetic exposure, rats received daily pretreatment for 7 days with either vehicle, GKE, KV, SLM, or PRED prior to BEP chemotherapy initiation (Table 1). This pretreatment phase facilitates the attainment of steady-state plasma concentrations, thereby maximizing the protective efficacy of the test compounds against subsequent BEP-induced toxicity [65]. The therapeutic agents were administered continuously throughout the BEP treatment period, with each dose given 1 h before BEP injection.

This treatment regimen was continued throughout the entire duration of the BEP treatment. Each specific treatment was administered 1 h prior to the intraperitoneal injection of BEP. The BEP therapy regimen spanned over a 9-week period, during which bleomycin was administered on days 2, 9, and 16, while etoposide and cisplatin were administered on days 1–5 of each 21-day cycle [5, 23, 66, 67]. The entire treatment plan consisted of three cycles of BEP treatment, with 1 week of treatment with either vehicle, or GKE, or KV, or SLM or PRED preceding the initiation of BEP, resulting in a total duration of 10 weeks. This treatment protocol is consistent with internationally accepted the standard clinical protocol for the chemotherapeutic management of TC patients with BEP [68].

2.2. Assessment of Effects of GKE, KV, SLM, PRED on BPE-Induced Testicular Toxicity

2.2.1. Gross Assessment of the Testes. Three to five replicate rats per objective point and treatment group were selected. Body weight was measured weekly and on the day of necropsy. Rats were anesthetized with ketamine and xylazine (70:30), and blood was collected directly from the heart chambers by cardiac puncture. The rats were then sacrificed, and the rats' testes were carefully identified, freed from adjoining supporting tissues, harvested en bloc, and weighed. A portion of the testis was excised for biochemical assays and fixation for histological examinations. The caudal epididymis was harvested for semen analysis.

Testicular-somatic index (TSI) was determined as follows:

$$\text{Testicular-somatic index (TSI) (\%)} = [\text{Testicular weight(g)}/\text{Final body weight(g)}] \times 100. \text{ [66].}$$

2.2.2. Determination of Serum Luteinizing Hormone (LH), Follicle Stimulating Hormone (FSH), and Testosterone (TST) Levels. Blood samples were collected in plain bottles, centrifuged at 3600 rpm for 15 min to separate out clear sera. Sera obtained were analyzed for reproductive hormones (LH, FSH, and TST) using rat-specific ELISA kits (Wuhan Elabscience Biotechnology Company Limited, No. 1 Shizishan Street, Hongshan District, Wuhan, Hubei, China). The kit standards and samples (50 μml) were added to the wells precoated with specific antibodies in a 96-well plate, and the

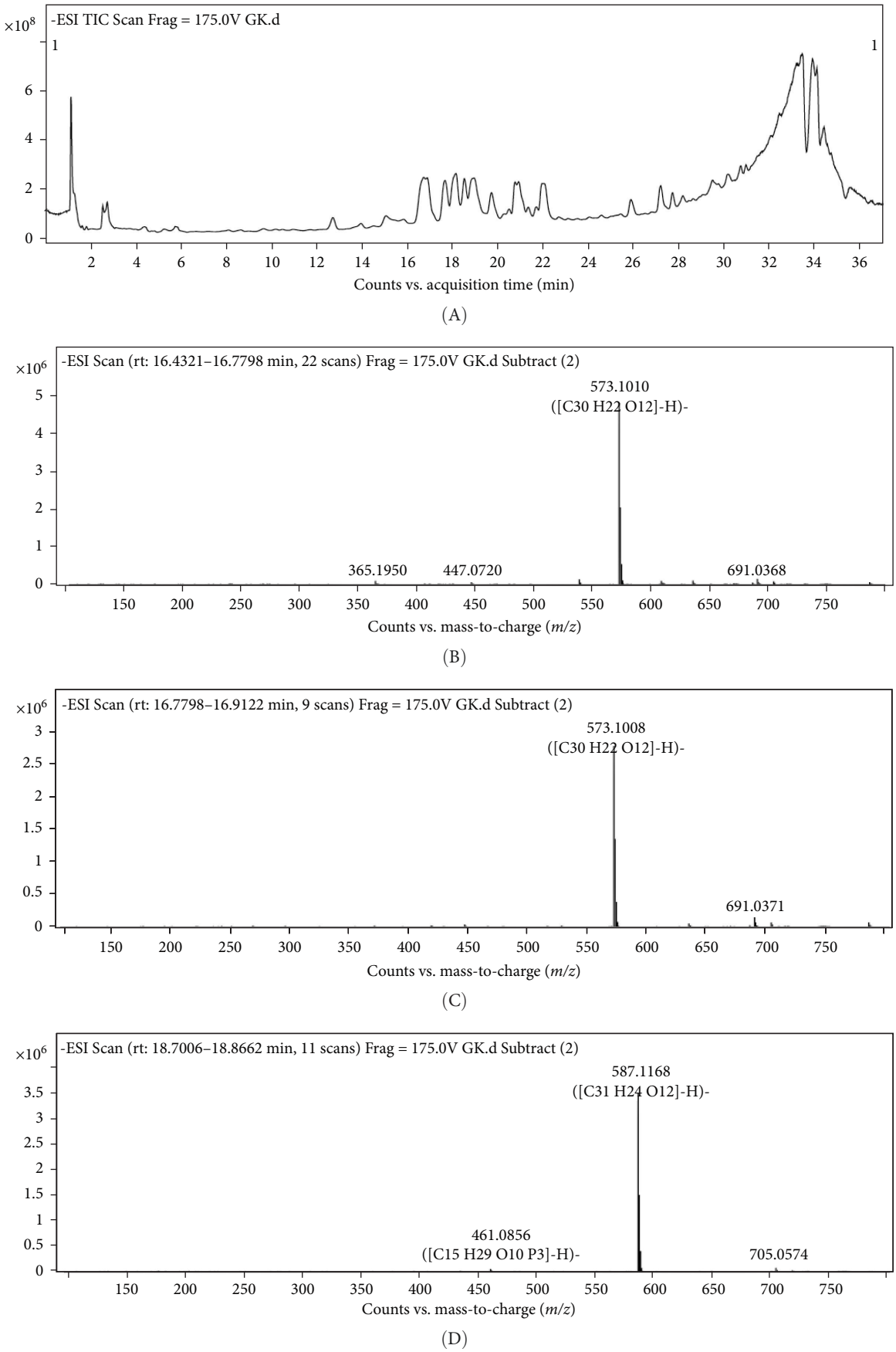

Figure 1: LC/MS results showing the presence of biflavonoid compounds in KV. (A) Full ESI TIC chromatogram of KV; (B) mass spectrum of GB1 [ion (m/z) exp. = 573.1010 $(M\text{-}H)^-$]; (C) mass spectrum of GB2 [ion (m/z) exp. = 573.1008 $(M\text{-}H)^-$]; (D) mass spectrum of Kolaflavanone [ion (m/z) exp. = 587.1168 $(M\text{-}H)^-$].

Table 1: Treatment protocol.

Groups	Treatments
Group I	10 mL/kg of 2% DMSO given p.o. daily for 10 weeks
Group II	BEP cocktail. [The animals received i.p. doses of cisplatin (1 mg/kg) and etoposide (5 mg/kg) on days 1–5 of each of the 21 days cycle while bleomycin (0.5 mg/kg) was administered on days 2, 9, and 16].
Group III	100 mg/kg GKE given p.o. daily for 10 weeks
Group IV	100 mg/kg KV given p.o. daily for 10 weeks
Group V	100 mg/kg GKE + BEP cocktail. [Same as Group II]. While GKE was administered p.o. 7 days prior to BEP initiation and throughout the 9 weeks of BEP.
Group VI	100 mg/kg KV + BEP cocktail [Same as Group II]. While KV was administered p.o. 7 days prior to BEP initiation and throughout the 9 weeks of BEP.
Group VII	10 mg/kg silymarin + BEP cocktail [Same as Group II]. While silymarin was administered p.o. 7 days prior to BEP initiation and throughout the 9 weeks of BEP.
Group VIII	5 mg/kg Prednisolone + BEP cocktail [Same as Group II]. While prednisolone was administered p.o. 7 days prior to BEP initiation and throughout the 9 weeks of BEP.

Note: Table shows the treatment schedule: Rats received daily pretreatment with vehicle, GKE, KV, SLM, or PRED for 7 days before initiating BEP chemotherapy to ensure steady-state drug levels. All treatments continued throughout the 9-week BEP regimen (three 21-day cycles: bleomycin on days 2, 9, 16; etoposide and cisplatin on days 1–5). Test compounds were administered 1 h before each BEP dose. This protocol reflects standard clinical practice for TC [5, 23, 65–68]. BEP was administered intraperitoneally (i.p.) while the other administrations were through the oral route, and ($n = 8$).
Abbreviations: BEP, bleomycin, etoposide, and cisplatin; GKE, *Garcinia kola* extract; i.p., intraperitoneal; KV, kolaviron; *p.o.*, per oral; PRED, prednisolone; SLM, silymarin.

assay was conducted according to the manufacturer's instructions contained in the enclosed leaflets. The results were calculated by plotting the optical density (OD) into a four-parametric logistic curve. The product and catalog numbers for LH (Diasino) are DS177709 and DS1777092012V4, respectively while that for FSH (Diasino) and TST (Diasino) are DS177710 and DS1777101909V3, and DS177714 and DS1777142110V2, respectively.

2.2.3. Determination of the Testicular Tissue Antioxidant Activities. The enzymatic activities of superoxide dismutase (SOD), catalase (CAT), and glutathione-S-transferase (GST), along with the concentrations of reduced glutathione (GSH) and malondialdehyde (MDA), were quantified in testicular tissue following the methodology outlined by Buege and Aust [67]. SOD activity was determined based on its capacity to inhibit the autoxidation of adrenaline. Absorbance was measured spectrophotometrically at 492 nm, and enzyme activity was expressed in units per milligram of protein (U/mg protein). CAT activity was evaluated by monitoring the enzymatic decomposition of hydrogen peroxide (H_2O_2). The reaction kinetics were assessed spectrophotometrically at 405 nm, with results reported as U/mg protein. Reduced GSH levels were determined via its reaction with 5,5′-dithiobis-2-nitrobenzoic acid (DTNB, Ellman's reagent), yielding 5-thio-2-nitrobenzoic acid (TNB), which was measured at 405 nm. Thiobarbituric acid-reactive substances (TBARS) were quantified as an index of lipid peroxidation. Testicular homogenates were incubated with TBA at 80°C for 45 min, and absorbance was recorded at 532 nm. MDA concentrations were calculated using a molar extinction coefficient of $1.56 \times 10^5\ M^{-1}\,cm^{-1}$ and expressed as nmol MDA per mg protein. GST activity was assessed spectrophotometrically (Labtech LT-4500 microplate reader, France) by measuring the conjugation rate of GSH to 1-chloro-2,4-dinitrobenzene (CDNB). Testicular homogenates (60 μL) were incubated with the reaction mixture, and absorbance was monitored at 340 nm for 5 min. Enzyme activity was calculated in μmol CDNB conjugated per minute per well (μmol/min/well) using an extinction coefficient (ε) of $9.6\,mM^{-1}\,cm^{-1}$.

Testicular nitric oxide (NO) levels were estimated via the Griess reaction. Tissue supernatants were incubated with Griess reagent (1% sulfanilamide and 0.1% N-(1-naphthyl) ethylenediamine dihydrochloride) for 10 min at room temperature (protected from light). Absorbance was measured at 540 nm, and nitrite (NO_2^-) concentrations were extrapolated from a sodium nitrite ($NaNO_2$) standard curve, expressed as μM per mg protein.

2.2.4. Quantification of Testicular Tissue Pro-Inflammatory Cytokines (TNF-α and IL-6). Testicular levels of tumor necrosis factor-alpha (TNF-α) and interleukin-6 (IL-6) were quantified using commercial enzyme-linked immunosorbent assay (ELISA) kits (Wuhan Elabscience Biotechnology Co., Ltd., China), following the manufacturer's protocols.

For the TNF-α assay, the human TNF-α ELISA kit (Catalog No. E-EL-H0109) was employed, with absorbance readings correlated against a standard curve generated using recombinant TNF-α, while for the IL-6 assay, the human IL-6 ELISA kit (Catalog No. E-EL-H6156) was used, with cytokine concentrations derived from a parallel IL-6 standard curve. All assays were performed in triplicate, and data were normalized to total protein content.

2.2.5. Quantitative Assessment of Testicular Tissue Caspase-3 (CAS-3) and Caspase-9 (CAS-9). The testicular tissue concentrations of CAS-3 and CAS-9, pivotal biomarkers of apoptosis, were quantitatively analyzed in homogenized testicular tissues using enzyme-linked immunosorbent assay (ELISA) kits (Wuhan Elabscience Biotechnology Co., Ltd.; Catalog Nos. E-EL-R0160 for CAS-3 and E-EL-R0163 for CAS-9, specific for rat antigens).

Table 2: Body weight and testicular weight.

Drug treatment	Initial body weight (g)	Final body weight (g)	Difference in body weight (DBW) (g)	Percentage weight gain/loss (PW) (%)	Testicular weight (g)	Testicular-somatic index (TSI) (%)
Control	173.2	226.8	53.6	31.0.	2.1	0.9
BEP	230.9	227.8	−3.1	−1.4	1.2	0.5
GKE	230.7	291.0	60.3	26.1	2.8	1.0
KV	212.6	253.5	40.9	19.2	2.7	1.1
GKE + BEP	233.7	252.8	19.1	8.2	1.4	0.6
KV + BEP	218.2	237.2	19.0	8.7	1.3	0.5
SLM + BEP	219.8	240.0	20.2	9.2	1.5	0.6
PRED + BEP	225.9	207.3	−18.6	−8.2	1.3	0.6

Note: BEP treatment led to body weight loss (−3.1 g; −1.4% PW; TSI = 0.5%) versus control gains (53.6 g; 31.0% PW; TSI = 0.9%). GKE and KV alone increased weight and TSI (GKE: 60.3 g; 26.2%; 1.0%; KV: 40.9 g; 19.2%; 1.1%). Co-treatment with GKE, KV, or SLM partially reversed BEP effects (19.0–20.2 g gain; 8.2–9.2% PW; TSI = 0.5%–0.6%), while PRED + BEP caused further loss (−18.6 g; −8.2%; TSI = 0.6%). Values are given as mean and percentage for groups of eight rats each.
Abbreviations: BEP, bleomycin, etoposide, cisplatin; GKE, *Garcinia kola* extract; KV, kolaviron; PRED, prednisolone; SLM, silymarin.

The assay was performed in strict adherence to the manufacturer's protocol. Briefly, testicular homogenates and prediluted standards were dispensed into micro-ELISA plates precoated with rat-specific monoclonal antibodies against CAS-3 or CAS-9. Subsequently, a biotinylated secondary antibody, followed by an avidin-horseradish peroxidase (HRP) conjugate, was added to each well and incubated. Following a series of washes to remove unbound reagents, a chromogenic substrate solution was introduced, inducing an enzymatic colorimetric reaction proportional to the target caspase concentration. The reaction was terminated using a stop solution, and the OD of each well was measured spectrophotometrically at 450 nm. The absolute concentrations of CAS-3 and CAS-9 in testicular samples were extrapolated from a standard curve generated using known reference concentrations.

2.3. Semen Analysis. Sperm analysis was conducted to evaluate sperm viability, motility, morphology, and count. The cauda epididymis was carefully excised, cleared of adipose tissue, and finely minced in phosphate-buffered saline (1 mmol/L KH_2PO_4, 10 mmol/L Na_2HPO_4, 137 mmol/L NaCl, 2.7 mmol/L KCl, and pH 7.0) to release spermatozoa. Sperm motility was assessed by categorizing sperm as progressive, nonprogressive, or immotile within a single microscopic field. Results were expressed as the percentage of progressive sperm motility [69]. Sperm counts were determined using a hemocytometer and reported as millions per milliliter of suspension while the sperm viability was evaluated via eosin–nigrosin staining. Briefly, sperm smears were prepared on glass slides, stained with eosin–nigrosin solution, and examined microscopically to differentiate viable (unstained) from nonviable (stained) spermatozoa [69, 70]. Sperm morphological integrity was determined using aniline blue staining. Sperm smears were fixed, stained with a solution containing 0.2% eosin and 0.6% fast green in a 2:1 ethanol-distilled water mixture (2:1 ratio), air-dried, and analyzed under a light microscope for abnormalities [71].

2.4. Histopathological Evaluation of Testicular Tissues. For histopathological examination, testicular tissue samples from treated rats were meticulously processed. First, they were fixed in 10% phosphate-buffered formalin (pH = 7.0) to preserve cellular architecture. Following fixation, the tissues were embedded in paraffin to facilitate sectioning. Subsequently, thin sections were prepared and stained with two crucial histological stains: Periodic acid-Schiff-hematoxylin (PAS-H) staining is often used for testicular tissue histopathological examination to visualize and analyze structures rich in carbohydrates, particularly glycoproteins and polysaccharides. This is crucial for assessing spermatogenesis and identifying specific testicular pathologies. It also provides excellent visualization of cellular and tissue morphology. These stained sections were then examined under a light microscope coupled with a host computer for detailed analysis and digital image acquisition [72, 73].

2.5. Statistical Analysis. All experimental data were presented as mean ± standard error of the mean (SEM), with a size of eight rats per group specified for each parameter. Descriptive statistics, including measures of central tendency (mean) and dispersion (SEM), were employed for data summarization. Comparative analyses were conducted using one-way analysis of variance (ANOVA) with Tukey's post hoc test for multiple comparisons, implemented in GraphPad Prism software (Version 8.0). A threshold of $p < 0.05$ was established to denote statistical significance.

3. Results

3.1. Effects of BEP Treatment on the Body Weight and Testicular Weight. Table 2 shows the effects of treatments on body weight and testicular weight as depicted by differences in body weight (DBW), percentage weight gain/loss (PW), and testicular-somatic index. At the end of treatment and recovery period, the control group gained 53.6 g (PW = 31.0%, TSI = 0.9%), BEP group lost 3.1 g (PW = −1.4%, TSI = 0.5%). The GKE group gained 60.3 g (PW = 26.2%, TSI = 1.0%), while the KV group gained 40.9 g (PW = 19.2%, TSI = 1.1%). In the GKE + BEP group, there was 19.1 g (PW = 8.2%, TSI = 0.6%) weight gain following recovery from BEP exposure, while the KV + BEP group gained 19.0 g (PW = 8.7%, TSI = 0.5%) and the SLM + BEP group gained 20.2 g (PW = 9.2%, TSI = 0.6%).

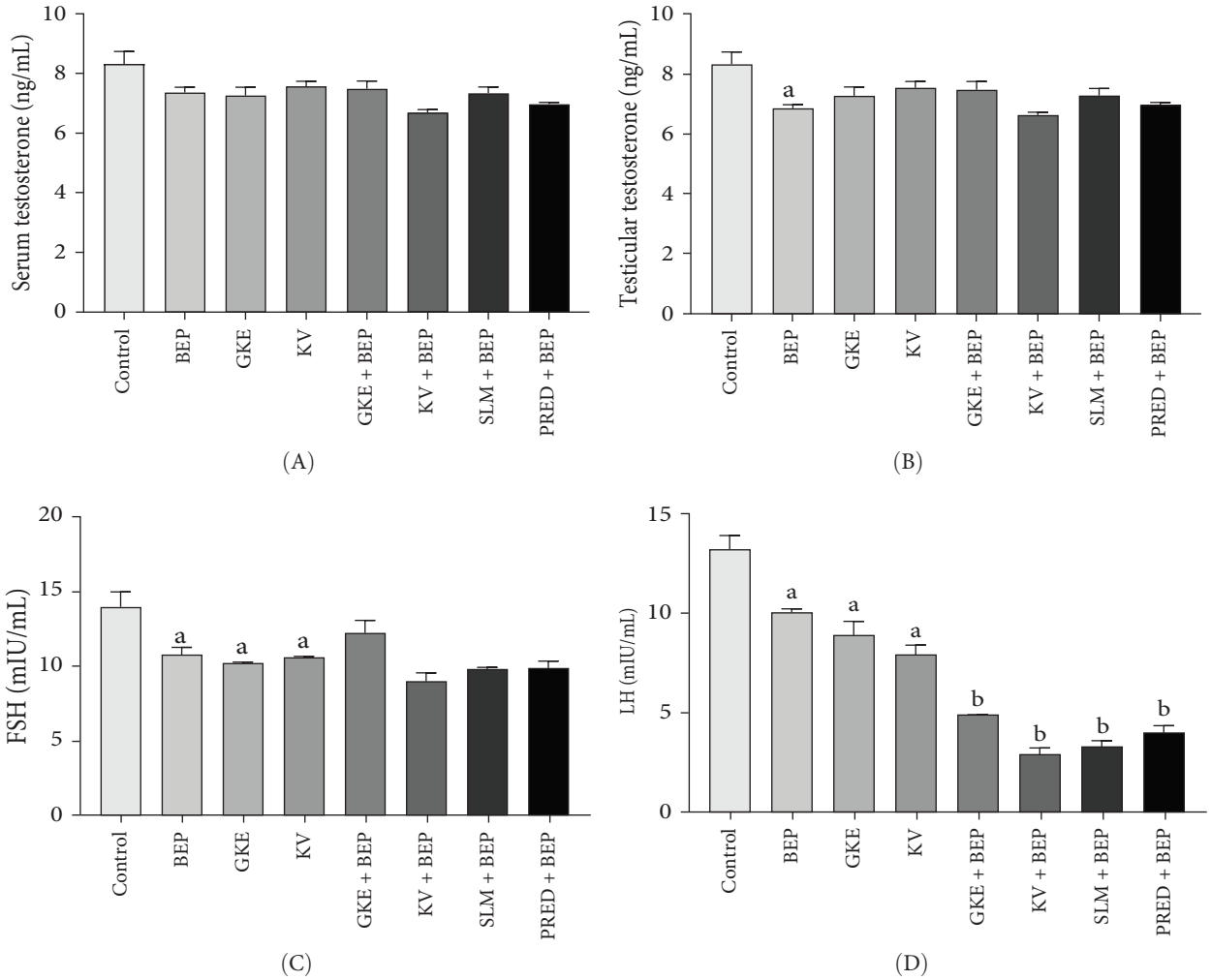

Figure 2: Modulatory effects of *Garcinia kola* extract (GKE) and kolaviron (KV) on reproductive hormone profiles in BEP-treated rats. This figure illustrates changes in key reproductive hormones following BEP chemotherapy and co-administration of GKE, KV, silymarin (SLM), and prednisolone (PRED). Panels depict: (A) serum testosterone, (B) testicular testosterone, (C) serum follicle-stimulating hormone (FSH), and (D) serum luteinizing hormone (LH). Statistical significance is denoted as: [a]$p < 0.05$ versus control group; [b]$p < 0.05$ versus BEP-alone treated group. BEP, bleomycin, etoposide, cisplatin; GKE, *Garcinia kola* extract; KV, kolaviron; SLM, silymarin; PRED, prednisolone.

However, in the PRED + BEP treated group, there was a remarkable loss of 18.61 g (PW = −8.2%, TSI = 0.6%).

3.2. Hormonal Assessment. Figure 2A–D depicts how BEP, GKE, KV, SLM, and PRED therapy changed TST, FSH, and LH levels in different experimental groups. BEP treatment reduced serum testosterone (ST) (7.4 ± 0.2 vs 8.3 ± 0.4, $p > 0.05$), testicular testosterone (TT) (6.9 ± 0.1 vs 8.3 ± 0.4, $p < 0.05$), serum FSH (10.8 ± 0.5 vs 13.9 ± 2.2, $p > 0.05$), and serum LH (10.0 ± 1.9 vs 13.2 ± 1.8, $p > 0.05$) when compared with control. Also, GKE-only treatment reduced ST (7.3 ± 0.3 vs 8.3 ± 0.4, $p > 0.05$), TT (7.3 ± 0.3 vs 8.3 ± 0.4, $p > 0.05$), serum FSH (10.2 ± 0.1 vs 13.9 ± 2.2, $p > 0.05$), and serum LH (8.9 ± 1.8 vs 13.2 ± 1.8, $p > 0.05$) when compared with control. KV-only treatment reduced ST (7.6 ± 0.2 vs 8.3 ± 0.4, $p > 0.05$), TT (7.5 ± 0.2 vs 8.3 ± 0.4, $p > 0.05$), serum FSH (10.6 ± 0.1 vs 13.9 ± 2.2, $p > 0.05$), and serum LH (7.9 ± 2.2 vs 13.2 ± 1.8, $p > 0.05$) when compared with control. In GKE + BEP group, GKE increased ST ($p > 0.05$), TT ($p > 0.05$), and FSH ($p > 0.05$), but not LH ($p > 0.05$) levels in BEP-treated rats compared to BEP group. In the KV + BEP group, KV decreased ST ($p > 0.05$), TT ($p > 0.05$) and FSH ($p > 0.05$), and LH ($p < 0.05$) levels in BEP-treated rats compared to BEP group. In the SLM + BEP group, SLM increased TT ($p > 0.05$), but decreased ST ($p > 0.05$) and FSH ($p > 0.05$), and LH ($p > 0.05$) levels in BEP-treated rats compared to BEP group. PRED decreased ST ($p > 0.05$), TT ($p > 0.05$), FSH ($p > 0.05$), and LH ($p > 0.05$) levels in BEP-treated rats compared to BEP group.

3.3. Effects of BEP on Sperm Parameters. Analysis of sperm parameters in BEP-treated animals is shown in Figure 3A–C. BEP treatment reduced sperm count (80.3 ± 2.3 vs 95.0 ± 5.0, $p > 0.05$), viability (51.7 ± 1.7 vs $71.67 \pm 1.7\%$, $p < 0.05$), and motility (44.0 ± 3.1 vs $65.0 \pm 2.9\%$, $p < 0.05$) when compared with control. Treatment with GKE and KV significantly

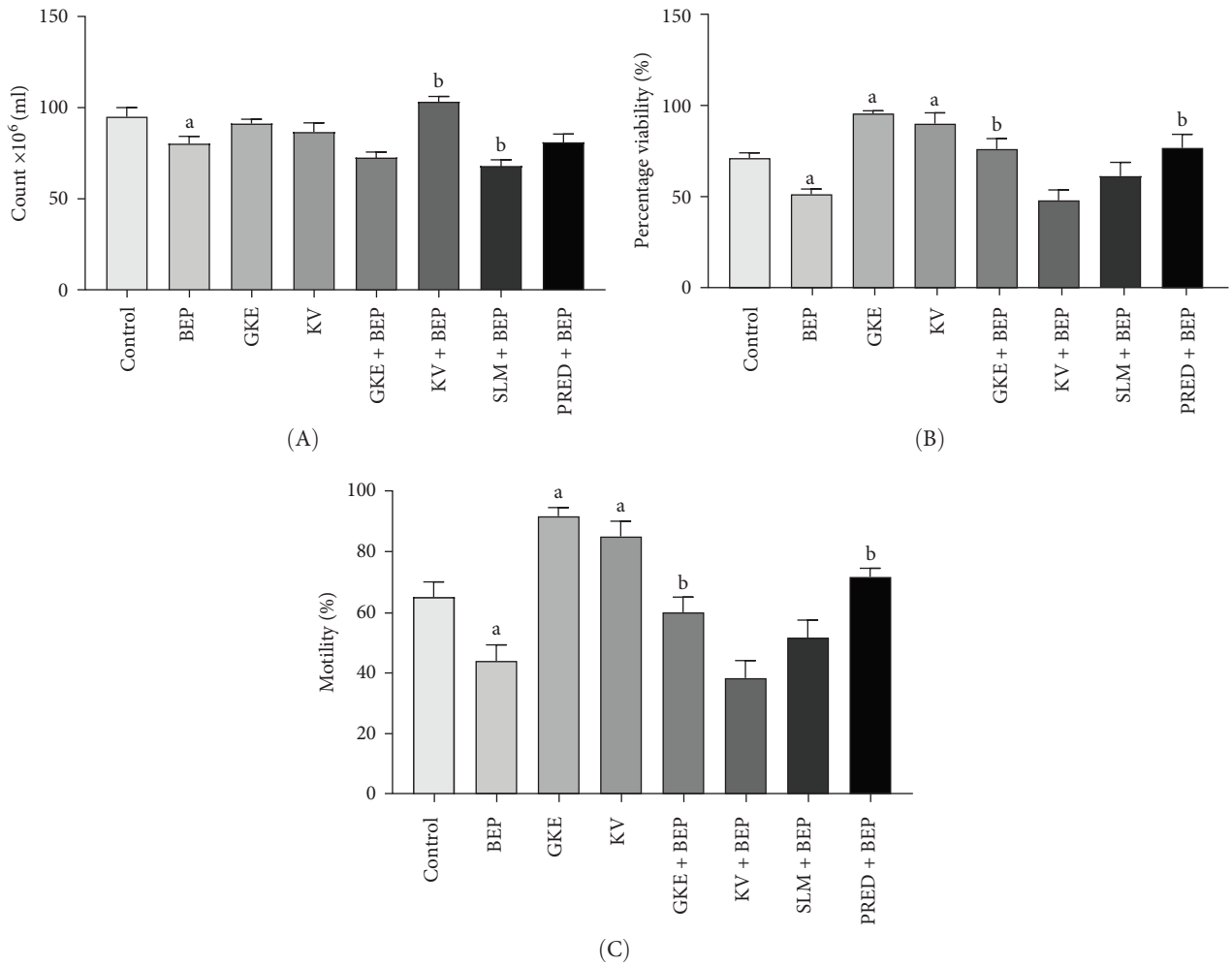

Figure 3: Ameliorative effects of *Garcinia kola* extract (GKE) and kolaviron (KV) on sperm parameters in BEP-treated male rats. This figure presents the impact of BEP chemotherapy and co-administration of GKE, KV, silymarin (SLM), and prednisolone (PRED) on key indicators of male reproductive health. Panels illustrate: (A) sperm count, (B) sperm viability, and (C) sperm motility. Statistical significance is indicated by: $^{a}p < 0.05$ versus control group; $^{b}p < 0.05$ versus BEP-alone treated group.

($p < 0.05$) increased sperm viability (96.3 ± 0.9, 90.7 ± 3.5 vs $71.7 \pm 1.7\%$) and motility (91.7 ± 1.7, 85.0 ± 2.9 vs $65.0 \pm 2.9\%$) in healthy rats when compared with control. Only GKE significantly increased viability and motility in BEP-treated rats when compared with BEP-alone ($p < 0.05$) (Figure 3B,C). There was no significant reversal of BEP-induced sperm viability or motility in KV + BEP group when compared with BEP-alone, however, the sperm count increased significantly ($p < 0.05$). Also, no significant ($p > 0.05$) increase in count, viability, and motility was seen in SLM + BEP when compared with BEP alone. However, PRED significantly increased viability and motility but not sperm count in BEP-treated rats when compared with BEP alone.

3.4. Assessment of Treatments on Testicular Oxidative Stress Markers. Table 3 summarizes the effects of various treatments on testicular antioxidant status in rats. Administration of the BEP regimen significantly reduced the activities of key testicular antioxidant enzymes, including GSH ($p < 0.05$) and SOD ($p < 0.05$), while GST and CAT showed nonsignificant decreases compared to controls. Concurrently, BEP treatment led to a significant elevation in testicular MDA levels ($p < 0.05$), a marker of lipid peroxidation, alongside a nonsignificant increase in NO) when compared to the control groups. However, co-administration of GKE with BEP effectively reversed these detrimental effects. GKE significantly increased GSH ($p < 0.05$), GST ($p < 0.05$), and SOD ($p < 0.05$) activities, while CAT levels also increased (though nonsignificantly) compared to the BEP-alone group. Furthermore, GKE co-administration significantly reduced NO levels ($p < 0.05$), and nonsignificantly decreased MDA levels, demonstrating its protective antioxidant capacity. Similarly, KV co-administration with BEP mitigated oxidative stress. KV significantly increased GST ($p < 0.05$) and SOD ($p < 0.05$) activities, alongside a nonsignificant increase in CAT. KV also significantly decreased both MDA ($p < 0.05$) and NO ($p < 0.05$) levels compared to the BEP group. In contrast, SLM co-administration with BEP showed more selective effects. While SLM significantly increased CAT activity ($p < 0.05$), its effects on GSH, GST, and SOD were not statistically significant. SLM also

Table 3: Activities of the testicular tissue antioxidant markers.

Drug treatment	GSH (μmoles/mg protein)	GST (U/mg protein)	CAT (U/mg protein)	SOD (U/mg protein)	MDA (ηmoles/mg protein)	NO (μmoles/mg protein)
Control	12.4 ± 1.1	0.2 ± 0.0	28.7 ± 1.0	0.3 ± 0.0	0.8 ± 0.1	5.9 ± 0.6
BEP	6.2 ± 0.7^{a}	0.1 ± 0.0	16.7 ± 0.9	0.1 ± 0.0^{a}	1.9 ± 0.2^{a}	8.3 ± 0.3
GKE	6.6 ± 0.8^{a}	0.3 ± 0.0^{a}	19.5 ± 1.8	0.4 ± 0.0	1.3 ± 0.1	5.7 ± 0.7
KV	6.8 ± 0.5^{a}	0.2 ± 0.0	15.8 ± 1.2	0.33 ± 0.1	1.2 ± 0.2	3.8 ± 0.6
GKE + BEP	12.1 ± 0.5^{b}	0.3 ± 0.0^{b}	29.6 ± 2.2	0.5 ± 0.0^{b}	1.4 ± 0.1	4.1 ± 0.5^{b}
KV + BEP	6.4 ± 0.9	0.2 ± 0.0	26.5 ± 1.1	0.2 ± 0.0	0.87 ± 0.0^{b}	4.1 ± 0.5^{b}
SLM + BEP	9.8 ± 0.4	0.2 ± 0.0	45.4 ± 1.3^{b}	0.3 ± 0.0	1.8 ± 0.2	10.3 ± 0.2
PRED + BEP	7.5 ± 0.7	0.2 ± 0.0	22.7 ± 1.8	0.4 ± 0.0^{b}	1.5 ± 0.1	6.7 ± 0.3

Note: The results for glutathione (GSH), glutathione-*S*-transferase (GST), catalase (CAT), superoxide dismutase (SOD), malondialdehyde (MDA), and nitric oxide (NO).
Abbreviations: BEP, bleomycin, etoposide, cisplatin; GKE, *Garcinia kola* extract; KV, kolaviron; PRED, prednisolone; SLM, silymarin.
[a]$p < 0.05$ vs control.
[b]$p < 0.05$ vs BEP.

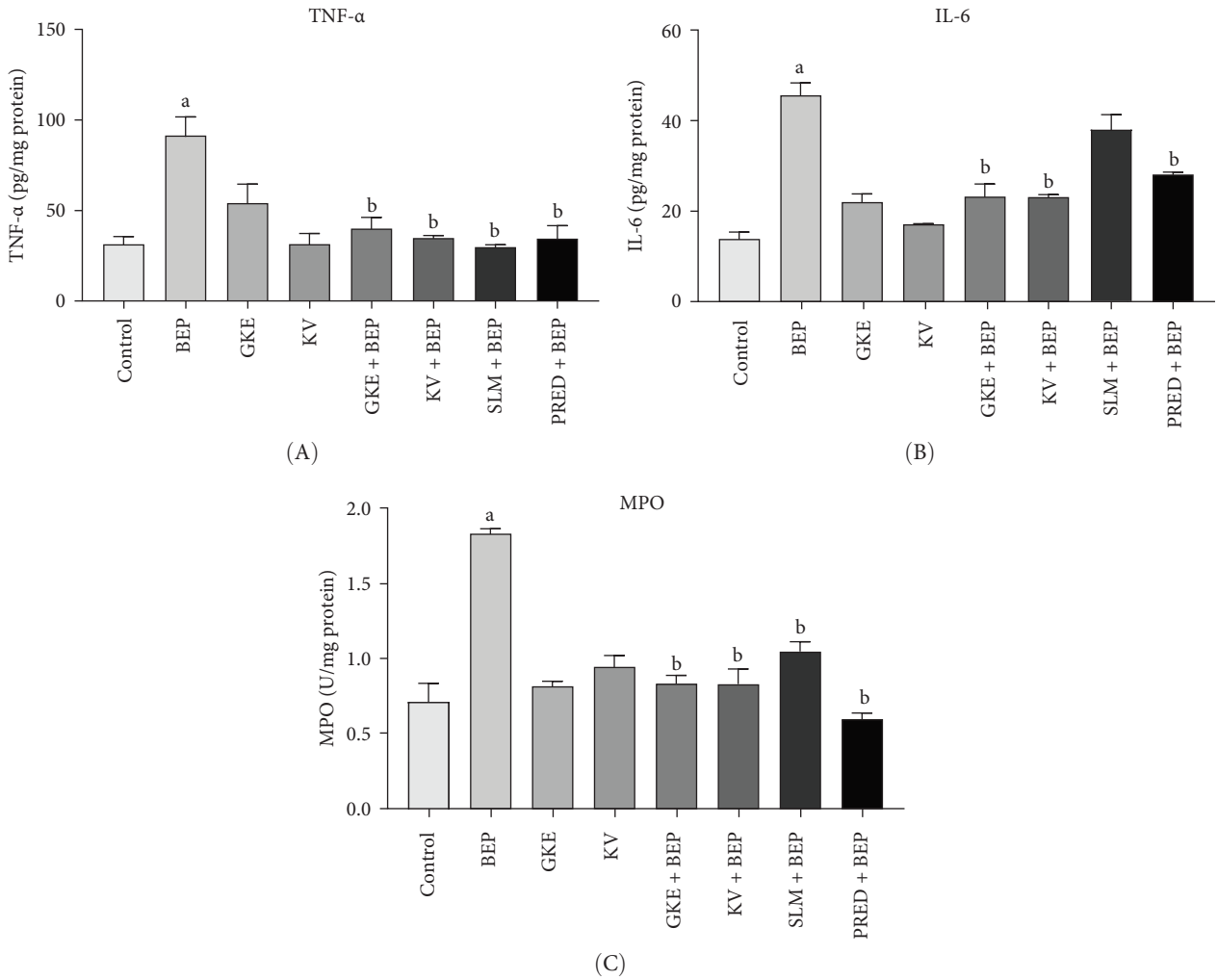

Figure 4: Modulatory effects of *Garcinia kola* extract (GKE) and Kolaviron (KV) on testicular inflammatory parameters in BEP-treated animals. This figure illustrates the impact of BEP chemotherapy and co-administration of GKE, KV, silymarin (SLM), and prednisolone (PRED) on key markers of inflammation within the testicular tissue. Panels display concentrations of (A) tumor necrosis factor-alpha (TNF-α), (B) interleukin-6 (IL-6), and (C) myeloperoxidase (MPO). Statistical significance is denoted as: $^{a}p < 0.05$ versus control group; $^{b}p < 0.05$ versus BEP-alone treated group.

nonsignificantly decreased MDA and NO levels compared to the BEP group.

3.5. Effects of Treatments on Pro-Inflammatory Cytokine Levels in Rat Testicular Tissue. Administration of the BEP regimen significantly augmented testicular tissue concentrations of pro-inflammatory cytokines, specifically TNF-α, IL-6, and myeloperoxidase (MPO) in BEP-treated rats compared to the control group ($p < 0.05$) (Figure 4A–C). Conversely, treatment with GKE or KV alone did not significantly alter the basal levels of testicular TNF-α, IL-6, or MPO. Importantly, co-administration of GKE, KV, SLM, or PRED with BEP led to a significant reduction ($p < 0.05$) in the BEP-induced elevation of testicular TNF-α, IL-6, and MPO concentrations when compared to the BEP-alone group (Figure 4A–C). The only exception was the SLM + BEP group, where the reduction in IL-6 levels did not reach statistical significance (Figure 4B). These findings collectively demonstrate the anti-inflammatory potential of the tested compounds against BEP-induced testicular inflammation.

3.6. Effects of Extract Treatments on Testicular Apoptotic Markers. Figure 5A,B illustrates the influence of various treatment regimens on key apoptotic markers within the testicular tissue. BEP treatment significantly elevated testicular CAS-9 and CAS-3 concentrations in the BEP group compared to the control group ($p < 0.05$). Conversely, administration of GKE alone resulted in a significant increase in CAS-9 ($p < 0.05$) but a nonsignificant increase in CAS-3 ($p > 0.05$). Similarly, KV alone led to non-significant increases in both CAS-9 ($p > 0.05$) and CAS-3 ($p > 0.05$) levels compared to the control.

Regarding co-administration, a significant reduction in CAS-9 concentration ($p < 0.05$) was observed in the GKE + BEP and KV + BEP groups when compared to the BEP-alone group (Figure 5A). However, in the SLM + BEP and PRED +

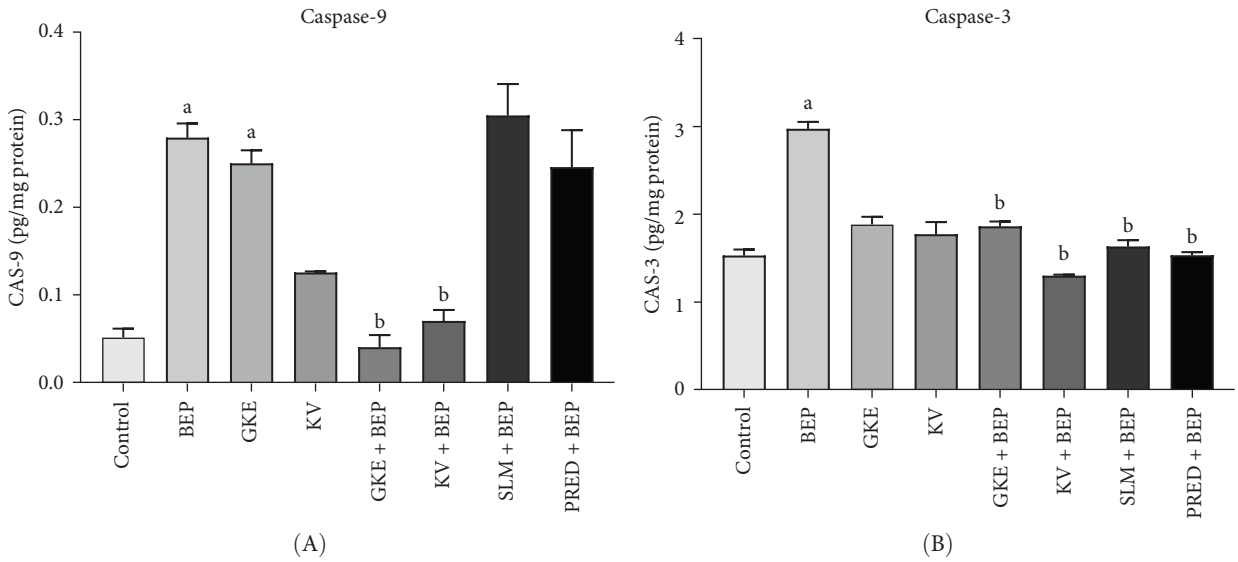

FIGURE 5: (A) and (B) Modulatory effects of *Garcinia kola* extract (GKE) and Kolaviron (KV) on apoptotic markers in testicular tissues of BEP (bleomycin, etoposide, and cisplatin combination)-treated animals. This figure illustrates the impact of BEP chemotherapy and co-administration of GKE, KV, silymarin (SLM), and prednisolone (PRED) on key indicators of cellular apoptosis within the testicular parenchyma. Panels display concentrations of (A) caspase-9 and (B) caspase-3. Statistical significance is denoted as: $^{a}p < 0.05$ versus control group; $^{b}p < 0.05$ versus BEP-alone treated group.

BEP treated groups, the reduction in CAS-9 was not statistically significant ($p > 0.05$) compared to the BEP-alone group. All co-administration groups, including GKE + BEP, KV + BEP, SLM + BEP, and PRED + BEP, demonstrated a significant reduction in CAS-3 levels ($p < 0.05$) in BEP-treated rats when compared to the BEP-alone group (Figure 5B). These results suggest differential modulatory effects on the apoptotic cascade by the tested compounds.

3.7. Histopathological Assessment of Testicular Tissues. Figure 6A presents representative transverse sections of rat testes from various treatment groups, stained with PAS-H and visualized at 400x magnification. Photomicrograph 1 (Control group) displays normal testicular histology, characterized by intact seminiferous epithelium exhibiting all stages of spermatogenesis; Photomicrograph 2 (BEP-treated group): Reveals significant testicular damage induced by BEP, marked by atrophy of tubular germ cells (black arrows), presence of retained spermatids, and sloughing of spermatogenic cells into the lumen. Additionally, the basal membrane epithelial layer contains vacuolated Sertoli cells (red arrow), indicating cellular stress and degeneration. In stark contrast, photomicrographs 3 (GKE-treated group) and 4 (KV-treated group), representing animals treated with GKE and KV alone, respectively, demonstrate normal seminiferous tubule morphology with complete spermatogenesis. Furthermore, photomicrographs 5 (GKE + BEP-treated group), 6 (KV + BEP-treated group), 7 (SLM + BEP-treated group), and 8 (PRED + BEP-treated group) illustrate the protective effects of co-administration. These images show a preserved testicular architecture with seminiferous tubules containing spermatogenic cells undergoing normal spermatogenesis, indicating a significant amelioration of BEP-induced testicular damage by GKE, KV, SLM, and PRED.

Figure 6B presents representative transverse sections of rat testes from various treatment groups, stained with PAS-H stain and visualized under a light microscope at 400x magnification. Photomicrograph 1 (Control group) shows normal histology of the seminiferous epithelium, characterized by orderly arrangement of spermatogenic cells in all phases of spermatogenesis. In contrast, photomicrograph 2 (BEP-treated group) reveals significant testicular damage, with seminiferous tubules exhibiting pronounced tubular degeneration (blue arrow) and atrophy, alongside a disrupted germinal epithelium and compromised spermatogonia (yellow arrow). However, photomicrographs 3 through 8, representing the GKE, KV, GKE + BEP, KV + BEP, SLM + BEP, and PRED + BEP treated groups, respectively, demonstrate an absence of observable histological abnormalities, indicating protective or ameliorative effects against BEP-induced testicular pathology.

4. Discussion

TC remains one of the most common malignancies affecting men of reproductive age, yet it exhibits remarkably high cure rates due to early diagnostic advancements and the efficacy of the BEP chemotherapeutic regimen, which achieves 5-year survival rates exceeding 90% [74, 75]. Despite its recorded therapeutic success, BEP chemotherapy exerts deleterious effects on male fertility by inducing testicular dysfunction, resulting in diminished sperm count, compromised sperm quality, and potential transient or permanent infertility [76–78]. A key mechanistic contributor to such fertility impairment is oxidative stress, characterized by an imbalance between ROS and endogenous antioxidants [79, 80]. Within the male reproductive tract, excessive ROS generation disrupts spermatozoal integrity, promotes DNA fragmentation, and ultimately diminishes fertility [81, 82]. The susceptibility of sperm cells

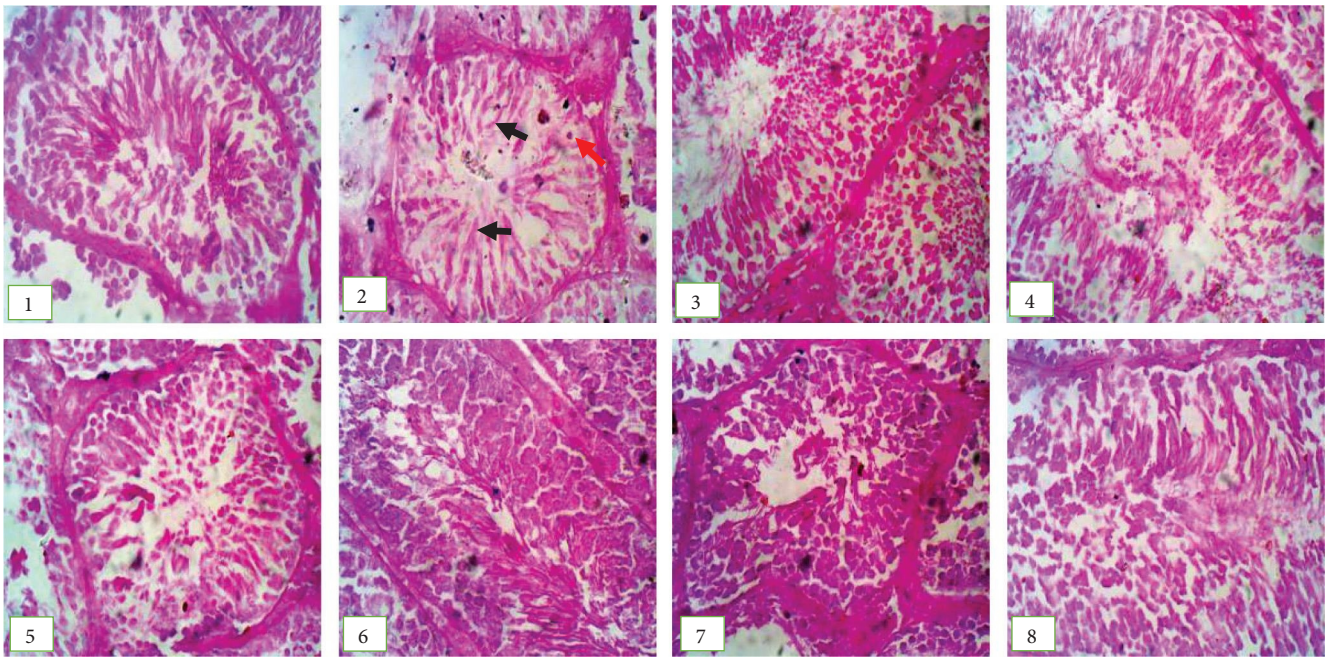

(A)

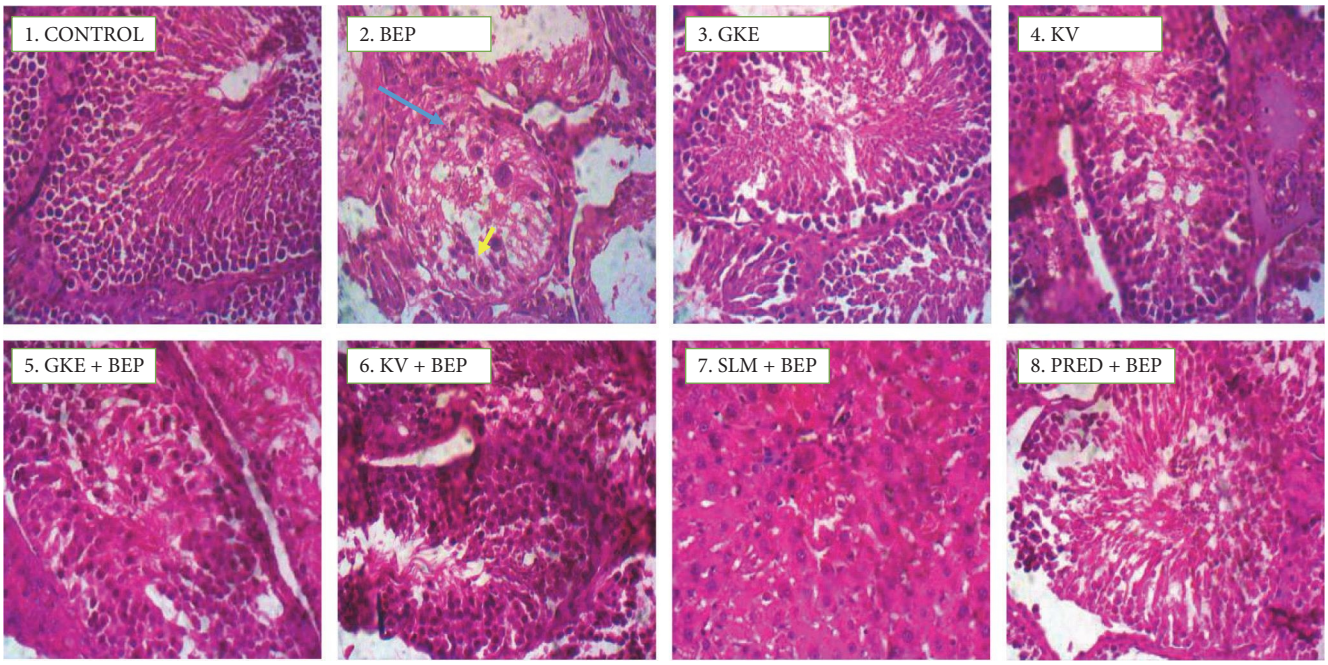

(B)

Figure 6: (A) Representative histopathological sections of rat testes across treatment groups. This figure presents transverse sectional photomicrographs of testicular tissues from various experimental groups, stained with periodic acid-Schiff-hematoxylin (PAS-H) and viewed under a light microscope at 400x magnification showing 1—Control group: which demonstrates normal testicular architecture; 2—BEP group: significant testicular damage characterized by atrophy of tubular germ cells (black arrow) and vacuolated Sertoli cells (red arrow); 3—GKE group: exhibits normal testicular histology; 4—KV group: which displays normal testicular histology; 5—GKE + BEP group which reveals amelioration of BEP-induced damage with preserved testicular architecture; 6—KV + BEP group which shows preserved testicular architecture following co-treatment; 7—SLM + BEP group which indicates a protective effect against BEP-induced testicular alterations; and 8—PRED + BEP group which displays restored testicular morphology after co-administration with BEP. (B) Representative histopathological sections of rat testes across treatment groups. This figure presents representative transverse sectional photomicrographs of testicular tissues from various experimental groups, stained with PAS-H, and viewed under a light microscope at ×400 magnification showed: 1—Control group: which shows normal testicular architecture; 2—BEP group: which shows significant testicular damage, characterized by tubular degeneration (blue arrow) and atrophy with a disrupted germinal epithelium and compromised spermatogonia (yellow arrow); 3—GKE group: showing normal testicular histology; 4—KV group: showing normal testicular histology; 5— GKE + BEP group: showing the

amelioration of BEP-induced damage with preserved testicular architecture; 6—KV + BEP group: showing preserved testicular architecture following co-treatment; 7—SLM + BEP group: showing a protective effect against BEP-induced testicular alterations; and 8—PRED + BEP group: showing restored testicular morphology after co-administration with BEP.

to oxidative damage is further exacerbated by the high polyunsaturated fatty acid content in their membranes and the elevated metabolic activity within gonadal tissues [83].

Emerging evidence suggests that GK and its bioactive biflavonoid constituent, KV, may counteract these adverse effects. KV exhibits potent antioxidant and anti-inflammatory properties, effectively scavenging free radicals while upregulating endogenous antioxidant enzymes such as SOD, CAT, and GSH-Px, thereby mitigating oxidative injury to spermatogenic cells and enhancing seminal parameters [84–87]. Additionally, KV modulates key reproductive hormones, including TST, LH, and FSH, thereby supporting Leydig cell functionality and hypothalamic–pituitary–gonadal axis regulation [85, 88]. However, the potential dose-dependent toxicity of GKE extracts at elevated concentrations warrants further investigation [89, 90].

This study evaluates the comparative efficacy of GKE and KV against BEP-induced testicular damage, using SLM and PRED as reference agents. Prior research has associated BEP-induced reductions in testicular weight with oxidative stress [91, 92]. However, our results demonstrate that GKE, KV, SLM, and PRED significantly attenuated BEP-mediated testicular weight loss. Although BEP consistently impaired sperm count, viability, and motility, GKE and KV administration notably improved sperm viability and motility, with GKE exhibiting superior protective effects, a finding consistent with existing literature on GK's spermatoprotective properties [93]. Intriguingly, PRED emerged as the most effective intervention in restoring sperm viability and motility, followed by GKE, SLM, and KV.

A pivotal observation from this investigation is the pronounced enhancement of sperm viability and motility following PRED administration in BEP-treated rats, despite its negligible impact on sperm count. While the National Cancer Institute (NCI) recognizes BEP as the gold-standard chemotherapeutic regimen for TC, a thorough review of existing literature revealed no preclinical or clinical studies documenting PRED's role in preserving spermatogenesis in this context. Thus, this study represents the first report elucidating PRED's potential chemopreventive effects against BEP-induced spermatotoxicity in Wistar rats.

Excessive ROS accumulation disrupts sperm structural and functional integrity, precipitating lipid peroxidation and fertility decline. BEP treatment markedly elevated ROS/reactive nitrogen species (RNS) while depleting testicular antioxidant reserves (SOD, GSH, GST, CAT), concomitant with increased MDA and nitrite levels. Treatment with GKE, KV, SLM, or PRED effectively restored the testicular oxidative defense system, reducing MDA and NO concentrations, with GKE demonstrating superior efficacy. These findings align with prior studies on GK [94], SLM [95–97], and PRED [98] in oxidative stress mitigation.

Moreover, BEP significantly upregulated pro-inflammatory mediators, including (TNF-α, IL-6, and MPO), indicative of testicular inflammation. GKE, KV, SLM, and PRED administration attenuated these inflammatory markers. BEP also triggered apoptotic pathways, evidenced by elevated CAS-3 and CAS-9 expression. Notably, GKE and KV substantially suppressed apoptotic activity by downregulating these caspases, whereas SLM and PRED only reduced CAS-3 without affecting CAS-9. These observations corroborate previous reports on GKE/KV's anti-apoptotic effects [99–101] and partially align with the mechanisms of SLM [102–104] and PRED [105, 106].

Histopathological analyses reinforced biochemical findings, revealing that BEP induced severe testicular damage, including tubular atrophy, germ cell exfoliation, and Sertoli cell vacuolation—consistent with prior studies [98, 99]. Conversely, GKE, KV, SLM, and PRED preserved testicular architecture, maintaining intact seminiferous tubules with normal germ cell stratification.

5. Conclusion

BEP-induced testicular toxicity is mechanistically driven by oxidative stress, inflammatory cytokine activation, endocrine disruption, and apoptotic signaling. This study demonstrates that adjunctive therapy with GKE, KV, SLM, or PRED effectively mitigates BEP's detrimental testicular effects by modulating these pathological pathways.

Data Availability Statement

Data for this study will be made available upon request.

Conflicts of Interest

The authors declare no conflicts of interest.

Funding

No funding was received for the work reported in this manuscript.

Acknowledgments

We extend our sincere gratitude for the invaluable technical assistance that illuminated this research. Our appreciation goes to Mr. Ikechukwu I. Okoye of the Department of Oral Pathology and Oral Medicine, Faculty of Dentistry, Lagos State University College of Medicine, Ikeja, Lagos State, Nigeria, whose expert hands meticulously prepared the tissue slides, rendering the microscopic world visible. We are profoundly grateful to Dr. Jarikre Theophilus from the Department of Veterinary Pathology, Faculty of Veterinary Medicine, University of Ibadan, Ibadan, Oyo State, Nigeria, whose discerning eye and profound knowledge guided the accurate interpretation of the histological slides. A special note of thanks is also extended to

Dr. Onome Bright for her instrumental assistance with the intricate semen analysis.

References

[1] E. Rajpert-De Meyts, L. Aksglaede, M. Bandak, J. Toppari, and N. Jørgensen, "Testicular Cancer: Pathogenesis, Diagnosis and Management With Focus on Endocrine Aspects," Endotext [Internet] (2023).

[2] J. K. Gurney, A. A. Florio, A. Znaor, et al., "International Trends in the Incidence of Testicular Cancer: Lessons From 35 Years and 41 Countries," *European Urology* 76, no. 5 (2019): 615–623.

[3] R. Xavier, R. C. de Carvalho, and R. Fraietta, "Semen Quality From Patients Affected by Seminomatous and Non-Seminomatous Testicular Tumor," *International Brazilian Journal of Urology* 47, no. 3 (2021): 495–502.

[4] H. Møller and H. Evans, "Epidemiology of Gonadal Germ Cell Cancer in Males and Females," *APMIS* 111, no. 1 (2003): 43–48.

[5] M. Moradi, N. Goodarzi, A. Faramarzi, H. Cheraghi, A. H. Hashemian, and C. Jalili, "Melatonin Protects Rats Testes Against Bleomycin, Etoposide, and Cisplatin-Induced Toxicity via Mitigating Nitro-Oxidative Stress and Apoptosis," *Biomedicine & Pharmacotherapy* 138 (2021): 111481.

[6] E. M. Ward, R. L. Sherman, S. J. Henley, et al., "Annual Report to the Nation on the Status of Cancer, Featuring Cancer in Men and Women Aged 20-49 Years," *JNCI: Journal of the National Cancer Institute* 111, no. 12 (2019): 1279–1297.

[7] K. Kawai and H. Akaza, "Current Status of Chemotherapy in Risk-Adapted Management for Metastatic Testicular Germ Cell Cancer," *Cancer Science* 101, no. 1 (2010): 22–28.

[8] N. Adra and L. H. Einhorn, "Testicular Cancer Update," *Clinical Advances in Hematology & Oncology: H&O* 15, no. 5 (2017): 386–396.

[9] E. S. Sabanegh Jr and A. M. Ragheb, "Male Fertility After Cancer," *Urology* 73, no. 2 (2009): 225–231.

[10] R. A. Huddart and A. J. Birtle, "Recent Advances in the Treatment of Testicular Cancer," *Expert Review of Anticancer Therapy* 5, no. 1 (2005): 123–138.

[11] M. Brydøy, S. D. Fosså, O. Klepp, et al., "Paternity and Testicular Function Among Testicular Cancer Survivors Treated With Two to Four Cycles of Cisplatin-Based Chemotherapy," *European Urology* 58, no. 1 (2010): 134–141.

[12] S. M. Lambert and H. Fisch, "Infertility and Testis Cancer," *Urologic Clinics of North America* 34, no. 2 (2007): 269–277.

[13] M. L. Meistrich, M. Finch, M. F. da Cunha, U. Hacker, and W. W. Au, "Damaging Effects of Fourteen Chemotherapeutic Drugs on Mouse Testis Cells," *Cancer Research* 42, no. 1 (1982): 122–131.

[14] A. L. de Almeida, A. Fortuna, M. Sousa, and R. Sá, "A Systematic Review of Bleomycin-Induced Gonadotoxicity: Mechanistic Implications for Male Reproductive Health and Fertility," *Reproductive Toxicology* 130 (2024): 108721.

[15] A. Samanta, T. R. Maity, S. Das, A. K. Datta, and S. Datta, "Effect of Etoposide on Grass Pea DNA Topoisomerase II: An *in silico*, *in vivo*, and *in vitro* Assessments," *Bulletin of the National Research Centre* 43, no. 1 (2019): 170.

[16] P. B. Tchounwou, S. Dasari, F. K. Noubissi, P. Ray, and S. Kumar, "Advances in Our Understanding of the Molecular Mechanisms of Action of Cisplatin in Cancer Therapy," *Journal of Experimental Pharmacology* 13 (2021): 303–328.

[17] K. Narayana, M. Al-Bader, A. Mousa, and K. M. Khan, "Molecular Effects of Chemotherapeutic Drugs and Their Modulation by Antioxidants in the Testis," *European Journal of Pharmacology* 674, no. 2-3 (2012): 207–216.

[18] J. Lauritsen, M. K. Hansen, M. Bandak, et al., "Cardiovascular Risk Factors and Disease After Male Germ Cell Cancer," *Journal of Clinical Oncology* 38, no. 6 (2020): 584–592.

[19] V. Borbélyová, E. Renczés, M. Chovanec, M. Mego, and P. Celec, "Transient Effects of Chemotherapy for Testicular Cancer on Mouse Behaviour," *Scientific Reports* 10, no. 1 (2020): 10224.

[20] A. Agarwal and S. S. Allamaneni, "Disruption of Spermatogenesis by the Cancer Disease Process," *Journal of the National Cancer Institute Monographs* 2005, no. 34 (2005): 9–12.

[21] G. Delbès, D. Chan, P. Pakarinen, J. M. Trasler, B. F. Hales, and B. Robaire, "Impact of the Chemotherapy Cocktail Used to Treat Testicular Cancer on the Gene Expression Profile of Germ Cells From Male Brown-Norway Rats," *Biology of Reproduction* 80, no. 2 (2009): 320–327.

[22] M. L. Meistrich, "Effects of Chemotherapy and Radiotherapy on Spermatogenesis in Humans," *Fertility and Sterility* 100, no. 5 (2013): 1180–1186.

[23] G. Delbes, B. F. Hales, and B. Robaire, "Effects of the Chemotherapy Cocktail Used to Treat Testicular Cancer on Sperm Chromatin Integrity," *Journal of Andrology* 28, no. 2 (2007): 241–249.

[24] N. Kilarkaje, A. M. Mousa, M. M. Al-Bader, and K. M. Khan, "Antioxidants Enhance the Recovery of Three Cycles of Bleomycin, Etoposide, and Cisplatin–Induced Testicular Dysfunction, Pituitary-Testicular Axis, and Fertility in Rats," *Fertility and Sterility* 100, no. 4 (2013): 1151–1159.e5.

[25] Y. Tadokoro, K. Yomogida, H. Ohta, A. Tohda, and Y. Nishimune, "Homeostatic Regulation of Germinal Stem Cell Proliferation by the GDNF/FSH Pathway," *Mechanisms of Development* 113, no. 1 (2002): 29–39.

[26] K. Yomogida, Y. Yagura, Y. Tadokoro, and Y. Nishimune, "Dramatic Expansion of Germinal Stem Cells by Ectopically Expressed Human Glial Cell Line-Derived Neurotrophic Factor in Mouse Sertoli Cells," *Biology of Reproduction* 69, no. 4 (2003): 1303–1307.

[27] K. D. Falang, M. O. Uguru, and N. L. Nnamonu, "Anti-Pyretic Activity of *Garcinia kola* Seed Extract," *European Journal of Medicinal Plants* 4, no. 5 (2014): 511–521.

[28] S. A. Onasanwo and R. A. Rotu, "Antinociceptive and Anti-Inflammatory Potentials of Kolaviron: Mechanisms of Action," *Journal of Basic and Clinical Physiology and Pharmacology* 27, no. 4 (2016): 363–370.

[29] C. O. Nwaehujor, R. I. Udegbunam, J. O. Ode, and S. O. Udegbunam, "Analgesic Anti-Inflammatory Anti-Pyretic Activities of Garcinia Hydroxybiflavanonol (GB1) From *Garcinia kola*," *Journal of the Korean Society for Applied Biological Chemistry* 58, no. 1 (2015): 91–96.

[30] W. O. Kalu, P. N. Okafor, I. I. Ijeh, and C. Eleazu, "Effect of Kolaviron, A Biflavanoid Complex From *Garcinia kola* on Some Biochemical Parameters in Experimentally Induced Benign Prostatic Hyperplasic Rats," *Biomedicine & Pharmacotherapy* 83 (2016): 1436–1443.

[31] E. O. Farombi, I. A. Adedara, B. O. Ajayi, O. R. Ayepola, and E. E. Egbeme, "Kolaviron, A Natural Antioxidant and Anti-Inflammatory Phytochemical Prevents Dextran

Sulphate Sodium-Induced Colitis in Rats," *Basic & Clinical Pharmacology & Toxicology* 113, no. 1 (2013): 49–55.

[32] G. O. Omotoso, I. I. Ukwubile, L. Arietarhire, F. Sulaimon, and I. T. Gbadamosi, "Kolaviron Protects the Brain in Cuprizone-Induced Model of Experimental Multiple Sclerosis via Enhancement of Intrinsic Antioxidant Mechanisms: Possible Therapeutic Applications?" *Pathophysiology* 25, no. 4 (2018): 299–306.

[33] H. Daïrou, E. Makembe, G. Nfor, R. Helena, A. Yoshikawa, and Y. Fanta, "Antioxidant Capacity and Anti-Inflammatory Activity of *Garcinia kola* (Heckel) Stem Bark Extracts," *International Journal of Herbal Medicine* 9 (2021): 16–27.

[34] B. O. Ugwuowo, A. Ahmed, H. O. Oluwasola, and P. O. Ukoha, "Comparative Assessment of Phytochemicals, Antioxidant Activity and Antimicrobial Activity of *Cola acuminata*, *Garcinia kola* and *Vernonia amygdalina*," *Journal of Chemical Society of Nigeria* 46, no. 4 (2021): 0698–0710.

[35] A. E. Idris, P. F. S. Etet, A. A. Saeed, et al., "Evaluation of Metabolic, Antioxidant and Anti-Inflammatory Effects of *Garcinia kola* on Diabetic Rats," *Saudi Journal of Biological Sciences* 27, no. 12 (2020): 3641–3646.

[36] E. O. Farombi, B. O. Ajayi, E. K. Opata, A. O. Fafioye, and A. T. Akinade, "Kolaviron Modulates Angiogenesis, Apoptosis and Inflammatory Signaling in Rat Model of Testosterone Propionate-Induced Benign Prostate Hyperplasia," *Inflammopharmacology* 31, no. 4 (2023): 2121–2131.

[37] I. A. Adedara, I. O. Awogbindin, I. C. Maduako, et al., "Kolaviron Suppresses Dysfunctional Reproductive Axis Associated With Multi-Walled Carbon Nanotubes Exposure in Male Rats," *Environmental Science and Pollution Research* 28, no. 1 (2021): 354–364.

[38] S. O. Abarikwu, E. O. Farombi, M. P. Kashyap, and A. B. Pant, "Kolaviron Protects Apoptotic Cell Death in PC12 Cells Exposed to Atrazine," *Free Radical Research* 45, no. 9 (2011): 1061–1073.

[39] M. M. Iwu, *Food as Medicine: Functional Food Plants of Africa* (Taylor & Francis eBooks DRM Free Collection, 2017).

[40] O. J. Uko, A. Usman, and A. M. Ataja, "Some Biological Activities of *Garcinia kola* in Growing Rats," *Veterinarski Arhiv* 71, no. 5 (2001): 287–297.

[41] H. Kagbo and D. Ejebe, "Phytochemistry and Preliminary Toxicity Studies of the Methanol Extract of the Stem Bark of *Garcinia kola* (Heckel)," *Internet Journal of Toxicology* 7, no. 2 (2010).

[42] B. Konziase, "Protective Activity of Biflavanones From *Garcinia kola* Against *Plasmodium* Infection," *Journal of Ethnopharmacology* 172 (2015): 214–218.

[43] T. K. Michel, A. A. Ottoh, U. C. E. Chukwunonye, E. C. Obodoike, O. Christopher, and I. M. Mmaduakolam, "Bio-Flavonoids and Garcinoic Acid From *Garcinia kola* Seeds With Promising Anti-Inflammatory Potentials," *Pharmacognosy Journal* 8, no. 1 (2015): 56–58.

[44] C. S. Nworu, P. A. Akah, C. O. Esimone, C. O. Okoli, and F. B. C. Okoye, "Immunomodulatory Activities of Kolaviron, A Mixture of Three Related Biflavonoids of, *Garcinia kola*," *Immunopharmacology and Immunotoxicology* 30, no. 2 (2008): 317–332.

[45] A. Altemimi, N. Lakhssassi, A. Baharlouei, D. G. Watson, and D. A. Lightfoot, "Phytochemicals: Extraction, Isolation, and Identification of Bioactive Compounds From Plant Extracts," *Plants* 6, no. 4 (2017): 42.

[46] E. O. Farombi, A. O. Abolaji, T. H. Farombi, A. S. Oropo, O. A. Owoje, and M. T. Awunah, "*Garcinia kola* Seed Biflavonoid Fraction (Kolaviron), Increases Longevity and Attenuates Rotenone-Induced Toxicity in *Drosophila melanogaster*," *Pesticide Biochemistry and Physiology* 145 (2018): 39–45.

[47] Q. K. Alabi, R. O. Akomolafe, O. S. Olukiran, et al., "The *Garcinia kola* Biflavonoid Kolaviron Attenuates Experimental Hepatotoxicity Induced by Diclofenac," *Pathophysiology* 24, no. 4 (2017): 281–290.

[48] O. R. Oyenihi, N. L. Brooks, and O. O. Oguntibeju, "Effects of Kolaviron on Hepatic Oxidative Stress in Streptozotocin Induced Diabetes," *BMC Complementary and Alternative Medicine* 15, no. 1 (2015): 236.

[49] S. O. Abarikwu, "Kolaviron, A Natural Flavonoid From the Seeds of *Garcinia kola*, Reduces LPS-Induced Inflammation in Macrophages by Combined Inhibition of IL-6 Secretion, and Inflammatory Transcription Factors, ERK1/2, NF-κB, p38, Akt, p-c-JUN and JNK," *Biochimica et Biophysica Acta (BBA) - General Subjects* 1840, no. 7 (2014): 2373–2381.

[50] G. Ibironke and A. Fasanmade, "Analgesic and Central Nervous System Depressant Activities of Kolaviron (A *Garcinia kola* Biflavonoid Complex)," *African Journal of Biomedical Research* 18, no. 3 (2015): 217–223.

[51] G. Karimi, M. Vahabzadeh, P. Lari, M. Rashedinia, and M. Moshiri, "Silymarin", A Promising Pharmacological Agent for Treatment of Diseases," *Iranian Journal of Basic Medical Sciences* 14, no. 4 (2011): 308–317.

[52] M. A. Ahmed, H. Tayawi, and M. Ibrahim, "Protective Effect of Silymarin Against Kidney Injury Induced by Carbon Tetrachloride in Male Rats," *Iraqi Journal of Veterinary Sciences* 33, no. 1 (2019): 127–130.

[53] H. M. El-hanbuli, A. F. Abo-sief, and T. Mostafa, "Protective Effect of Silymarin on the Testes of Rats Treated With Anabolic Androgenic Steroid: A Biochemical, Histological, Histochemical and Immunohistochemical Study," *Journal of Histology and Histopathology* 4 (2017): 10.

[54] R. Kaur, K. Kapoor, and H. Kaur, "Plants as a Source of Anticancer Agents," *Journal of Natural Product & Plant Resources* 1, no. 1 (2011): 119–124.

[55] B. O. Adetuyi, F. K. Omolabi, P. A. Olajide, and J. K. Oloke, "Pharmacological, Biochemical and Therapeutic Potential of Milk Thistle (Silymarin): A Review," *World News of Natural Sciences* 37 (2021): 75–91.

[56] J.-W. Wu, L.-C. Lin, and T.-H. Tsai, "Drug–Drug Interactions of Silymarin on the Perspective of Pharmacokinetics," *Journal of Ethnopharmacology* 121, no. 2 (2009): 185–193.

[57] R. Twycross, "The Risks and Benefits of Corticosteroids in Advanced Cancer," *Drug Safety* 11, no. 3 (1994): 163–178.

[58] A. J. Akindele, G. O. Oludadepo, K. I. Amagon, D. Singh, and D. D. Osiagwu, "Protective Effect of Carvedilol Alone and Coadministered With Diltiazem and Prednisolone on Doxorubicin and 5-Fluorouracil-Induced Hepatotoxicity and Nephrotoxicity in Rats," *Pharmacology Research & Perspectives* 6, no. 1 (2018): e00381.

[59] A. J. Akindele, K. I. Amagon, G. T. Ekundayo, D. Singh, and D. D. Osiagwu, "Amelioration of Doxorubicin-Induced Liver and Kidney Toxicities by Nicorandil Alone and Co-Administered With Prednisolone and Diltiazem," *Proceedings of the Nigerian Academy of Science* 12, no. 1 (2020).

[60] O. L. Erukainure, V. F. Salau, C. I. Chukwuma, and M. S. Islam, "Kolaviron: A Biflavonoid With Numerous Health Benefits," *Current Pharmaceutical Design* 27, no. 4 (2021): 490–504.

[61] C. S. Nworu and P. A. Akah, "Towards Harnessing the Therapeutic Potential of Kolaviron, A Biflavonoid Complex From, *Garcinia kola*, Heckl: A Review of Its Bioactivity and Mechanisms of Action," *Trends in Natural Products Research* 4, no. 1 (2023): 1–17.

[62] J. Tauchen, A. Frankova, A. Maňourová, I. Valterová, B. Lojka, and O. Leuner, "*Garcinia kola*: A Critical Review on Chemistry and Pharmacology of an Important West African Medicinal Plant," *Phytochemistry Reviews* 22, no. 5 (2023): 1305–1351.

[63] C. Manirafasha, O. R. Oyenihi, N. L. Brooks, S. S. du Plessis, and Y. G. Aboua, "Potential Antioxidative Effects of Kolaviron on Reproductive Function in Streptozotocin-Induced Diabetic Wistar Rats," in *Antioxidants*, (IntechOpen).

[64] National Institutes of Health, *Guide for the Care and use of Laboratory Animals* (US Department of Health, Education and Welfare, 1985): 85–23.

[65] R. R. Wadhwa, M. Cascella, R. R. Wadhwa, and M. Cascella, "Steady State Concentration," in *StatPearls*, (StatPearls Publishing, 2025, https://www.ncbi.nlm.nih.gov/books/NBK553132/.

[66] P. Prathima, K. Venkaiah, T. Daveedu, et al., "α-Lipoic Acid Protects Testis and Epididymis Against Linuron-Induced Oxidative Toxicity in Adult Rats," *Toxicological Research* 36, no. 4 (2020): 343–357.

[67] J. A. Buege and S. D. Aust, "Microsomal Lipid Peroxidation," *Methods in Enzymology* 52 (1978): 302–310.

[68] A. R. Purohit and M. V. Rao, "Mitigative Role of Melatonin and α-Tocopherol Against Mercury-Induced Genotoxicity," *Drug and Chemical Toxicology* 37, no. 2 (2014): 221–226.

[69] J. O. Omirinde, S. G. Olukole, and B. O. Oke, "Age-Related Changes in the Testicular Morphophysiology of the Cane Rat (*Thryonomys swinderianus*)," *Journal of Microscopy and Ultrastructure* 10, no. 3 (2022): 118–126.

[70] S. Yu, M. Rubin, S. Geevarughese, J. S. Pino, H. F. Rodriguez, and W. Asghar, "Emerging Technologies for Home-Based Semen Analysis," *Andrology* 6, no. 1 (2018): 10–19.

[71] S. Pourmasumi, A. Khoradmehr, T. Rahiminia, P. Sabeti, A. R. Talebi, and J. Ghasemzadeh, "Evaluation of Sperm Chromatin Integrity Using Aniline Blue and Toluidine Blue Staining in Infertile and Normozoospermic Men," *Journal of Reproduction & Infertility* 20, no. 2 (2019): 95–101.

[72] S. Mazaud-Guittot, A. Gow, and B. Le Magueresse-Battistoni, "Phenotyping the Claudin 11 Deficiency in Testis: From Histology to Immunohistochemistry," *Methods in Molecular Biology* 763 (2011): 223–236.

[73] P. Tian, Z. Yang, C. Qu, et al., "Exploration of Tissue Fixation Methods Suitable for Digital Pathological Studies of the Testis," *European Journal of Medical Research* 29, no. 1 (2024): 319.

[74] J. Maselli, B. F. Hales, P. Chan, and B. Robaire, "Exposure to Bleomycin, Etoposide, and Cis-Platinum Alters Rat Sperm Chromatin Integrity and Sperm Head Protein Profile," *Biology of Reproduction* 86, no. 5 (2012): 166.

[75] R. A. Huddart and A. M. Reid, "Adjuvant Therapy for Stage IB Germ Cell Tumors: One Versus Two Cycles of BEP," *Advances in Urology* 2018 (2018): 8781698.

[76] S. J. Gaddam, F. Bicer, and G. T. Chesnut, "Testicular Cancer," in *StatPearls*, (StatPearls Publishing, 2025, https://www.ncbi.nlm.nih.gov/books/NBK563159/.

[77] M. Ghezzi, M. Berretta, A. Bottacin, et al., "Impact of Bep or Carboplatin Chemotherapy on Testicular Function and Sperm Nucleus of Subjects With Testicular Germ Cell Tumor," *Frontiers in Pharmacology* 7 (2016): 122.

[78] S. Ghafouri-Fard, H. Shoorei, A. Abak, et al., "Effects of Chemotherapeutic Agents on Male Germ Cells and Possible Ameliorating Impact of Antioxidants," *Biomedicine & Pharmacotherapy* 142 (2021): 112040.

[79] K. Duffin, R. T. Mitchell, M. F. H. Brougham, G. Hamer, A. M. M. van Pelt, and C. L. Mulder, "Impacts of Cancer Therapy on Male Fertility: Past and Present," *Molecular Aspects of Medicine* 100 (2024): 101308.

[80] A. T. Alahmar, "Role of Oxidative Stress in Male Infertility: An Updated Review," *Journal of Human Reproductive Sciences* 12, no. 1 (2019): 4–18.

[81] B. Ayad, T. S. Omolaoye, N. Louw, et al., "Oxidative Stress and Male Infertility: Evidence From a Research Perspective," *Frontiers in Reproductive Health* 4 (2022): 822257.

[82] R. J. Aitken, J. R. Drevet, A. Moazamian, and P. Gharagozloo, "Male Infertility and Oxidative Stress: A Focus on the Underlying Mechanisms," *Antioxidants* 11, no. 2 (2022): 306.

[83] M. Lahimer, H. Mustapha, V. Bach, et al., "Oxidative Stress in Male Infertility and Therapeutic Approach: A Mini-Review," *Asian Pacific Journal of Reproduction* 12, no. 6 (2023): 249–255.

[84] N. B. Takalani, E. M. Monageng, K. Mohlala, T. K. Monsees, R. Henkel, and C. S. Opuwari, "Role of Oxidative Stress in Male Infertility," *Reproduction and Fertility* 4, no. 3 (2023): e230024.

[85] Y. Zhou, H. Zhang, H. Yan, P. Han, J. Zhang, and Y. Liu, "Deciphering the Role of Oxidative Stress in Male Infertility: Insights From Reactive Oxygen Species to Antioxidant Therapeutics," *Frontiers in Bioscience Landmark* 30, no. 4 (2025): 27046.

[86] I. A. Adedara and E. O. Farombi, "Kolaviron, A Biflavonoid Complex From *Garcinia kola* Seeds, Ameliorates Ethanol-Induced Reproductive Toxicity in Male Wistar Rats," *Nigerian Journal of Physiological Sciences* 28, no. 1 (2012): 9–16.

[87] A. Kehinde, A. Adefisan, O. Adebayo, and O. Adaramoye, "Biflavonoid Fraction From *Garcinia kola* Seed Ameliorates Hormonal Imbalance and Testicular Oxidative Damage by Anti-Tuberculosis Drugs in Wistar Rats," *Journal of Basic and Clinical Physiology and Pharmacology* 27, no. 4 (2016): 385–394.

[88] V. F. Salau, O. L. Erukainure, N. A. Koorbanally, and M. S. Islam, "Kolaviron Modulates Dysregulated Metabolism in Oxidative Pancreatic Injury and Inhibits Intestinal Glucose Absorption With Concomitant Stimulation of Muscle Glucose Uptake," *Archives of Physiology and Biochemistry* 129, no. 1 (2023): 157–167.

[89] V. Emojevwe, I. A. Adedara, D. A. Awele, R. A. Rotu, O. G. Adebayo, and O. A. Eneni, "Kolaviron, A Flavonoid-Rich Extract Ameliorates Busulfan-Induced Chemo-Brain and Testicular Damage in Male Rats through Inhibition of Oxidative Stress, Inflammatory, and Apoptotic Pathways," *Biomedicine & Pharmacotherapy* 142 (2021): 112022.

[90] A. J. Ajibade, O. O. Oyedapo, and O. M. Owolabi, "The Effect of Ethanolic Extract of *Garcinia kola* on the Sperm Parameters and Histology of the Testis of Male Wistar Rats," *International Journal of Pharmaceutical Sciences Review and Research* 10, no. 1 (2011): 162–166.

[91] C. E. Okafor, A. E. Onuka, I. O. Umoh, and F. N. Ugwu, "Ethanolic Seed Extract of *Garcinia kola* Reduces Epididymal Sperm Count and Some Serum Reproductive Hormone Concentrations in Adult Male Albino Wistar Rats," *Asian*

Journal of Research in Medical and Pharmaceutical Sciences 4, no. 2 (2018): 1–5.

[92] I. A. Adedara, I. O. Awogbindin, J. P. Anamelechi, and E. O. Farombi, "*Garcinia kola* Seed Ameliorates Renal, Hepatic, and Testicular Oxidative Damage in Streptozotocin-Induced Diabetic Rats," *Pharmaceutical Biology* 53, no. 5 (2015): 695–704.

[93] M. Moradi, M. A. Hashemian, A. Faramarzi, et al., "Therapeutic Effect of Sodium Alginate on Bleomycin, Etoposide and Cisplatin (BEP)-Induced Reproductive Toxicity by Inhibiting Nitro-Oxidative Stress, Inflammation and Apoptosis," *Scientific Report* 14, no. 1 (2024): 1565.

[94] E. O. Farombi, I. A. Adedara, A. B. Oyenihi, E. Ekakitie, and S. Kehinde, "Hepatic, Testicular and Spermatozoa Antioxidant Status in Rats Chronically Treated With *Garcinia kola* Seed," *Journal of Ethnopharmacology* 146, no. 2 (2013): 536–542.

[95] S. Sahreen, M. R. Khan, and R. A. Khan, "Ameliorating Effect of Various Fractions of *Rumex hastatus* Roots Against Hepato-and Testicular Toxicity Caused by CCl_4," *Oxidative Medicine and Cellular Longevity* 2013 (2013): 325406.

[96] Z. Zahra, M. R. Khan, M. Majid, S. Maryam, and M. Sajid, "Gonadoprotective Ability of *Vincetoxicum arnottianum* Extract Against Bisphenol A-Induced Testicular Toxicity and Hormonal Imbalance in Male Sprague Dawley Rats," *Andrologia* 52, no. 6 (2020): e13590.

[97] N. A. Shah and M. R. Khan, "Increase of Glutathione, Testosterone and Antioxidant Effects of Jurenia Dolomiaea on CCl_4 Induced Testicular Toxicity in Rat," *BMC Complementary and Alternative Medicine* 17, no. 1 (2017): 1–9.

[98] I. O. Shymanskyy, O. O. Lisakovska, A. O. Mazanova, D. O. Labudzynskyi, A. V. Khomenko, and M. M. Veliky, "Prednisolone and Vitamin D(3) Modulate Oxidative Metabolism and Cell Death Pathways in Blood and Bone Marrow Mononuclear Cells," *The Ukrainian Biochemical Journal* 88, no. 5 (2016): 38–47.

[99] I. A. Adedara, S. Vaithinathan, R. Jubendradass, P. P. Mathur, and E. O. Farombi, "Kolaviron Prevents Carbendazim-Induced Steroidogenic Dysfunction and Apoptosis in Testes of Rats," *Environmental Toxicology and Pharmacology* 35, no. 3 (2013): 444–453.

[100] A. Oyagbemi, D. Bester, J. Esterhuyse, and E. Farombi, "Kolaviron, A Biflavonoid of *Garcinia kola* Seed Mitigates Ischemic/Reperfusion Injury by Modulation of pro-Survival and Apoptotic Signaling Pathways," *Journal of Intercultural Ethnopharmacology* 6, no. 1 (2017): 42–49.

[101] O. Farombi, I. Adedara, and S. Abarikwu, "O27 Chemopreventive Activities of Kolaviron, A Novel Bioflavonoid From the Seed of *Garcinia kola*: Mechanistic Perspectives," *Biochemical Pharmacology* 139 (2017): 118.

[102] P. F. Surai, "Silymarin as a Natural Antioxidant: An Overview of the Current Evidence and Perspectives," *Antioxidants* 4, no. 1 (2015): 204–247.

[103] S.-H. Kim, G.-S. Choo, E.-S. Yoo, et al., "Silymarin Induces Inhibition of Growth and Apoptosis through Modulation of the MAPK Signaling Pathway in AGS Human Gastric Cancer Cells," *Oncology Reports* 42 (2019): 1904–1914.

[104] U. Sharma, P. K. Sahni, B. Sharma, et al., "Silymarin: A Promising Modulator of Apoptosis and Survival Signaling in Cancer," *Discover Oncology* 16, no. 1 (2025): 66.

[105] S. Ganbarjeddi, A. Azimi, M. Z. Heydarabad, et al., "Apoptosis Induced by Prednisolone Occurs Without Altering the Promoter Methylation of BAX and BCL-2 Genes in Acute Lymphoblastic Leukemia Cells CCRF-CEM," *Asian Pacific Journal of Cancer Prevention* 21, no. 2 (2020): 523–529.

[106] F. Ramadhani, S. Kang, R. Kawala, B. Chung, H.-W. Bai, and B. Kang, "γ-Irradiated Prednisolone Promotes Apoptosis of Liver Cancer Cells via Activation of Intrinsic Apoptosis Signaling Pathway," *Molecular Medicine Reports* 23, no. 6 (2021): 425.