World Inventia Publishers

Journal of Pharma Research
Available online through
www.jprinfo.com

JPR INFO
Journal of Pharma Research
USA CODEN: JPROK3

Vol. 05 Issue 12, 2016 ISSN: 2319-5622

Original Article

PHYTO CHEMICAL AND PHARMACOLOGICAL EVALUATION OF MENTHA ARVENSIS LEAVES EXTRACT ON THIOACETAMIDE-INDUCED LIVER DAMAGE IN RATS TO DETERMINE HEPATO-PROTECTIVE ACTIVITY

Dr. G. Nagaraju[1*], V.Sirisha[2], Kavati Ramakrishna[3], Dr. Hareesh Dara[1]

[1*]Department of Pharmaceutical Chemistry, Dhanvanthari Institute of PharmaceuticaL Sciences, Sujathanagar, Kothagudem.
[1]Department of Pharmaceutics, SREE COLLEGE OF PHARMAY, NAYAKULAGUDEM, Kothagudem,Telangana.
[2]Department of Pharmaceutics, Dhanvanthari Institute of Pharmaceutical Sciences, Sujathanagar, Kothagudem.
[3]Department of Pharmaceutics, Pulipati Prasad college of pharmacy, Pulipati Prasad college of pharmaceutical sciences, khammam.

Received on: 22-11-2016 Revised and Accepted on: 31-12-2016

ABSTRACT

Experiments were designed to establish the hepatoprotective activity of Mentha Arvensis (EMAL) ethanolic Leaves extracts at different doses (100 and 200 mg/kg bw) against thioacetamide-induced liver damage in albino Wistar rats. Hepatotoxicity was assessed by evaluating the activity of liver-function marker enzymes such as aspartate transaminase, alanine transaminase, alkaline phosphatase and lactate dehydrogenase as well as antioxidant enzymes such as catalase, glutathione peroxidase, glutathione reductase, glutathione-S-transferase and reduced glutathione. Lipid peroxidation was measured as malonaldehyde, a thiobarbituric acid reactive substance. Liver histopathological changes were also evaluated. EMAL administration was found to markedly prevent the elevation of serum liver enzymes and conjugated dienes, and significantly increase hepatic levels of antioxidant markers. Histological findings also confirmed the EMAL protective effects on thioacetamide-induced hepatotoxicity. Thus, results from the present study demonstrate the antioxidant and hepatoprotective activity of EMAL, strongly suggesting that it could be used as a rich source of natural antioxidants.

Keywords: *Mentha Arvensis, Thioacetamide, Liver damage, Antioxidants, Lipid peroxidation, Hepato preventive effect*

INTRODUCTION

Plants and their derivatives have been utilized as medicines for thousands of years [1]. In recent times, there has been an upsurge of significance in the preventive potential of medicinal plants as antioxidants in scavenging free radical-induced tissue injury [2]. Even though synthetic antioxidants are readily available, they may cause genotoxicity and carcinogenicity at high concentrations [3, 4, and 5]. Nowadays more attention has been paid to the preventive effects of natural antioxidants against drug-induced toxicities since herbal medicines are considered as less toxic and free from side effects [6]. The liver has a remarkable ability to metabolize and aid in the excretion of xenobiotics. Nevertheless, it is susceptible to damage from a number of drugs and toxins. Plant-based hepatoprotective drugs are found to be effective against liver disorders due to their safety, efficacy and cost effectiveness. This caused a sharp rise in the use of medicinal plants in recent years [7, 8, 9].

Mentha Arvensis is a medicinal plant member of the Lamiaceae family well known for their therapeutic properties. M. Arvensis Leaves extract is widely used due to its medicinal properties such as antifungal activity [10], antibacterial [10, 11], antiparasitic [12], antifertility [13] and antitumor [14] activities. However, no comprehensive evidence has yet been documented for the hepatoprotective activity of M. Arvensis experimentally or clinically. The aim of this work was to study and gain insight on the biochemical effects and antioxidant profile exerted upon M. Arvensis crude Ethanolic extract (EMAL) administration to rats with thioacetamide (TAA)-induced liver damage. Our data

***Corresponding author:**
Dr. G. Nagaraju
Institute of Pharmaceutical Sciences, Sujathanagar, Kothagudem
Email: gdp413@gmail.com
DOI:

© 2012, JPR. All Rights Reserved

will provide information supporting the use of M. Arvensis-derived extracts as potent antioxidants against hepatotoxicity.

2. Materials and Methods

2.1. Chemicals and Reagents

Thioacetamide (TAA) was purchased from Sigma-Aldrich (St. Louis, MO). Assay kits were purchased from Agappe Diagnostic, India. All other chemicals were of analytical grade.

2.2. Collection and preparation of plant extracts

M. Arvensis Leaves were collected from the Agricultural Centre, SVS University and authenticated. Leavess were cleaned, chopped, shade-dried and powdered. Dried powder (50g) was soxhlet extracted with2. 400 ml of ethanol for 48 h. Ethanolic extracts were concentrated under reduced pressure using a rotary evaporator and then kept under 4 ºC refrigeration.

2.3. Animals and diets

Male albino Wistar rats weighing 158 ± 6.3 gm (mean ± S.D, n = 30) were used in this study. Animals were housed in polypropylene cages, given standard rat chow (Sai Feeds, Hyderbad, India) and drinking water, and maintained under controlled temperature (26-28 ºC), with a 12 h light/12 h dark cycle. Animal studies were performed according to Institute of Animal Ethics Committee (IAEC) regulations approved by the Committee for the Purpose of Control and Supervision of Experiments on Animals (769/2011/CPCSEA)

2.4. Preparation of doses and treatments

TAA suspended in normal saline was administered at 100 mg/kg body weight (bw) subcutaneously (sc) to induce oxidative stress in rats [15]. Silymarin (Nupal drugs, India), at an oral dose of 100 mg/kg bw, was used as standard control in the experiment. Different doses (100 and 200 mg/kg bw) of EMAL was suspended in distilled water were also prepared for oral administration to the animals.

2.5. Experimental design – Preventive study

Animals were divided into five groups, with six rats in each of the groups, which were treated as follows:

Group I: Control rats (vehicle only)

Group II: Thioacetamide control (100 mg/kg bw, subcutaneous)

Group III: Thioacetamide (as in group II) + Silymarin (100 mg/kg bw, peritoneal)

Group IV: Thioacetamide (as in group II) + EMAL (100 mg/kg bw, peritoneal)

Group V: Thioacetamide (as in group II) + EMAL (200 mg/kg bw, peritoneal)

All groups except group I received a single dose of TAA on the ninth day of the experiment. Group III received Silymarin, and groups IV and V received EMAL, nine days before TAA challenge. Group I animals were used as vehicle controls, and received normal saline instead of drug and/or TAA. All animals were sacrificed 24 h after TAA administration.

2.6. Estimation of marker enzymes

Hepatotoxicity was assessed by quantifying the serum levels of aspartate transaminase (AST) (EC.2.6.1.1), alanine transaminase (ALT) (EC.2.6.1.2), alkaline phosphatase (ALP) (EC.3.1.3.10) and lactate dehydrogenase (LDH) (EC.1.1.1.27) by a kinetic method using a kit from Agape Diagnostic Ltd., India. Activities of these serum enzymes were measured by using a semi-autoanalyser (RMS, India).

2.7 Tissue analysis

Livers were excised and washed thoroughly in ice cold saline. Ten percent of the livers weight were used to prepare homogenates in 0.1 M Tris-HCl buffer (pH 7.4). The homogenates were centrifuged at 3000 rpm for 20 min at 4oC, and the supernatant was used for the estimation of catalase (CAT), glutathione peroxidase (GPx), glutathione reductase (GR), glutathione-S-transferase (GST), reduced glutathione (GSH) lipid peroxidation (as thiobarbituric acid reactive substance, TBARS) and conjugated dienes (CD).

Tissue CAT (EC.1.11.1.60) activity was determined from the rate of decomposition of H2O2 [16]. GPx (EC 1.11.1.9) activity was determined by measuring the decrease in GSH content after incubating the sample in the presence of H2O2 and NaN3[17]. GR (EC 1.6.4.2) activity was assayed at 37oC by following the oxidation of NADPH by GSSG at 340 nm [18]. GST (EC 2.5.1.18) activity was determined from the rate of increase in conjugate formation between reduced glutathione (GSH) and 1-chloro-2,4-dinitro benzene (CDNB) [19]. GSH was determined on the basis of the formation of yellow colored complexes with 5,5-Dithiobis (2-nitrobenzoic acid) DTNB [20]. The level of lipid peroxidation was measured as malondialdehyde (MDA), a thiobarbituric acid reacting substance (TBARS), using 1'1'3'3' tetramethoxypropane as standard [15]. Protein content in the tissue was determined using bovine serum albumin (BSA) as the standard [21].

2.8. Histopathological analysis

Small pieces of liver tissues were fixed in 10% buffered formalin and processed for embedding in paraffin. Sections of 5-6 µm were cut and stained with hematoxylin and eosin and examined for histopathological changes under the microscope (Motic AE 21, Germany) by taking microphotographs using a Moticam 1000 camera at the original magnification of 100X. Liver sections were graded numerically to assess the degree of histological features in acute hepatic injury. Centrilobular necrosis is the necrosis around the central vein characterized by the prominent ballooning, swollen granular cytoplasm with fading nuclei.

© 2012, JPR. All Rights Reserved

Bridging hepatic necrosis is a form of confluent necrosis of liver cells linking central veins to portal tracts or portal tracts to one another [22].

2.9 Statistical analysis

The results of the analysis were expressed as mean ± SD and all statistical comparisons were made using one-way ANOVA tests followed by Turkey's post hoc analysis, and P-values over than or equal to 0.05 were considered significant.

3. Results

3.1 Preventive effect of EMAL as shown by the measurement of serum biochemical parameters

Rats administrated with TAA showed elevated levels of serum AST, ALT, ALP and lipid peroxides. Treatment with EMAL at doses of 100 and 200 mg/kg significantly ($p \leq 0.05$) protected the animals from TAA induced hepatotoxicity. Standard drug Silymarin also showed a remarkable protection towards TAA administration. Treatment with 100 mg/kg bw of EMAL and Silymarin caused a protection reduction of 92.9% and 83.1% AST, 86.6% and 76.6% of ALT, 88.7% and 75.7% of ALP, 90% and 82.3% of LDH levels respectively (Table 1)

Table 1: Preventive effects of EMAL on changes in serum enzyme levels of rats treated with TAA. Values are mean ± SD, n = 6 animals. † p ≤ 0.05 vs. normal control. *p ≤ 0.05 vs. TAA control.

GROUPS	AST (IU/L)	ALT (IU/L)	ALP (IU/L)	LDH (IU/L)
(Group-I) Normal control	187 ± 0.16	74 ± 0.05	376 ± 0.62	1336 ± 0.06
(Group-II) TAA (100 mg/kg bw)	401 ± 0.53†	164 ± 0.03†	483 ± 0.63†	2536 ± 0.03†
(Group-III) Silymarin (100 mg/kg, *sc)* + TAA	223 ± 0.43*	95 ± 0.07*	402 ± 0.09*	1548 ± 0.06*
(Group-IV) EMAL (100 mg/kg bw) + TAA	202 ± 0.36*	86 ± 0.05*	388 ± 0.06*	1456 ± 0.05*
(Group-V) EMAL (200 mg/kg bw) + TAA	219 ± 0.85*	92 ± 0.07*	419 ± 0.05*	1687 ± 0.03*

Table 2: Preventive effects of EMAL against TAA induced Changes in the liver antioxidant Status. Values are mean ± SD, n = 6 animals. † p ≤ 0.05 vs. normal control. *p ≤ 0.05 vs. TAA control

GROUPS	GSH (nmol/mg protein)	SOD (enzyme required for 50% inhibition of NBT reduction)	GR (nmol of GSSG utilized/min /mg protein)	GPx (nmol of GSH oxidized/min /mg protein)	CAT (U/mg protein)	MDA (mmol/g tissue)
(Group-I) Normal control	29.6 ± 0.32	8.65 ± 0.62	23.43 ± 0.52	36.51 ± 5.26	35.32 ± 3.45	56.53 ± 5.38
(Group-II) TAA (100 mg/kg bw)	11.8 ± 0.65†	2.23 ± 0.70†	4.83 ± 0.61†	18.32 ± 2.31†	18.42 ± 5.60†	78.43± 7.72 †
(Group-III) Silymarin (100 mg/kg, *sc)* + TAA	23.6 ± 0.58*	5.49 ± 0.73*	16.92 ± 0.56*	29.84 ± 2.32*	28.49 ± 2.65*	46.12 ± 6.38 *
(Group-IV) EMAL (100 mg/kg bw) + TAA	26.4 ± 0.66*	6.96± 0.75*	22.25 ± 0.76*	34.15 ± 1.86*	32.42 ± 9.43*	54.26 ± 5.62 *

© 2012, JPR. All Rights Reserved

3.2. Preventive effect of EMAL as shown by measurement of liver antioxidant parameters

Table 2 shows the effect of EMAL on liver antioxidant status. The activities of enzymatic antioxidants GR, GPx, SOD, CAT and non-enzymatic antioxidant GSH were measured. The activities of enzymatic and the levels of non-enzymatic antioxidants were significantly ($p \leq 0.05$) decreased in rats treated with TAA alone. Administration of 100 mg/kg bw of EMAL and Silymarin significantly increased GR to 93.6% and 65%, GPx to 87% and 63.3%, GSH to 83.1% and 66.2%, SOD to 73.6% and 50.7%, and CAT to 82.8% and 67.5%. Among the two doses of EMAL, 100 mg/kg bw showed maximum enhancing effect, which was almost comparable to those detected in the normal control and Silymarin-treated animals (Table 2).

3. 3. Histopathological analysis

Histopathological examination of liver sections of normal animals showed normal cellular architecture with distinct hepatic cells, sinusoidal spaces and a central vein (Fig. 1A). The liver sections from the rats of TAA control group showed disarrangement of normal hepatic cells with high degree of damage, characterized by the centrilobular necrosis, focal necrosis and bile duct proliferation (Fig. 1B). The sections from the rats treated with the EMAL (100 and 200 mg/kg bw) and intoxicated with TAA exhibited less centrilobular necrosis and bile duct proliferation compared to the TAA control (Fig. 1C and 1D). 5. EMAL at 100 mg/kg bw showed better activity than at the higher 200 mg/kg bw dose. However, the use of standard Silymarin at 100 mg/kg bw on animals intoxicatedwith TAA resulted in slight centrilobular fatty changes, necrosis and bile duct proliferation, indicating its mild toxicity (Fig. 1E).

A

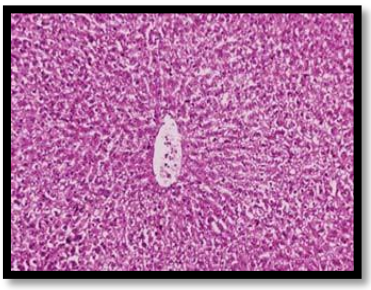

B

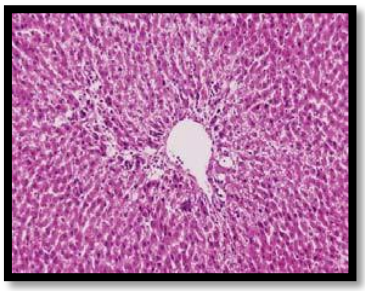

C

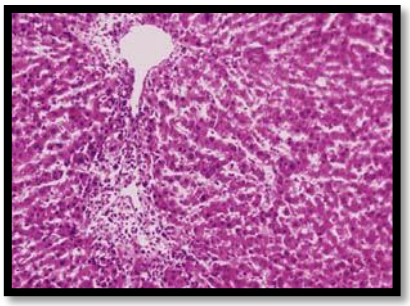

D

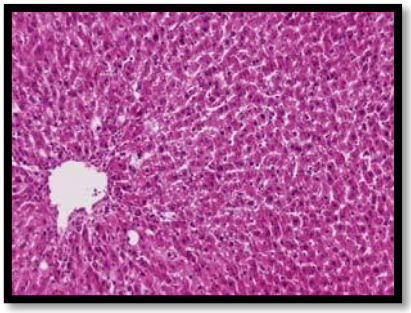

E

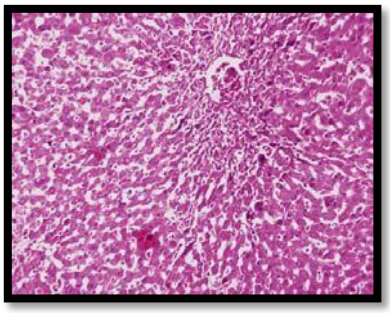

Fig 1: Histopathological changes occurred in the liver of post treatment groups after TAA intoxication and recovery by the treatment with EMAL. (Hematoxylin and eosin staining, 100×). (A) Normal control; (B) TAA control (100 mg/kg, sc); 6. (C) Silymarin (100 mg/kg bw + TAA); (D) EMAL (100 mg/kg bw + TAA); (E) EMAL 200 mg/kg bw + TAA).

4. DISCUSSION

Natural compounds that diminish free radical formation might be good candidates for the treatment of oxidative damage in cells and tissues. The formation of free radicals may contribute to oxidative damage, resulting in acute hepatitis [23]. TAA has been widely used to induce hepatotoxicity in experimental animals due to its ability to form a toxic reactive intermediate called thioacetamide s-oxide through metabolic activation by cytochrome P-450 enzymes in liver microsomes, which is accompanied by elevated levels of liver enzymes that are released into the blood stream [24]. One of the most notable

© 2012, JPR. All Rights Reserved

signs of TAA administration is hepatotoxicity. The goal of this study was to investigate the role of EMAL extract on liver injury produced after TAA-administration to male albino Wistar rats. Results showed that administration of TAA significantly ($p \leq 0.05$) elevated the levels of ALT, AST, ALP and LDH in the animals, leading to the leakage of enzymes to the blood circulation. Administration of EMAL ahead of TAA reduced the elevated enzyme levels in serum plasma resulting from the stabilization of three enzymes, clearly showing a preventive effect of EMAL on TAA intoxication. Reduction in hepatic antioxidant levels is the main mechanism of TAA action. GSH, CAT, SOD, GR and GPx are considered as the first line of the cellular antioxidant defense system [25, 26]. Reduced levels of GSH have been associated with TAA-induced hepatitis and are closely correlated to the lipid peroxidation and disturbance of Ca2++ induced by toxic agents [27]. There is an observed boost in tissue GSH content in EMAL-treated group showing that EMAL tends to reverse the tissue depletion of GSH in hepatic tissues. Our findings also show that EMAL stabilizes the GR activity levels in hepatic tissues, which demonstrate the role of EMAL in the recovery of the levels of GSH in tissues, as GR is critical to maintain GSH levels [28]. EMAL causes a significant ($p \leq 0.05$) increase in hepatic SOD and CAT activities and, thus, diminishes the oxidative injury in the liver due to the free radical establishment by the action of TAA.

Lipid peroxidation is considered as one of the important characteristics of oxidative stress [29, 30, 31]. Rats treated with TAA showed significantly ($p \leq 0.05$) elevated levels of lipid peroxidation (LPO), which is characterized by increase in the levels of TBARS and CD resulted in the failure of the antioxidant defense mechanism [32]. There was a decrease in the levels of TBARS and CD in EMAL-treated rats previously to their intoxication with TAA, showing that EMAL may exert a preventive action on hepatic tissue. Of the two doses of EMAL used in this study (100 mg/kg bw and 200 mg/kg bw), the lower concentration exhibited a more pronounced, significant ($p \leq 0.05$) effect, reverting the levels of most enzyme activities and antioxidant markers to almost those detected in normal controls.

Histopathological evaluation of liver sections from TAA treated rats revealed deep centrilobular necrosis while those from the animals previously treated with EMAL showed clear signs of the preventive action of EMAL against TAA-induced damage. Taken together, results from this study provide solid evidence indicating the efficacy of EMAL as a promising anti-hepatotoxic agent.

5. CONCLUSION

Results from this study demonstrate the hepatopreventive activity of Ethanolic Leaves extract of M. Arvensis in TAA-induced hepatoxicity, which is likely due to scavenging of free radicals by enhancing the activity of endogenous antioxidants. The antioxidant effects of the plant extract may be attributed to the presence in the extract of phytochemicals such as alkaloids and polyphenols, as we demonstrated earlier [33]. The biochemical parameters altered by TAA administration were reversed towards stabilization at near-normal levels by EMAL, and its effect was more prominent when using 100 mg/kg bw EMAL, when compared with Silymarin which was used as a positive control drug against TAA-induced hepatotoxicity. In order to further confirming the hepatoprotective action of EMAL, further studies and clinical trials are required, which are already ongoing in our laboratory.

Abbreviations:

AST	Aspartate transaminase
ALT	Alanine transaminase
ALP	Alkaline phosphatase
CD	Conjugated dienes
CDNB	1- Chloro-2, 4-dinitrobenzene
DTNB	5, 5-Dithobis-(2-nitrobenzoicacid)
GSH	Reduced glutathione
GPx	Glutathione peroxidase
GR	Glutathione reductase
GSSG	Oxidized glutathione
GST	Glutathione-S-transferase
MDA	Malonaldehyde
TBA	Thiobarbituric acid
TCA	Trichloroacetic acid
ROS	Reactive oxygen species

6. References

1. Lee KH. Novel antitumor agents from higher plants, Med Res Rev 1999; 19:569-596.

2. Schwartsmann G. Marine organisms and other novel natural sources of new cancer drugs, Ann Oncol 2000; 11:235- 243.

3. Mohamed Saleem TS, Madhusudhana Chetty C, Ramkanth S, Rajan VST, Mahesh Kumar K, Gauthaman K. Hepatoprotective herbs - A review. Int J Res Pharm Sci 2010; 1:1-5.

4. Stickel F, Schuppan D. Herbal medicine in the treatment of liver diseases. Dig Liver Dis 2007; 39:293-304.

5. Loguercio C, Federico A. Oxidative stress in viral alcoholic hepatitis, Free Radic Biol Med 2003; 34:1-10.

© 2012, JPR. All Rights Reserved

6. Vitaglione P, Morisco F, Caporaso N, Fogliano V. Dietary antioxidant compounds and liver health. Crit Rev Food Sci Nutr 2004; 44:575-586.

7. De Smet PA. Herbal remedies. N Engl J Med 2002; 347: 2046-2056.

8. Kessler RC, Davis RB, Foster DF, Van Rompay MI, Walters EE, Wilkey SA, Kaptchuk TJ, Eisenberg DM. Long-term trends in the use of complementary and alternative medical therapies in the United States. Ann Intern Med 2001; 135:262-268.

9. Flora KD, Rosen HR, Brenner KG. The use of naturopathic remedies for chronic liver disease. Am J Gastroenterol 1996; 91: 2654-2655.

11. Valsaraj R, Pushpangadan P, Smitt UW, Andersen A, Nyman U. Antimicrobial screening of selected medicinal plants from India. J Ethnopharmacol 1997; 58:75-83.

12. Niehaus WG, Samuelsson B. Formation of malonaldehyde from phospholipid arachidonate during microsomal lipid peroxidation. Eur J Biochem 1968; 6:126-130.

13. Beers RF Jr, Sizer IW. A spectrophotometric method for measuring the breakdown of hydrogen peroxide by catalase. J Biol Chem 1952; 195:133-140.

14. Rotruck JT, Pope AL, Ganther HE, Swanson AB, Hafeman DG, Hoekstra WG. Selenium: Biochemical role as a component of glutathione peroxidase. Science 1973; 179:588–590.

15. Beutler E. Red cell metabolism: A manual of biochemical methods. 3rd Edition, Willey, New York 1984; 73:120-126.

16. Habig WH, Pabst MJ, Jakoby WB. Glutathione S-transferase. The first enzymatic step in mercapturic acid formation J Biol Chem 1974; 249: 7130-7139.

17. Ellman GL. Tissue sulfhydryl groups. Arch BiochemBiophys 1959; 82:70-77.

18. Lowry OH, Rosebrough NJ, Farr AL, Randall RJ. Protein measurements with the Folin phenol reagent. J Biol Chem 1951; 193: 265-275.

19. Lefkowitch JH. Pathologic diagnosis of liver diseases. In: Zakim D, Boyer TD: Hepatology. (Ed 3) Philadelphia: WB Saunders, 1996, 844-874.

20. Pradeep HA, Khan S, Ravikumar K, Ahmed MF, Rao MS, Kiranmai M, Reddy DS, Ahamed SR, Ibrahim M. Hepatoprotective evaluation of Anogeissus latifolia: in vitro and in vivo studies. World J Gastroenterol 2009; 15:4816-4822.

21. Masella R, Di Benedetto R, Vari R, Filesi C, Giovannini C. Novel mechanisms of natural antioxidant compounds in biological system: involvement of glutathione-related enzymes, J Nutr Biochem 2005; 16:577-586.

22. Shapiro H, Ashkenazi M, Weizman N, Shahmurov M, Aeed H, Bruck R. Curcumin ameliorates acute thioacetamide-induced hepatotoxicity. J Gastroenterol Hepatol 2006; 21: 358-366.

23. Rahman TM, Hodgson HJ. Animal models of acute hepatic failure. Int J Exp Pathol 2000; 81:145-157.

24. Noctor G, Foyer CH. Ascorbate and glutathione: Keeping active oxygen under control. Annu Rev Plant Physiol Plant Mol Biol 1998; 49:249-279.

25. Kyle ME, Nakae D, Saikaida S, Serroni A, Farber JL. Protein thiol depletion and the killing of cultured hepatocytes by hydrogen peroxide. BiochemPharmacol 1989; 38:3797-3805.

26. Ansil PN, Nitha A, Prabha SP, Wills PJ, Jazaira V, Latha MS. Protective effect of Amorphophallus campanulatus (Roxb.) Blume.tuber against thioacetamide induced oxidative stress in rats. Asian Pac J Trop Med 2011; 4:870-877.

27. Sinclair AJ, Barnett AH, Lunec J. Free radicals and antioxidant systems in health and disease. Br J Hosp Med 1990; 43:334-344.

28. Thirumalai T, David E, Viviyan Therasa S, Elumalai EK. Restorative effect of Eclipta alba in CCl4 induced hepatotoxicity in male albino rats. Asian Pac J Trop Dis 2011; 1:304-307.

29. Comporti M. Lipid peroxidation and cellular damage in toxic liver injury. Lab Invest 1985; 53: 599-603.

How to cite this article:
Dr. G. Nagaraju *, PHYTO CHEMICAL AND PHARMACOLOGICAL EVALUATION OF MENTHA ARVENSIS LEAVES EXTRACT ON THIOACETAMIDE-INDUCED LIVER DAMAGE IN RATS TO DETERMINE HEPATO-PROTECTIVE ACTIVITY Pharma Res, 2016; 05(12): 298-303. DOI:

Conflict of interest: The authors have declared that no conflict of interest exists.
Source of support: Nil

© 2012, JPR. All Rights Reserved