International Journal of Medical and Pharmaceutical Sciences
Open access peer-reviewed Journal
Volume 1, Issue 12, Page 62-70.
https://doi.org/10.5281/zenodo.17960279

Research Article

Evaluation of Nephroprotective Activity of Gossypin against Gentamycin Induced Kidney Damage in Rat Model

Sujata Shivasharan[1], Shravankumar Suresh Kolli*[2]

[1]*Department of Pharmacology, Aryan College of Pharmacy Gulbarga*
[2]*Department of In-vivo Pharmacology, Syngene International Ltd Bengaluru*

Background and objective: Gossypin, isolated from Hibiscus vitifolius, is used to treat various diseases. In the present study, gossypin was evaluated for nephroprotective activity against gentamicin-induced kidney damage in rats. **Materials and methods:** The nephroprotective activity of gossypin was evaluated in gentamicin-induced nephrotoxicity in rats by measuring the levels of biochemical enzymes in serum and tissue homogenates, urine analysis, and histopathology studies. **Results:** Gossypin at 5 mg/kg and 10 mg/kg doses and selenium 2 mg/kg showed nephroprotective activity against gentamicin-induced nephrotoxicity in rats by significantly decreasing the biochemical enzymes such as lipid peroxidase (LPO) ($p<0.05$), superoxide dismutase ($p<0.05$), catalase ($p<0.001$), glutathione ($p<0.05$), creatinine ($p<0.01$), blood urea nitrogen (BUN) ($p<0.01$), and uric acid ($p<0.05$) levels in urine and serum as compared to the control group. Furthermore, this protection is supported by histopathological findings. **Conclusions:** Gossypin possesses significant nephroprotective activity against gentamicin-induced nephrotoxicity in rats.

Keywords: Nephrotoxicity, Hibiscus vitifolius, Biochemical Estimation, Histopathologiocal findings.

INTRODUCTION

Nephrotoxicity can be defined as renal disease or dysfunction that arises as a direct or indirect result of exposure to medicines and industrial or environmental chemicals. Several environmental contaminants, chemicals, and drugs, including antibiotics, dramatically alter the structure and function of various tissues and produce multiple adverse effects in the liver, kidney, heart, and intestine[1]. Several drugs and antibiotics, including penicillins, cephalosporins, tetracycline, sulfonamides, and amino glycosides, are known to be potential nephrotoxins. Aminoglycoside antibiotics are frequently used to treat severe abdominal and urinary tract[2]. Gentamicin (GM) is still considered to be an important aminoglycoside antibiotic used to treat life-threatening bacterial infections. However, nephrotoxicity and ototoxicity remain major problems for its effective long-term clinical use[3]. GM is known to cause a number of morphological, metabolic, and functional alterations in the kidney, and the specificity of GM nephrotoxicity is apparently related to its accumulation in the renal proximal convoluted tubules, leading to tubular necrosis[4]. The kidneys are dynamic organs that represent the major control system for maintaining body homeostasis, that is, water and electrolyte balance. Although they comprise less than 1% of the total body mass, they receive approximately 20% of the resting cardiac output.

Role of Nephron Heterogeneity in Nephrotoxicity

A number of normal biochemical and physiological patterns can be identified that make the kidney cells, compared with those of other organs, especially susceptible to ischemic or toxic insults. The major activity of the epithelial cells of the nephrons (uriniferous tubules), the functional units of the kidney, is the reabsorption of Na+ from the blood plasma filtrate produced in the renal glomeruli. This

process represents the driving force for the reabsorption of water and the coupled uptake of organic solutes, such as sugars and amino acids. Sodium reabsorption against an electrochemical gradient is active and mediated by the basolaterally localized Na,K-ATPase, a pump fueled by cellular adenosine triphosphate (ATP) derived predominantly from the oxidative metabolism of epithelial cell[5].The linear correlation between renal oxygen consumption and Na+ reabsorption is generally assumed to result from direct coupling between energy-providing metabolism and energy-consuming transport processes, as illustrated by the morphological layout of renal epithelial cells along the various nephron segments[6].

Gentamycin:

Gentamicin (GM) is widely used as a bactericidal agent for the treatment of severe infections caused by gram-negative bacteria, such as *Pseudomonas aeruginosa*. Its antibacterial activity is due to the irreversible inhibition of bacterial protein synthesis. However, the clinical use of aminoglycosides, such as GM, is limited by their ototoxicity and nephrotoxicity. The mechanisms underlying nephrotoxicity have been extensively investigated; however, the mechanisms by which these drugs induce cellular malfunction and necrosis remain unclear. The accurate localization of GM in cells and tissues can contribute to this effort. Previously, subcellular fractionation, micropuncture techniques, and autoradiography using radioactively labeled aminoglycosides were used to study the mechanisms of nephrotoxity[7].

Molecular Mechanisms of Aminoglycoside-Induced Apoptosis

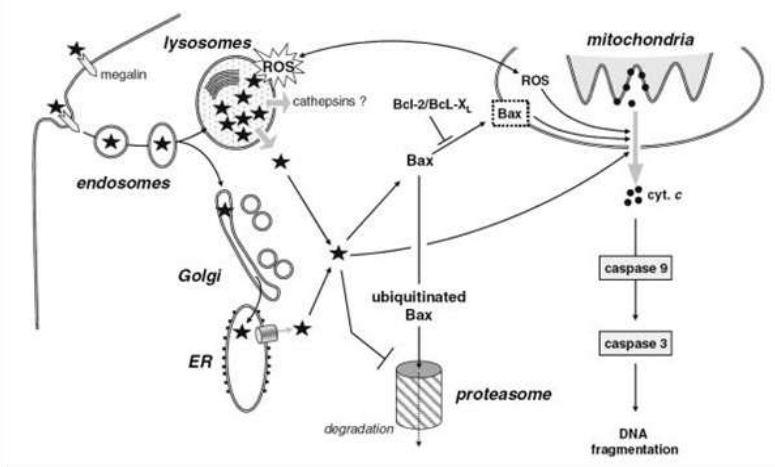

Figure 1: Mechanisms of Aminoglycoside-Induced Apoptosis

Antibiotics are taken up into cells by receptor-mediated endocytosis (via megalin and, probably, negatively charged phospholipids) and accumulate in lysosomes, where they cause phospholipidosis. However, a small amount released from lysosomes to the cytosol (by membrane destabilization) or reaching the cytosol by retrograde traffic triggers apoptotic signals that will casue the activate caspases. These signals could be direct (activation of Bax and subsequent release of cytochrome c from mitochondria) or indirect (inhibition of the proteasome, causing an increase in ubiquitinylated Bax protein). Current studies have also examined the role of reactive oxygen species (ROS) in this process[8].

- **A Brief Review of Literature on Gossypin and Its Uses:**

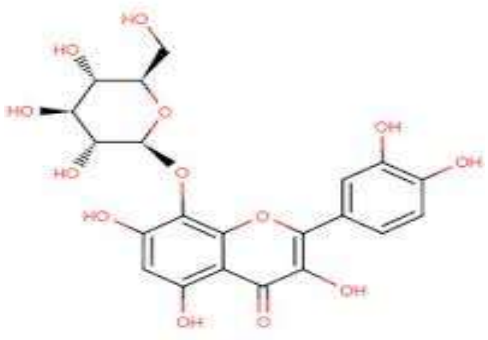

Figure 2: Gossypin

Gossypin was isolated from *Hibiscus vitifolius*. The yellow part of the petals of *Hibiscus vitifolius* (Malvaceae family) (1.5 g) was extracted with methanol for 3–4 h, concentrated to a small volume under vacuum, and kept in a refrigerator for 24 h. A large amount of yellow solid was separated, filtered, and washed with methanol. The yellow solid had a melting point of 228-230OC. Based on the spectral data (UV, IR, NMR and Mass), the compound was identified as gossypin. The flavonoid gossypin has been reported to exhibit anti-inflammatory activity by inhibiting arachidonic acid metabolism [9,10]. Gossypin significantly reduces the effect of paw edema and increased vascular permeability induced by histamine, 5-HT, bradykinin[11,12] and Prostaglandin-E[13]. Gossypin has also been shown to possess anti-hyaluronidase activity Antinoceptive ativity of gossypin was also reported[12].

MATERIAL AND METHODS

Chemicals and drugs: 2-Thiobarbituric acid (TBA), trichloroacetic acid (TCA), 5, 5'-Dithiobis-2-nitrobenzoic acid (DTNB), and Griess reagent were obtained from Sigma-Aldrich Corporation (St. Louis, MO, USA), Uric acid, blood urea nitrogen (BUN), creatinine (ERBA Diagnostics Mannheim GmbH), standard selenium, and gentamicin (Kopran Laboratories Pvt. Ltd) were measured. Mumbai). All other reagents and solvents used in the experiment were of analytical grade. Refrigerator centrifuge (MPW-350R), UV- Spectrophotometer (UV-1601, Shimadzu Corporation, Kyoto, Japan).

Animals: Wistar-Albino rats of either sex (200–250 g) were obtained from the central animal house of H. S. K. College of Pharmacy and Research Centre, Bagalkot. The animals were housed at room temperature (22-28○˚C) with 65 ± 10% relative humidity for 12 h dark and light cycles and given standard laboratory feed (Amruth, Sangli, Maharashtra) and water ad libitum. The study was approved and conducted as per the norms of the Institutional Animal Ethics Committee.

Disease induction in Rats: Wistar albino rats will be assigned to five groups, each containing six rats. Nephrotoxicity was induced by intraperitoneal administration of gentamicin (100 mg/kg/day) for eight days in the standard and treated groups. Selenium (2 mg/kg) and gossypin were administered for eight days with gentamicin. On the 8th day, rats were placed in separate metabolic cages for 24 h for urine collection to determine urine output and creatinine content. Blood will be collected via retro-orbital puncture to estimate the serum creatinine and blood urea nitrogen (BUN) levels. Changes in body weight will be recorded, and the kidneys will be weighed and processed for histopathological estimation[14].

 Experimental Design.

Group I- Normal group, receives only normal saline, (n= 6)

Group II - Control group, receives gentamicin (100mg/kg) and normal saline orally (n=6)

Group III - Effect of standard drug Selenium (2mg/kg) on gentamicin (100mg/kg) induced nephrotoxicity in rats, (n=6)

Group IV - Effect of low dose of Gossypin (5mg/kg) on gentamicin (100mg/kg) induced nephrotoxicity in rats, (n=6)

Group V: Effect of high dose of gossypin (10 mg/kg) on gentamicin (100 mg/kg)-induced nephrotoxicity in rats (n=6).

Nephroprotective activity

Collection and analysis of urine samples: All animals will be kept in individual metabolic cages, and urine samples of 24h will be collected on the 8th day of gentamicin injection. The animals had free access to drinking water during the urine collection period. Urine will be analyzed for creatinine[15], uric acid[16], and BUN[17].

Collection and analysis of serum samples: After the experimental period, blood samples were collected from the retro-orbital plexus under light ether anesthesia in centrifuged tubes and centrifuged at 3000x g for 10 min to obtain serum. The resulting serum was collected, properly labeled, and analyzed immediately for creatinine[15], uricacid[16], BUN[17] using kits. (ERBA Diagnostics, Mannheim) using a star-21 plus semi auto analyzer.

Kidney homogenate analysis: On the 8th day, the animals were sacrificed by cervical decapitation or chloroform. The abdomen was opened to remove both kidneys, which were washed in 0.9% cooled saline and kept on ice. One kidney was stored in 10% formalin for histopathology. Another sample was homogenized in cold phosphate buffer (0.1M, pH). The homogenates were centrifuged at 10000 rpm for 10 minutes at 4C (MPW-350R, Korea), and the post-mitochondrial supernatant (PMS) was used to estimate the total protein and lipid peroxidation. Another part of the homogenized supernatant was centrifuged at 17000 rpm for 1h at 4C. The supernatant obtained was used for further estimation of SOD, CAT, and GSH.

RESULTS AND DISCUSSION:

Biochemical levels of gentamicin-induced nephrotoxicity:

- **Effect of Gossypin on Urinary Creatinine Levels:**

A significant ($p<0.01$) increase in creatinine levels in urine was observed in gentamicin-treated groups compared to normal groups. The groups treated with gossypin showed a significant reduction in urine creatinine at 5 and 10 mg/kg ($p < 0.01$). Similarly, standard Selenium-treated animals showed significantly ($p<0.05$) decreased levels of creatinine in urine activity against gentamicin-induced nephrotoxicity compared to the control (Selenium-treated) group. (Fig 3).

- **Effect of gossypin on BUN in urine samples:**

A significant ($p<0.05$) increase in BUN levels in urine was observed in gentamicin-treated groups compared to the normal groups. The groups treated with gossypin showed a significant reduction in the BUN level in urine at 5 and 10 mg/kg ($p < 0.01$). Similarly, standard selenium-treated animals showed a significant ($p<0.01$) decrease in the level of BUN in urine against gentamicin-induced nephrotoxicity compared to the control (Selenium-treated) group. (Fig 4).

- **Effect of Gossypin on Urinary Uric Acid Levels:**

A significant ($p<0.001$) increase in urine UA levels was observed in gentamicin-treated groups compared to normal groups. The groups treated with gossypin showed significant reduction in the urine UA level at 5 and 10 mg/kg ($p < 0.05$). Similarly, standard selenium-treated animals showed significantly ($p<0.001$) decreased levels of Uric Acid in urine activity against gentamicin-induced nephrotoxicity compared to the control (gentamicin-treated) group. (Fig 5).

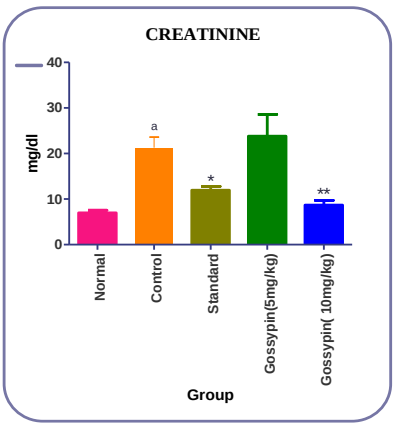

Figure 3: Creatinine

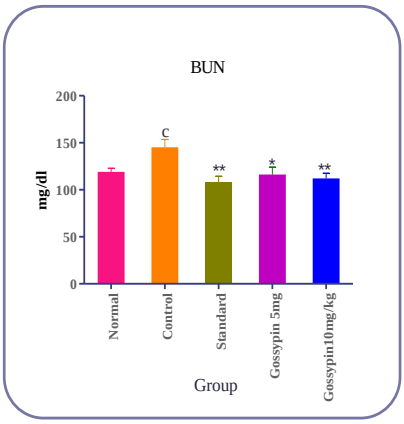

Figure 4: BUN

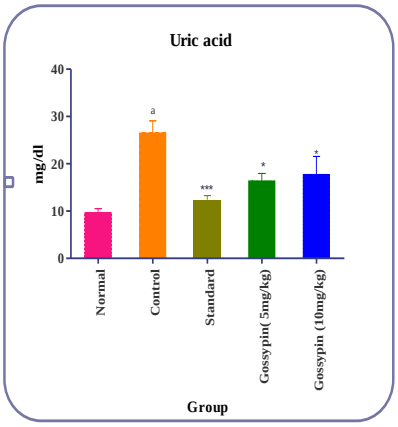

Figure 5: Uric Acid

All values are presented as mean ± SEM. One-way analysis of variance (ANOVA) followed by multiple *Dunnet't'- tests*. ap<0.001 compared with the normal group and ***p<0.001 and *p<0.05 compared with the control group.

- **Effect of gossypin on creatinine levels in the blood serum:**

A significant (p<0.001) increase in blood creatinine levels was observed in the gentamicin-treated groups compared to the normal groups. The groups treated with gossypin showed a significant reduction in blood creatinine levels at 5 and 10 mg/kg (p < 0.01). Similarly, standard selenium showed significant (p<0.001) decreased levels of Serum Creatinine activity against gentamicin-induced nephrotoxicity compared to the control (gentamicin-treated) group. (Fig6).

- **Effect of Gossypin on BUN in Blood:**

A significant (p<0.001) increase in BUN levels was observed in the gentamicin-treated groups compared to the normal groups. The groups treated with gossypin showed a significant reduction in BUN at 5 and 10 mg/kg (p < 0.01). Similarly, standard Selenium showed significant (p<0.05) decreased levels of Serum ALP activity against Gentamycin-induced Nephrototoxicity as compared to control (Gentamycin-treated) group. (Fig7).

- **Effect of Gossypin on Uric Acid in Blood:**

A significant (p<0.001) increased levels of uric acid in Blood was observed in Gentamycin treated groups as compared to normal groups. The groups treated with Gossypin showed significant at doses 5 and 10 mg/kg (p<0.01) reduction in the Uric Acid in Blood. Similarly, standard Selenium showed significant (p<0.01) decreased levels of Serum Uric Acid activity against Gentamycin-induced Nephrototoxicity as compared to control (Gentamycin-treated) group. (Fig8).

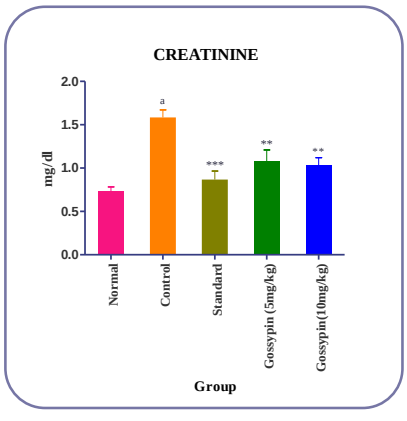

Figure 6: Creatinine

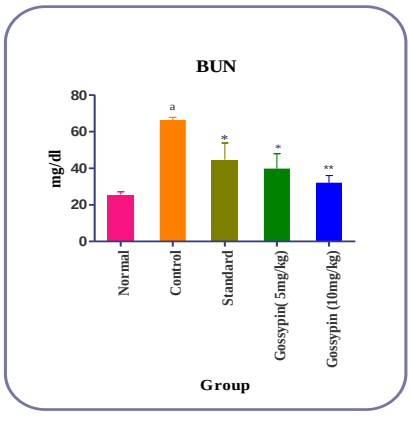

Figure 7: BUN

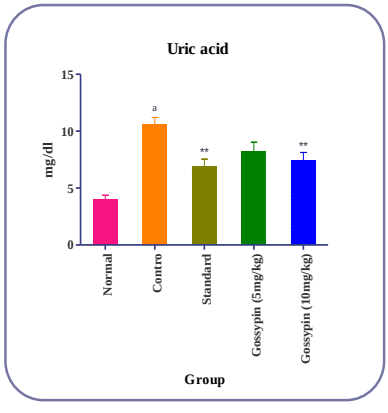

Figure 8: Uric Acid

All values were presented as a Mean ± SEM. One Way Analysis of variance (ANOVA) followed by multiple *Dunnet't'- test*. ap<0.001 as compared with the normal group and ***p<0.001 and *p<0.05, as compared with the control group.

Effect of gossypin on renal antioxidant enzymes (SOD, CAT, GSH) and lipid peroxidation (LPO) in gentamicin-induced Nephrotoxicity in rats.

SOD

A significant (p<0.05) increased levels of SOD was observed in Gentamycin treated groups as compared to normal groups. The groups treated with Gossypin showed significant at doses 5 and 10 mg/kg (p<0.05) reduction in the SOD in Blood. Similarly, standard Selenium showed significant (p<0.05) decreased levels of SOD activity against Gentamycin-induced Nephrototoxicity as compared to control (Gentamycin-treated) group. (Fig9).

CAT

A significant (p<0.001) increased levels of CAT was observed in Gentamycin treated groups as compared to normal groups. The groups treated with Gossypin showed significant at doses 5 and 10 mg/kg (p<0.001) reduction in the CAT. Similarly, standard Selenium showed significant (p<0.05) decreased levels of Serum CAT activity against Gentamycin-induced Nephrototoxicity as compared to control (Gentamycin-treated) group. (Fig10).

GSH

A significant (p<0.05) increased levels of GSH was observed in Gentamycin treated groups as compared to normal groups. The groups treated with Gossypin showed significant at doses 5 and 10 mg/kg (p<0.05) reduction in theGSH. Similarly, standard Selenium showed significant (p<0.01) decreased levels of GSH activity against Gentamycin-induced Nephrototoxicity as compared to control (Gentamycin-treated) group. (Fig11).

LPO

A significant (p<0.05) increased levels of LPO was observed in Gentamycin treated groups as compared to normal groups. The groups treated with Gossypin showed significant at doses 5 and 10 mg/kg (p<0.05) reduction in the LPO. Similarly, standard Selenium showed significant (p<0.05) decreased levels of LPO activity against Gentamycin-induced Nephrototoxicity as compared to control (Gentamycin-treated) group. (Fig12).

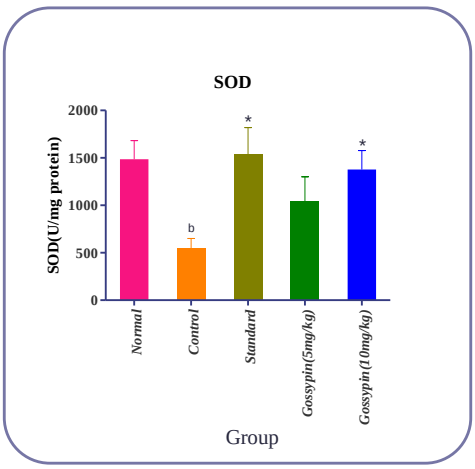

Figure 9: SOD

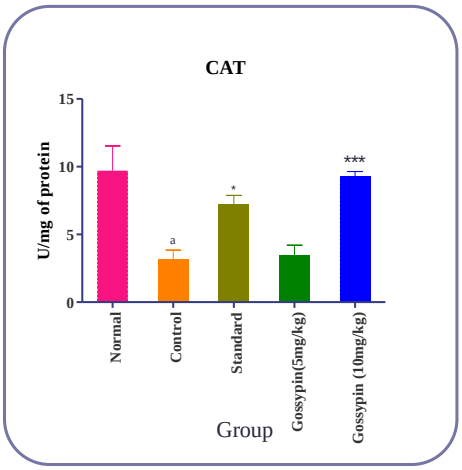

10: CAT

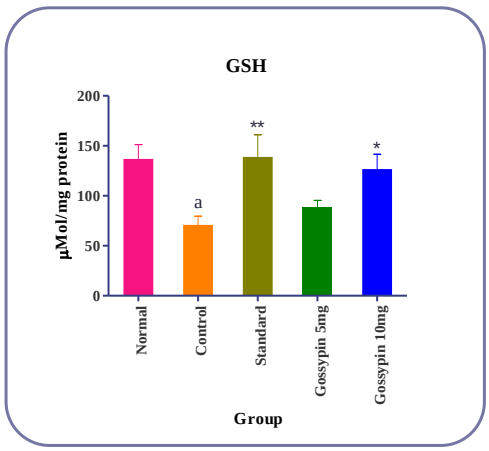

Figure 11: GSH

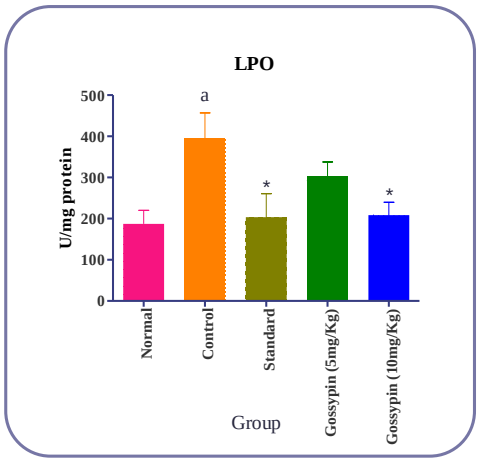

Figure 12: LPO

All values were presented as a Mean ± SEM. One Way Analysis of Variance (ANOVA) followed by multiple *Dunnet't'- test*. ap<0.001 as compared with the normal group and *p<0.05, as compared with the control group.

Effect of different doses of Gossypin on histopathology studies:

Histologically, normal group animals showed normal glomerular and renal tubular structure in normal group, the control group animals exhibited showed marked tubular necrosis, disconnected and degenerated epithelial tissues are visible in lumena of nephritic tubule and tubular dilation. Some of the epithelial tissue have large nuclei cytoplasm is swollen which result in edema. Standard selenium treated group, Gossypin 5mg/kg and, Gossypin 10mg/kg treated group showed normal renal tubule appearance less luminal debris and some disconnected cell were present and exhibited significant kidney protection against control group (Fig 6 and 6A).

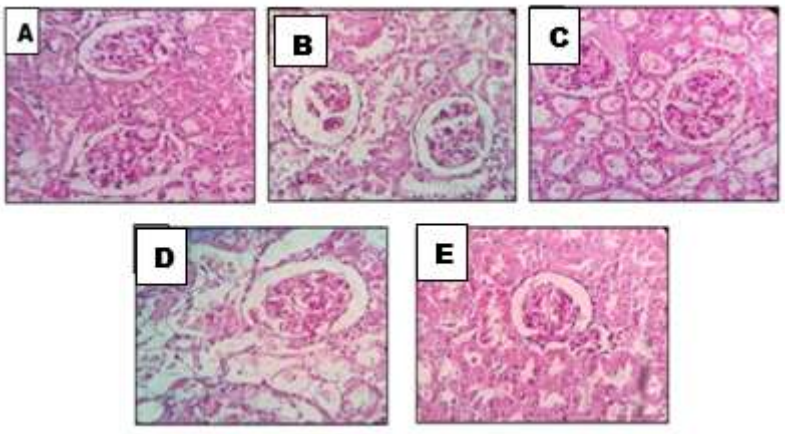

Figure 13: Histo-pathological Observations

Figure 13: Effect of different doses of Gossypin on gentamicin induced kidney damage in WA rats. 40 X magnified Photographs of kidney from different treatment groups stained with Haemotoxoline and Eosin. Plates; **A**: Normal group showed normal glomerular and renal tubular structure in normal group. **B**: Control group showed marked tubular necrosis, disconnected and degenerated epithelial tissues are visible in lumena of nephritic tubule and tubular dilation. Some of the epithelial tissue have large nuclei cytoplasm is swollen which result in edema. **C**: Standard selenium treated group **D**: Gossypin 5mg/kg treated and, **E**; Gossypin 10mg/kg treated group showed normal renal tubule appearance less luminal debris and some disconnected cell were present.

DISCUSSION

Gentamicin (GM) induced Nephrotoxicity is characterized by elevated levels of urea and creatinine in serum as well as urine, severe proximal tubular necrosis and renal failure[18]. Similar pattern of changes were also observed in our study following GM treatment. Gossypin 5 and 10mg/kg supplementation to GM treated rats recorded decrement in levels of urea and creatinine, BUN and uric acid in serum as well as urine. These observations indicate at an improved renal function in form of effective of creatinine BUN and uric acid. Decrement in activity levels of renal SOD and CAT following GM treatment are in accordance with previous report on GM induced suppression of endogenous enzymatic antioxidant machinery[19]. The Gossypin treatment efficiently prevented GM induced decrease in activity levels of SOD and CAT. Further Gossypin (5 and 10mg/kg) groups recorded significantly ($p<0.05$), ($p<0.01$) and ($p<0.001$) higher levels of GSH as compared to GM group, thus indicating that Gossypin. Treatment prevents GM induced depletion in levels of renal non-enzymatic antioxidants. Also, observed decrement in renal enzymatic and non-enzymatic antioxidants coupled with increment in LPO in GM treated rats are indicative of compromised antioxidant machinery and a higher susceptibility towards oxidative damage. However, Gossypin. Lowered LPO levels recorded in Gossypin (10mg/kg) treated groups that prevent membrane lipid peroxidation and subsequent depletion of enzymatic and non-enzymatic antioxidants during GM induced nephrotoxicity.

SUMMARY AND CONCLUSION:

The Nephroprotective activity was evaluated by using Gentamicin for 8 days study respectively, the administration Gentamicin significantly ($p<0.001$) increases in the levels of urine and serum creatinine, BUN, uric acid and similarly kidney homogenate LPO. However, administration of Gossypin 5 and, 10 mg/kg caused significantly decreased levels of urine and serum creatinine, BUN, uric acid and kidney homogenate. Further administration of Gentamicin caused significantly ($p<0.001$) decreased in the levels of SOD, CAT and GSH, when compare to normal group of rats. More over treatment with Gossypin. Significantly increased the levels of SOD, CAT, GSH when compare to control group of rats. These effects could contribute to the Nephroprotective property of Gentamycin. The Nephroprotective potential of Gossypin can be attributed to its Nephroprotective property.

REFERENCES

1. Kohn S, Fradis M, Robinson E, Iancu TC. Hepatotoxicity of combined treatment with cisplatin and gentamicin in the guinea pig. UltrastructPathol. 2005; 29: 129-137.
2. Nagai J, Takano M. Molecular aspects of renal handling of aminoglycosides and strategies for preventing the nephrotoxicity. Drug MetabPharmacokin. 2004; 19: 159-170.
3. Khan SA, Priyamvada S, Farooq N, Khan S, Wasim KM, Yusufi ANK. Protective effect of green tea extract on gentamicin-induced nephrotoxicity and oxidative damage in rat kidney. Pharmacol Res. 2009; 59: 254-262.
4. P edr a z a-Cha v e r ri J, Ma ldonado PD, Medina-Campos ON, Olivares-Corichi IM, Grandos-Silvestre M, Hernandez-Pando R, et al. Garlic ameliorates gentamicin nephrotoxicity: relation to antioxidants. Free RadicBiol Med 2000; 29: 602-611.
5. Soltoff SB. ATP and the regulation of renal cell function. Annu Rev Physiol 1986; 48:9-31
6. Walter P. Structure function correlation on rat kidney. Quantitative correlation of structure and function in the normal and acutely injured rat kidney. Adv Anat Embryol Cell Biol. 1982; 70:1-121.
7. Kunio F, Masashi S, Hayato M, Tetsuya S, and Lars-Inge L. Light-Microscopic Immunocytochemistry for Gentamicin and Its Use for Studying Uptake of the Drug in Kidney. Antimicrobial agents and chemotherapy. 2009; 53:3302-3307.
8. Servais H., Ortiz A, Devuyst O, Denamur S, Tulkens PM, Mingeot-Leclercq MP. Renal cell apoptosis induced by nephrotoxic drugs: cellular and molecular mechanisms and potential approaches to modulation. Apoptosis. 2008; 13:11-32.
9. Ferrandiz ML, Alearaz MJ. Anti-inflammatory activity and inhibition of arachidonic acid metabolism by flavonoids. Agents Actions. 1991; (32)283-288.

10. Dirosa M, Giroud JP, Wigloughby DA. Studies on the mediators of acute inflammatory response induced in rats in different sites by carrageenin and turpentine. J Path Bact. 1991; (104): 15-29.
11. Viswanathan S, Sabantham PT, Reddy K, Kameswaran L. Gossypin – induced analgesia in mice. Eur J Pharmacol. 1984; (98): 289-291.
12. Viswanathan S, Thirugnanasabantham P, Ramaswamy S, Bapna JS. A study on the role of cholinergic and gamma amino butyric acid systems in the anti-nociceptive effect of gossypin. Clin Exp. Pharmacol Physiol. 1993; (20):193-196.
13. Beiler JM, Martin GJ. Inhibitory action of vitamin P compounds on hyaluroni dose. J Biol Chem, 1947; (171): 507-571.
14. Reiman S, Frankel S. A colorimetric method for the determination of serum glutamic oxaloaceticandglutamic-pyruvic transaminases. Americ J of Clin Pathol.1957;28:56-63
15. Young DS. Effect of Drugs on Clinical Laboratory Tests. Third Edition 1990; 21:5.
16. Cameron GR, Karunarathe WAE. Carbon tetrachloride cirrhosis in relation to liver degeneration. J Path Bacteriol. 1936; 42:1.
17. Selvam R., Kalaiselvi P., Govindaraj A., Balamurugan V., Satish Kumar A. S. Effect of Arvalanata leaf extract and vediuppuchunnam on the urinary risk factors of calcium oxalate urolithiasis during experimental hyperoxaluria. Pharmacol Res. 2001; 43: 89-93
18. Karthikryan S. Hepatotoxicity of Isoniazid and Rifampacin: A study in the activity of marker enzymes of liver toxicity in serum and liver tissue of rabbits. Indian J Pharmacol. 2004; 36: 247-249.
19. Harlalka GV, Patil RC, Patil RM. Protective effect of Kalanchoe pinnata pers. (Crassulaceae) on gentamicin – induced nephrotoxicity in rats. Indian J Pharmacol. 2007; 39:201-205.

Cite: Sujata Shivasharan1, Shravankumar Suresh Kolli*, Evaluation of Nephroprotective Activity of Gossypin against Gentamycin Induced Kidney Damage in Rat Model, Int. J. Med. Pharm. Sci., 2025, 1 (12), 62-70. https://doi.org/10.5281/zenodo.17960279