INTERNATIONAL JOURNAL OF PHARMACEUTICAL SCIENCES
[ISSN: 0975-4725; CODEN(USA): IJPS00]
Journal Homepage: https://www.ijpsjournal.com

OPEN ACCESS

Research Paper

Evaluation of Hepatoprotective Activity of Silybum Marianum on Carbon Tetrachloride Induced Liver Damage in Rats

Yashkirti Vishwakarma*, Abhishek Shrivastava

Sagar Institute of Research and Technology – Pharmacy, Sanjeev Agrawal Global Educational University, Bhopal, Madhya Pradesh, India..

ARTICLE INFO

Published: 20 June 2026

Keywords:
Silybum marianum, hepatoprotective activity, carbon tetrachloride, liver injury, silymarin, antioxidant activity, Wistar rats

DOI:
10.5281/zenodo.20773099

ABSTRACT

The present study evaluated the hepatoprotective activity of the ethanolic extract of Silybum marianum against carbon tetrachloride (CCl_4)-induced liver damage in Wistar rats. The seeds were extracted using 70% ethanol and subjected to preliminary phytochemical screening, which confirmed the presence of flavonoids, phenols, tannins, saponins, glycosides, and steroids. Hepatotoxicity was induced by CCl_4 administration, and the extract was evaluated at doses of 100 and 200 mg/kg. Treatment with Silybum marianum significantly reduced elevated serum levels of ALT, AST, ALP, and bilirubin while restoring total protein levels. The extract also improved antioxidant status by increasing superoxide dismutase (SOD) and catalase (CAT) activities and reducing malondialdehyde (MDA) levels. Histopathological examination revealed marked restoration of normal hepatic architecture with reduced necrosis, steatosis, and inflammatory infiltration, particularly at the dose of 200 mg/kg. The hepatoprotective effects were comparable to those of the standard drug silymarin. The findings indicate that Silybum marianum possesses significant dose-dependent hepatoprotective and antioxidant activities, supporting its potential use in the management of liver disorders.

INTRODUCTION

The liver is a vital organ responsible for numerous physiological functions, including metabolism of carbohydrates, proteins, and lipids, detoxification of xenobiotics, synthesis of plasma proteins, and regulation of biochemical homeostasis. Owing to its central role in the metabolism of endogenous and exogenous compounds, the liver is highly susceptible to injury caused by drugs, chemicals, alcohol, and environmental toxins [1, 2]. Liver diseases constitute a major global health problem, and the search for effective hepatoprotective agents remains an important area of biomedical research [3, 4].Carbon tetrachloride (CCl_4) is one

***Corresponding Author:** Yashkirti Vishwakarma
Address: *1Sagar Institute of Research and Technology – Pharmacy, Sanjeev Agrawal Global Educational University, Bhopal, Madhya Pradesh, India.*
Email : hpworld1996@gmail.com

Relevant conflicts of interest/financial disclosures: The authors declare that the research was conducted in the absence of any commercial or financial relationships that could be construed as a potential conflict of interest.

of the most commonly used hepatotoxic agents for inducing experimental liver injury in laboratory animals. Following metabolic activation by the hepatic cytochrome P450 enzyme system, CCl_4 generates reactive free radicals, particularly trichloromethyl (CCl_3) and trichloromethyl peroxy ($OOCCl_3$) radicals. These radicals initiate lipid peroxidation, leading to oxidative stress, cellular membrane damage, inflammation, and hepatocellular necrosis [5,6]. Therefore, CCl_4-induced hepatotoxicity serves as a reliable experimental model for evaluating the efficacy of hepatoprotective compounds.

Oxidative stress is a key factor in the pathogenesis of liver injury. Excessive production of reactive oxygen species (ROS) overwhelms the body's antioxidant defense mechanisms, resulting in cellular damage and impaired liver function [7]. Consequently, natural antioxidants derived from medicinal plants have gained significant attention for their potential role in protecting the liver against oxidative damage [8].

Silybum marianum (Milk Thistle), a medicinal plant belonging to the family Asteraceae, has been traditionally used for the treatment of liver and biliary disorders for centuries[9, 10]. Its major bioactive constituent, silymarin, is a mixture of flavonolignans including silybin, silydianin, and silychristin. Silymarin possesses potent antioxidant, anti-inflammatory, membrane-stabilizing, and free radical scavenging properties, which contribute to its hepatoprotective effects [11,12,13]. Previous studies have demonstrated that silymarin can inhibit lipid peroxidation, enhance cellular antioxidant defenses, promote hepatocyte regeneration, and protect the liver against various toxic insults [14].

Therefore, the present study was undertaken to evaluate the hepatoprotective activity of *Silybum marianum* against carbon tetrachloride-induced liver damage in rats. The protective effect was assessed through biochemical and histopathological parameters to validate its potential as a natural hepatoprotective agent[15, 16].

MATERIALS AND METHODS:

Plant Material and Extraction

Dried seeds of *Silybum marianum* were procured from a reputed herbal supplier and authenticated by a qualified botanist. The seeds were cleaned, shade-dried, powdered, and subjected to Soxhlet extraction using 70% ethanol for 8 h. The extract was concentrated under reduced pressure using a rotary evaporator and stored at 4°C until use. Percentage yield was calculated based on the dry weight of the extract [17,18].

Phytochemical Screening

The ethanolic extract was screened qualitatively for major phytoconstituents such as flavonoids, alkaloids, tannins, phenolics, saponins, glycosides, and steroids using standard phytochemical tests described in the literature [19].

Experimental Animals and Ethical Approval

Healthy male Wistar rats (150–200 g) were obtained from a CPCSEA-approved animal facility and acclimatized for one week under standard laboratory conditions. The study protocol was approved by the Institutional Animal Ethics Committee (IAEC) and conducted according to CPCSEA guidelines [20,21].

Acute Oral Toxicity Study

Acute oral toxicity of the extract was evaluated according to OECD Guideline 423. Animals were observed for signs of toxicity and mortality for 14 days after administration. Based on the findings, doses of 100 and 200 mg/kg were selected for further studies [22].

Experimental Design

Table 1: Grouping of Animals for Antioxidant activity

Group	Treatment
I	Normal control
II	CCl_4 control (1 mL/kg, i.p.)
III	CCl_4 + Silymarin (100 mg/kg)
IV	CCl_4 + *S. marianum* extract (100 mg/kg)
V	CCl_4 + *S. marianum* extract (200 mg/kg)

Carbon tetrachloride (1:1 in olive oil) was administered intraperitoneally to induce hepatotoxicity, while treatments were given orally for 14 days [23].

Biochemical Analysis

Blood samples were collected at the end of the study, and serum was separated by centrifugation. Liver function markers including ALT, AST, ALP, total bilirubin, and total protein were estimated using standard diagnostic kits [24].

Estimation of Antioxidant Parameters

Liver tissues were homogenized in phosphate buffer (pH 7.4), centrifuged, and the supernatant was used for antioxidant assays [29].

Malondialdehyde (MDA)

MDA levels were determined using the TBARS method described by Ohkawa . Absorbance was measured at 532 nm, and results were expressed as nmol MDA/mg protein [30].

Superoxide Dismutase (SOD)

SOD activity was estimated by the Misra and Fridovich method based on inhibition of epinephrine auto-oxidation. Results were expressed as U/min/mg protein [31].

Catalase (CAT)

Catalase activity was measured according to Aebi's method by monitoring the decomposition of hydrogen peroxide at 240 nm and expressed as µmol H_2O_2 decomposed/min/mg protein [32].

Histopathological Evaluation

Liver tissues were fixed in 10% neutral buffered formalin, processed routinely, and stained with hematoxylin and eosin (H&E). Histological examination was performed to assess necrosis, inflammation, fatty changes, and hepatocellular degeneration [33].

Statistical Analysis

Results were expressed as mean ± SEM. Statistical significance was analyzed using one-way ANOVA followed by Tukey's post hoc test. Values of $p < 0.05$ were considered statistically significant [34].

RESULT AND DISCUSSION

Plant Material and Extraction

The seeds of *Silybum marianum* were procured from a reputed herbal supplier and authenticated by a qualified taxonomist. A voucher specimen was deposited in the departmental herbarium for future reference. The seeds were cleaned, shade-dried, powdered, and extracted using 70% ethanol in a Soxhlet apparatus for 8 hours. The extract was concentrated under reduced pressure using a rotary evaporator (40–50°C) and stored in an amber-colored container at 4°C until further use. The extraction process yielded a thick brownish semi-solid ethanolic extract with a percentage yield of 13.5% w/w. The obtained yield indicates efficient extraction of bioactive constituents and is consistent with previously reported yields for *Silybum marianum* seeds extracted using hydroalcoholic solvents.

Table 2: Comparative Yield of *Silybum marianum* Extracts Using Various Solvents and Methods

S. No.	Extraction Method	Solvent Used	Plant Material (g)	Yield (% w/w)
1	Soxhlet Extraction	70% Ethanol	200	**13.5**
2	Cold Maceration	70% Ethanol	100	11.8
3	Soxhlet Extraction	Absolute Ethanol	200	10.2
4	Reflux Extraction	Methanol	150	14.3
5	Cold Maceration	Distilled Water	100	7.6
6	Soxhlet Extraction	80% Methanol	200	15.5

The use of 70% ethanol as the extraction solvent was selected because of its ability to efficiently extract both polar and moderately non-polar phytoconstituents. The obtained extractive yield of **13.5% w/w** was within the reported range for *Silybum marianum* seeds, indicating effective recovery of bioactive constituents, particularly flavonolignans such as silybin and silydianin.

The relatively high yield suggests the presence of important phytochemical groups including flavonoids, phenolic compounds, tannins, and sterols, which are associated with hepatoprotective and antioxidant activities. In addition, concentration of the extract under reduced pressure and storage at 4°C helped preserve thermolabile constituents, ensuring the stability and biological activity of the extract for subsequent pharmacological evaluation. Overall, the results demonstrate that Soxhlet extraction with 70% ethanol is a suitable method for obtaining a phytochemically rich extract of Silybum marianum.

Phytochemical Screening

Preliminary phytochemical analysis of the ethanolic extract of *Silybum marianum* confirmed the presence of flavonoids, phenols, saponins, tannins, glycosides, and steroids, while alkaloids were absent. The presence of these bioactive constituents may contribute to the antioxidant and hepatoprotective activity of the extract.

Table 3: Phytochemical Constituents in Ethanolic Extract of *Silybum marianum*

S. No.	Phytochemical Class	Test Method	Result
1	Flavonoids	Alkaline reagent test	+
2	Phenols	Ferric chloride test	+
3	Saponins	Frothing test	+
4	Tannins	Lead acetate / Ferric chloride test	+
5	Glycosides	Keller–Killiani test	+
6	Steroids	Salkowski's test	+
7	Alkaloids	Wagner's and Mayer's tests	−

Biochemical Analysis

Table 4: Effect of Ethanolic Extract of Silybum marianum for Biochemical estimation

Group	ALT (U/L)	AST (U/L)	ALP (U/L)	Total Bilirubin (mg/dL)	Total Protein (g/dL)
I	41.25 ± 2.11	76.32 ± 2.45	96.42 ± 3.18	0.72 ± 0.04	6.72 ± 0.21
II	134.62 ± 4.58†	198.56 ± 5.67†	245.36 ± 6.01†	2.35 ± 0.09†	3.85 ± 0.17†
III	52.33 ± 3.04***	89.47 ± 3.01***	112.78 ± 3.92***	0.91 ± 0.05***	6.42 ± 0.18***
IV	66.72 ± 2.95**	102.36 ± 3.29**	132.64 ± 4.11**	1.12 ± 0.07**	5.92 ± 0.20**
V	49.56 ± 2.38***	84.25 ± 2.74***	108.25 ± 3.44***	0.89 ± 0.04***	6.55 ± 0.16***

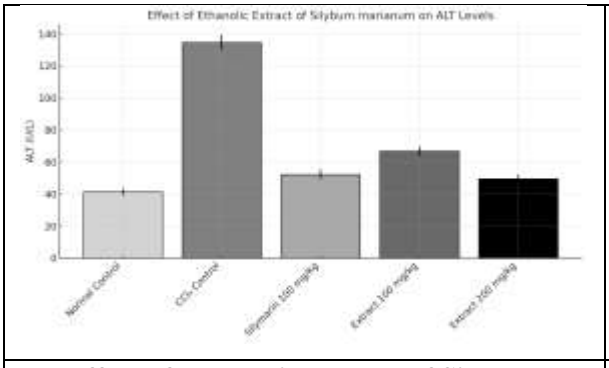

Effect of Ethanolic Extract of Silybum marianum on ALT Levels in CCl_4-Induced Hepatotoxic Rats

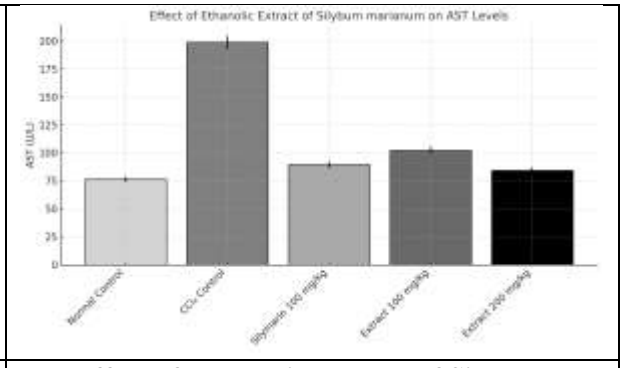

Effect of Ethanolic Extract of Silybum marianum on AST Levels in CCl_4-Induced Hepatotoxic Rats

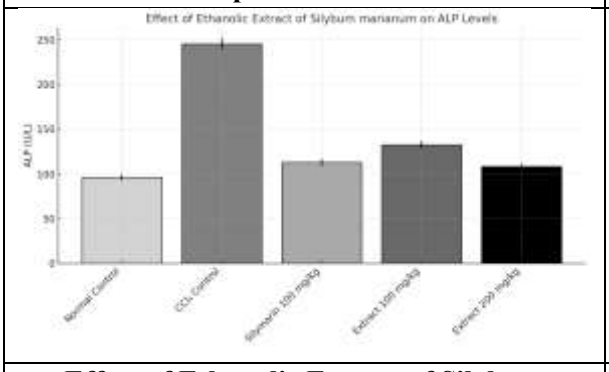

Effect of Ethanolic Extract of Silybum marianum on ALP Levels in CCl_4-Induced Hepatotoxic Rats

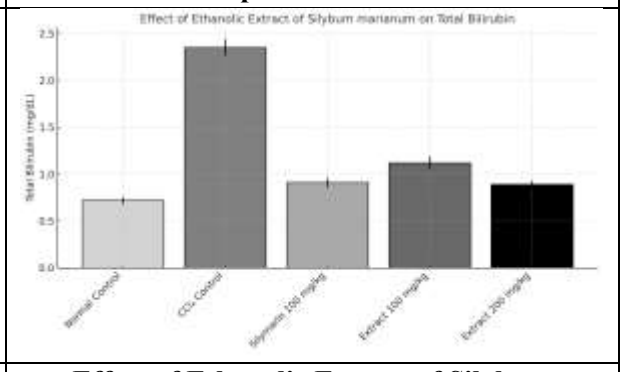

Effect of Ethanolic Extract of Silybum marianum on Total Bilirubin Levels in CCl_4-Induced Hepatotoxic Rats

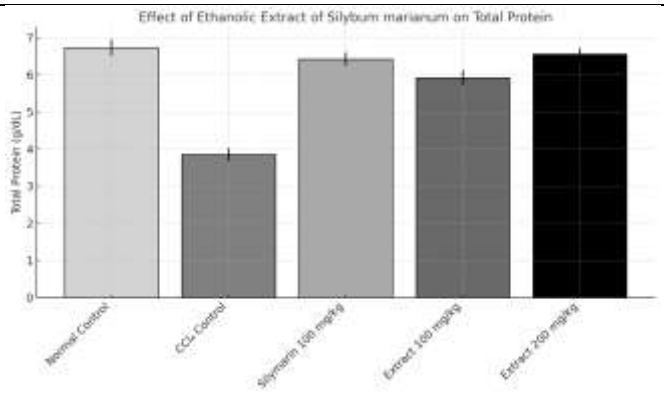

Effect of Ethanolic Extract of Silybum marianum on Total Protein Levels in CCl_4-Induced Hepatotoxic Rats

Figure 1: Biochemical estimation of Silybum marianum for Antioxidant activity

Estimation of Antioxidant Parameters

Table 5: Effect of Ethanolic Extract of Silybum marianum for Antioxidant activity

Group	MDA (nmol/mg protein)	SOD (units/min/mg protein)	CAT (µmol H_2O_2 decomposed/min/mg protein)
I	1.28 ± 0.06	12.84 ± 0.45	48.75 ± 1.62
II	4.91 ± 0.12†	4.92 ± 0.22†	19.34 ± 0.95†
III	1.72 ± 0.09***	10.76 ± 0.41***	42.58 ± 1.33***
IV	2.14 ± 0.11**	9.14 ± 0.38**	36.47 ± 1.28**
V	1.54 ± 0.07***	11.42 ± 0.33***	45.12 ± 1.41***

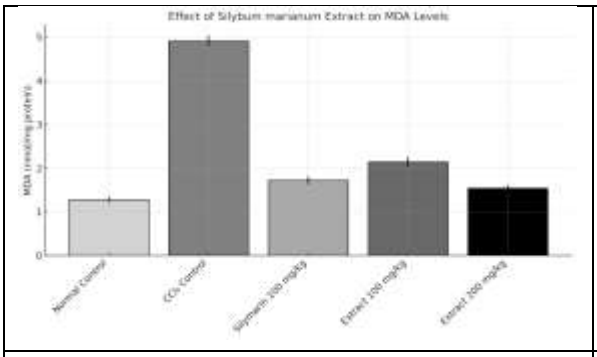

Effect of Ethanolic Extract of Silybum marianum on MDA Levels in CCl_4-Induced Hepatotoxic Rats

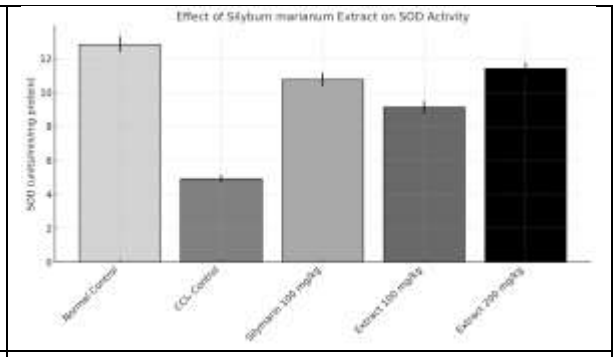

Effect of Ethanolic Extract of Silybum marianum on SOD Levels in CCl_4-Induced Hepatotoxic Rats

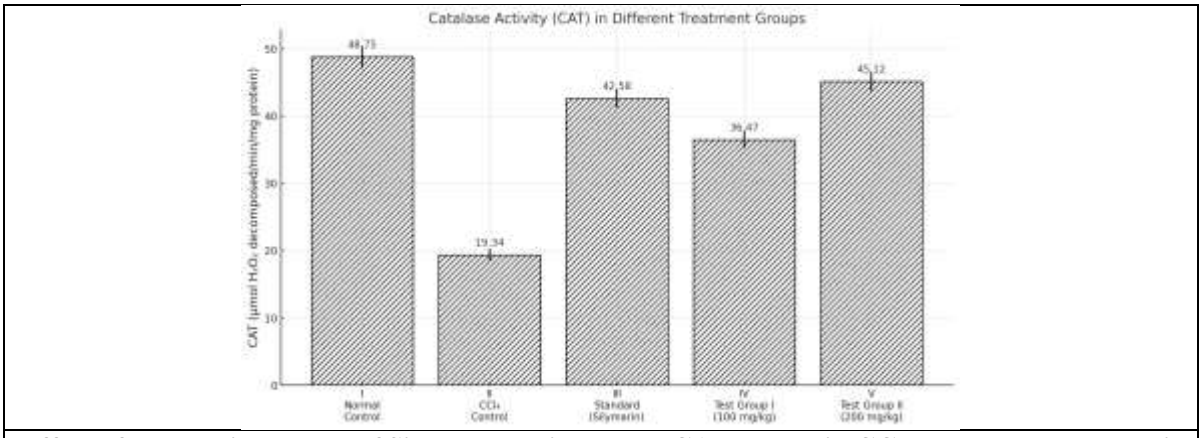

Effect of Ethanolic Extract of Silybum marianum on CAT Levels in CCl_4-Induced Hepatotoxic Rats

Figure 2: Effect of Ethanolic Extract of Silybum marianum for Antioxidant activity

Histopathological Evaluation

Histopathological examination of H&E-stained liver sections revealed normal hepatic architecture with intact hepatocytes and no pathological alterations in the normal control group. In contrast, the CCl_4-treated group showed severe hepatocellular necrosis, fatty degeneration, inflammatory cell infiltration, and disruption of normal liver architecture, confirming successful induction of hepatotoxicity. Treatment with silymarin (100 mg/kg) markedly protected the liver, as evidenced by reduced necrosis and inflammation along with preservation of hepatic architecture. Similarly, rats treated with *Silybum marianum* extract exhibited dose-dependent hepatoprotective effects. The 100 mg/kg dose showed moderate improvement with reduced steatosis and inflammatory changes, whereas the 200 mg/kg dose demonstrated near-normal liver architecture with minimal necrosis and significant hepatocyte regeneration. The hepatoprotective effect of the higher dose was comparable to that of the standard silymarin-treated group.

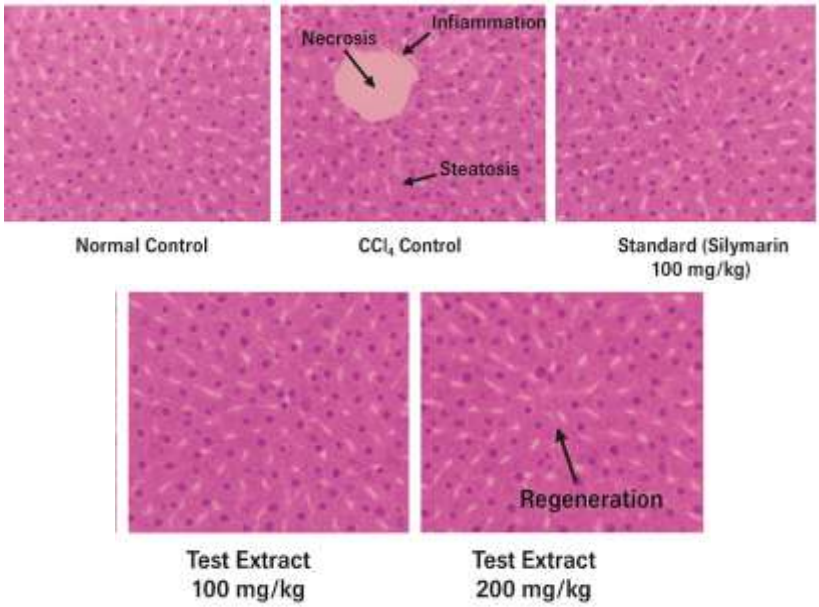

Figure 3: Histopathological Photomicrographs of Liver Tissues from Different Groups (Normal, CCl_4 Control, Standard, Extract 100 mg/kg, Extract 200 mg/kg)

The histopathological findings confirmed the hepatoprotective potential of *Silybum marianum* extract against CCl_4-induced liver injury. Severe hepatic damage observed in the CCl_4 control group was markedly reduced following treatment with the extract. The protective effect was dose-dependent, with the 200 mg/kg dose showing greater restoration of normal liver architecture, reduced necrosis, and decreased inflammatory changes. These effects may be attributed to the antioxidant and membrane-stabilizing properties of silymarin, the principal active constituent of *Silybum marianum*. The presence of regenerating hepatocytes further indicates the liver-restorative potential of the extract, with efficacy comparable to the standard silymarin-treated group.

CONCLUSION

The present study demonstrated that the ethanolic extract of *Silybum marianum* possesses significant hepatoprotective activity against CCl_4-induced liver damage in Wistar rats. Treatment with the extract effectively reduced elevated liver enzyme levels (ALT, AST, ALP, and bilirubin), restored antioxidant defenses (SOD and CAT), and decreased lipid peroxidation as indicated by reduced MDA levels. Histopathological findings further confirmed the protective effect of the extract, showing improved hepatic architecture, reduced necrosis and inflammation, and enhanced hepatocyte regeneration, particularly at the dose of 200 mg/kg. The hepatoprotective effect was dose-dependent and comparable to that of the standard drug silymarin. These findings suggest that the hepatoprotective activity of *Silybum marianum* may be attributed to its antioxidant and membrane-stabilizing properties. Therefore, *Silybum marianum* has potential as a natural therapeutic agent for the prevention and management of liver disorders.

REFERENCES

1. Hall JE. Guyton and Hall Textbook of Medical Physiology. 14th ed. Philadelphia: Elsevier; 2021.
2. Asrani SK, Devarbhavi H, Eaton J, Kamath PS. Burden of liver diseases in the world. J Hepatol. 2019;70(1):151–171.
3. Weber LW, Boll M, Stampfl A. Hepatotoxicity and mechanism of action of carbon tetrachloride. Crit Rev Toxicol. 2003;33(2):105–136.
4. Recknagel RO, Glende EA Jr, Dolak JA, Waller RL. Mechanisms of carbon tetrachloride toxicity. Pharmacol Ther. 1989;43(1):139–154.
5. Manibusan MK, Odin M, Eastmond DA. Postulated carbon tetrachloride mode of action. J Environ Sci Health C. 2007;25(3):185–209.
6. Suja SR, Latha PG, Pushpangadan P, Rajasekharan S. Evaluation of hepatoprotective effects of medicinal plants. J Ethnopharmacol. 2004;95(1):61–66.
7. Valko M, Leibfritz D, Moncol J, Cronin MT, Mazur M, Telser J. Free radicals and antioxidants in normal physiological functions. Int J Biochem Cell Biol. 2007;39(1):44–84.
8. Li S, Tan HY, Wang N, Zhang ZJ, Lao L, Wong CW, . The role of oxidative stress and antioxidants in liver diseases. Int J Mol Sci. 2015;16(11):26087–26124.
9. Asha VV, Pushpangadan P. Preliminary evaluation of hepatoprotective activity of medicinal plants. Fitoterapia. 1998;69(5):409–416.
10. Kroll DJ, Shaw HS, Oberlies NH. Milk thistle nomenclature and chemistry. Integr Cancer Ther. 2007;6(2):110–113.
11. Flora K, Hahn M, Rosen H, Benner K. Milk thistle (*Silybum marianum*) for the therapy of

liver disease. Am J Gastroenterol. 1998;93(2):139–143.
12. Polyak SJ, Ferenci P, Pawlotsky JM. Hepatoprotective and antiviral functions of silymarin. Hepatology. 2013;57(3):1262–1271.
13. Surai PF. Silymarin as a natural antioxidant. Antioxidants. 2015;4(1):204–247.
14. Federico A, Dallio M, Loguercio C. Silymarin/silybin and chronic liver disease. World J Gastroenterol. 2017;23(27):4778–4793.
15. Abenavoli L, Izzo AA, Milic N, Cicala C, Santini A, Capasso R. Milk thistle and liver diseases. Phytother Res. 2018;32(11):2202–2213.
16. Vargas-Mendoza N, Madrigal-Santillán E, Morales-González A, Esquivel-Soto J, Esquivel-Chirino C, García-Luna Y, . Hepatoprotective effect of silymarin. World J Hepatol. 2014;6(3):144–149.
17. Calixto JB, Campos MM, Otuki MF, Santos ARS. Anti-inflammatory compounds of plant origin. Journal of Ethnopharmacology. 2004;90(2–3):135–148
18. Pan SY, Zhou SF, Gao SH, Yu ZL, Zhang SF, Tang MK, Sun JN, Ma DL, Han YF, Fong WF, Ko KM. New perspectives on how to discover drugs from herbal medicines: CAM's outstanding contribution to modern therapeutics. Phytotherapy Research. 2013;27(5):767–774.
19. Handa SS, Kapoor VK, Chaudhary SK, Sharma PK, Kaul MK. Indian Herbal Pharmacopoeia. Revised ed. Mumbai: Indian Drug Manufacturers' Association; 2008.
20. Trease GE, Evans WC. Trease and Evans' Pharmacognosy. 16th ed. Edinburgh: Saunders Elsevier; 2012.
21. Committee for the Purpose of Control and Supervision of Experiments on Animals (CPCSEA). Guidelines for Laboratory Animal Facility. New Delhi: Ministry of Environment, Forest and Climate Change, Government of India; 2003.
22. Institutional Animal Ethics Committee. Approval of experimental protocol for animal studies; 2025.
23. Organisation for Economic Co-operation and Development. OECD Guidelines for the Testing of Chemicals: Test No. 423 – Acute Oral Toxicity (Acute Toxic Class Method). Paris: OECD Publishing; 2001.
24. López-Alarcón C, Denicola A. Evaluating the antioxidant capacity of natural products: A review on chemical and cellular-based assays. Toxicology Reports. 2013;1:124–139.
25. Ekor M. The growing use of herbal medicines: issues relating to adverse reactions and challenges in monitoring safety. Phytomedicine. 2014;21(6):587–595.
26. Reitman S, Frankel S. A colorimetric method for the determination of serum glutamic oxaloacetic and glutamic pyruvic transaminases. American Journal of Clinical Pathology. 1957;28(1):56–63.
27. Misra HP, Fridovich I. The role of superoxide anion in the autoxidation of epinephrine and a simple assay for superoxide dismutase. Journal of Biological Chemistry. 1972;247(10):3170–3175.
28. Bancroft JD, Gamble M. Theory and Practice of Histological Techniques. 6th ed. Philadelphia: Churchill Livingstone Elsevier; 2008.
29. Altman DG. Practical Statistics for Medical Research. London: Chapman and Hall; 1991.
30. Flora, K. . (2015). Milk thistle (*Silybum marianum*) in liver diseases: A literature review. *Digestive and Liver Disease*, 47(10), 735–742.
31. Liu, Y. . (2024). Silymarin and hepatoprotection: From bench to bedside. *Phytomedicine*, 130, 155178.

32. Hartinger, J. . (2023). Phytochemicals in liver protection: Role of silymarin and other flavonoids. *Current Pharmaceutical Biotechnology*, 24(1), 55–66
33. WHO Monographs on Selected Medicinal Plants, Volume 2. Geneva: World Health Organization; 2004.
34. Singh D, Cho WC, Upadhyay G. Drug-induced liver toxicity and herbal drugs: a review. Chem Biol Interact. 2014;224:1–18.

HOW TO CITE: Yashkirti Vishwakarma, Abhishek Shrivastava, Evaluation of Hepatoprotective Activity of Silybum Marianum on Carbon Tetrachloride Induced Liver Damage in Rats, Int. J. of Pharm. Sci., 2026, Vol 4, Issue 6, 5370-5379, https://doi.org/10.5281/zenodo.20773099