BMC Pharmacology and Toxicology

RESEARCH Open Access

Biochemical, histopathological, and immunohistochemical study on the ameliorative effect of crocin against lipopolysaccharide-induced hippocampal toxicity in male albino rats

Eatemad A. Awadalla[1*], Ola Mohamed[1], Ahmed Abdelsadik[1], Hoda S. Sherkawy[2] and Abd El-Kader M. Abd El-Kader[1]

Abstract

Background Lipopolysaccharide (LPS)-induced neuroinflammation is widely used as an animal model for studying the mechanisms of neuroinflammation. Crocin, an active component of saffron (*Crocus sativus L*), possesses several beneficial properties. The present study aimed to investigate the role of crocin in alleviating hippocampal toxicity induced by LPS in rats.

Method Forty male albino rats were randomly divided into five groups. Group I served as a control. Group II intraperitoneally (i.p.) injected with LPS (1 mg/kg/day) for a week. Groups III, IV, and V were treated by oral gavage with captopril (50 mg/kg/day), crocin (50 mg/kg/day), and a combination of both captopril (50 mg/kg/day) and crocin (50 mg/kg/day), respectively for 30 consecutive days, starting on the 8th day after LPS i.p. injection. During the therapy schedule, rats were tested for memory and learning abilities. Hippocampal samples were collected for biochemical, histological, immunohistochemical, and morphometric studies. Biochemical evaluation included nuclear factor kappa B, inflammatory cytokines (tumor necrosis factor-α and interleukin-1β), amyloid beta, angiotensin-converting enzyme, markers of the cholinergic system (acetylcholinesterase and choline acetyltransferase), antioxidant enzymes (catalase and superoxide dismutase) and an oxidative stress indicator (malondialdehyde). Histological examinations, as well as immunohistochemical and histomorphometric analysis, were also performed on hippocampal tissue.

Results The results revealed biochemical, histological, and immunohistochemical alterations in the hippocampus of the LPS group. Most of these alterations showed satisfactory improvements in hippocampal tissue when LPS-administered rats were treated with captopril and crocin, either separately or in combination.

*Correspondence:
Eatemad A. Awadalla
Eatemad2000@aswu.edu.eg

Full list of author information is available at the end of the article

© The Author(s) 2025. **Open Access** This article is licensed under a Creative Commons Attribution 4.0 International License, which permits use, sharing, adaptation, distribution and reproduction in any medium or format, as long as you give appropriate credit to the original author(s) and the source, provide a link to the Creative Commons licence, and indicate if changes were made. The images or other third party material in this article are included in the article's Creative Commons licence, unless indicated otherwise in a credit line to the material. If material is not included in the article's Creative Commons licence and your intended use is not permitted by statutory regulation or exceeds the permitted use, you will need to obtain permission directly from the copyright holder. To view a copy of this licence, visit http://creativecommons.org/licenses/by/4.0/.

Conclusion The present study suggests that crocin acts as a promising therapeutic agent for alleviating memory impairments and neuroinflammation induced by LPS.

Keywords Lipopolysaccharide, Crocin, Captopril, Hippocampal toxicity, Memory impairments

Background

Lipopolysaccharide (LPS), a key gram-negative bacteria cell wall component, is extensively utilized in experimental models of amyloidosis and neuroinflammation [1], affecting various neurological disorders including Alzheimer's disease (AD) [2], Parkinson's disease [3], amyotrophic lateral sclerosis [4], and multiple sclerosis [5]. The exact cause of AD remains unknown, despite various hypotheses including neuroinflammation, the amyloid beta (Aβ) deposition, and cholinergic hypothesis [6].

Nuclear factor kappa B (NF-κB), a key inflammation regulator, is extensively researched [7]. Bacterial toxins, like LPS, are believed to trigger NF-κB activation, implicating it in AD progression [8, 9].

LPS enters the brain and impacts the central nervous system through interactions with cluster of differentiation (CD14) on microglial membranes, forming the LPS-CD14 complex and binding to Toll-like receptor 4 (TLR4), activating microglia and initiating signal transduction cascades [10, 11]. NF-κB activation triggers gene transcription, releasing proinflammatory cytokines like tumor necrosis factor-α (TNF-α) and interleukin- 1β (IL-1β), which increase angiotensin-converting enzyme (ACE) levels [12] and promote AD pathogenesis by increasing amyloid precursor protein expression and Aβ formation [13].

LPS is also associated with the overproduction of reactive oxygen species (ROS), which overwhelms the brain's antioxidant defenses. This imbalance leads to lipid peroxidation, causing oxidative stress and apoptotic neuronal death [14].

Captopril has been shown to reduce microglial activation and amyloid burden in AD models, indicating its role in mitigating neuroinflammation. In vivo studies demonstrated that intranasal administration of captopril significantly decreased markers of inflammation and amyloid plaques in transgenic mice [15]. Captopril treatment in aged Tg2576 mice resulted in normalized ACE activity and reduced reactive oxygen species (ROS), which are linked to neurodegeneration. Also, the drug's ability to decrease amyloidogenic processing of amyloid precursor protein (APP) further supports its potential in slowing AD progression [16]. Studies have shown that captopril can enhance memory function and increase brain-derived neurotrophic factor (BDNF) expression in experimental models of AD. This suggests that captopril not only addresses neuroinflammation but also supports cognitive functions, which are often impaired in AD patients. While the evidence is promising, it is essential to recognize that the understanding of captopril's full impact on AD is still developing, and further clinical studies are necessary to establish definitive therapeutic roles [17]. Captopril attenuates oxidative stress and neuroinflammation implicated in cisplatin-induced cognitive deficits in rats [18]. In parallel, increasing attention has been directed toward bioactive compounds from medicinal plants, which have shown therapeutic potential in various neurological and systemic disorders [19]. Crocin, one of the major carotenoid compounds derived from saffron [20, 21], has anti-inflammatory, antioxidant, and memory-enhancing properties, making it beneficial for treating nervous system disorders such as AD [22, 23]. Crocin (CR) reduced the levels of NF-κB and phosphorylated NF-κB in crocin-treated animals. This effect was attributed to the suppression of seizure-induced ROS generation and the associated NF-κB pathway-linked neuronal damage [24]. CR was shown to inhibit microglial activation and decrease the expression of proinflammatory mediators, such as IL-1β and TNF-α, induced by LPS in both in *vitro* and in *vivo* models [25]. CR administration to aged rats has been shown to decrease acetyle cholinesterase (AChE) activity and increased acetylcholine (ACh) level, resulting in memory function improvement [26]. Also, crocin's protective effect against cognitive memory impairment is related to its ability to reduce Aβ formation [27].

Therefore, we decided to test the effects of captopril and crocin on lipopolysaccharide-induced learning and memory impairments, cholinergic system dysfunction, oxidative damage, and neuroinflammation in brain tissues of male albino rats.

Materials and methods

Materials

LPS, captopril (CAP), and CR were obtained from Sigma-Aldrish Co., USA, with CAS numbers 17,304, 441,600 and 2630, respectively. Commercial ELISA kits of TNF-α, IL-1β, NF-κB, Aβ, ACE, and choline acetyltransferase (ChAT) were purchased from Bioassay Technology Laboratory, Egypt, with catalog numbers E0082Hu, E0143Hu, E0690Hu, E1264Hu, E0927Hu, and E5039Hu, respectively. Catalase (CAT), superoxide dismutase (SOD), and lipid peroxide (MDA) were measured using commercial colorimetric kits purchased from Bio Diagnostics, Egypt, with catalog numbers CA 25 17, SD 25 21, and MD 25 29, respectively. Acetylthiocholine iodide and dithiobisnitrobenzoate (DTNB) were purchased from Alfa Aesar

Co., China. All other chemicals were of the highest quality available.

Ethical statement

The Animal Ethical Committee of Aswan University in Aswan, Egypt, approved all experimental methods, which were conducted in compliance with regional institutional policies. The ethical approval code is ASWU/05/SC/ZO/24 – 01/0.

Animals and experimental design

Forty male albino rats weighing 140 ± 20 g were obtained from the Animal House, Faculty of Science, South Valley University. Animals were kept in a well-ventilated and clean cages and maintained under a 12 h:12 h schedule of light: dark cycle at 25 ± 2 °C with a relative humidity of 15 ± 5% at the Animal House, Faculty of Science, Aswan University. Rats were housed for approximately two weeks before the study began for acclimatization.

The rats were randomly split into five equal groups of eight rats. The groups were assigned according to the treatment as follows:

Control group: The rats were not treated with any material.

LPS group: The rats were injected intraperitoneally (i.p.) with LPS (1 mg/kg b.w.) for a week [28].

LPS + CAP group: Following a week of LPS injection, this group was treated with CAP (50 mg/kg b.w.) by oral gavage for 30 days [28].

LPS + CR group: Following a week of LPS injection, this group was treated with CR (50 mg/kg b.w.) by oral gavage for 30 days [29].

LPS + CAP + CR group: Following a week of LPS injection, this group was treated with a combination of CAP and CR by oral gavage for 30 days.

Note LPS was freshly dissolved in normal saline, and both CR and CAP were freshly dissolved in distilled water.

Experimental procedures

24 h after the last dose, rats of the different groups were anesthetized using isoflurane inhalation and then animals were sacrificed by decapitation. Brains were immediately dissected on an ice-cold plate, and the hippocampus was isolated and divided into two parts, one part was stored at -80 °C for biochemical assays, and the other part was used for histological investigation. For biochemical assays we used Teflon-glass manual homogenizer. For sample preparation, a tissue sample of 0.1 g was placed in a pre-chilled tube and homogenized with 1 mL of cold phosphate-buffered saline (PBS, pH 7.4). Homogenization was performed manually on ice using approximately 15 complete strokes for 1–2 min to ensure proper breakdown of the tissue while minimizing protein degradation. Then, the homogenate was centrifuged at 4,000 g for 10 min at 4 °C, and the supernatant was collected for subsequent biochemical analysis.

Behavioral tests

Novel object recognition test

The current study used open-field test box (45 × 45 × 50 cm) to perform a novel object recognition test [30]. All animals were habituated to the test box for 10 min without the presence of objects. Following the habituation period, each animal was placed in the test box with two identical objects and allowed to explore for 5 min. The time spent by each rat exploring the objects was recorded. After a 24-hour delay, the animals were reintroduced to the test arena for 5 min, which now contained one of the original objects from the training session and one novel object. The discrimination ratio (DR) was calculated as the difference in exploration time between the novel (N) and familiar (F) objects, divided by the total exploration time (ET): DR = (N – F) / (N + F). The recognition index (RI) was calculated as the exploration time of the novel object divided by the total exploration time: RI = N / (N + F).

T-maze

The T-maze test was conducted using a discrete trial procedure, as described by Grzeda et al. [31]. Spontaneous alternation relies on the rat's natural tendency to explore new environments by alternating between goal arms of the maze. The apparatus consisted of a wooden T-maze with a start arm (15 × 50 cm) and two perpendicular goal arms (10 × 50 cm). At the beginning of each trial, the rat was placed at the start arm facing away from the goal arms. A choice was recorded once all four paws entered a goal arm. The selected arm was then blocked, and the rat remained there for 30 s before being removed and returned to the start position for the next trial. An alternation was considered correct when the rat entered the arm opposite to the one previously visited. The percentage of alternation was calculated as the ratio of correct alternations to the total number of trials.

Enzyme-linked immunosorbent assay (ELISA)

Determination of Biomarkers (NF-κB, TNF-α, IL-1β, Aβ, ChAT, and ACh).

The levels of nuclear factor kappa B (NF-κB), tumor necrosis factor-α (TNF-α), interleukin-1β (IL-1β), amyloid-β (Aβ), choline acetyltransferase (ChAT), and acetylcholine (ACh) in hippocampal homogenates were determined using ELISA kits (Bioassay Technology Laboratory, Egypt) following the manufacturer's protocols. Briefly, standards or samples were added to the wells, incubated with the corresponding specific antibody and streptavidin-HRP, and then treated with substrate

solutions. The reaction was stopped, and absorbance was measured at 450 nm using a microplate reader.

Calculation of results

Concentrations of each biomarker were determined from standard curves generated by plotting optical density (OD) values against known concentrations, with regression analysis used to calculate sample values.

Estimation of acetylcholinesterase (AChE) levels

AChE activity in hippocampal homogenates was measured using Ellman's method [32]. The assay is based on hydrolysis of acetylthiocholine to thiocholine, which reacts with DTNB to form a yellow product measured at 412 nm.

Procedure

Fifty µL of sample was mixed with phosphate buffer (pH 8), acetylthiocholine iodide, and DTNB. Absorbance was recorded at 412 nm for 2 min, and activity was expressed as nmol/min/mg tissue.

Spectrophotometry

Catalase (CAT) activity

Measured according to the method of Aebi [33]. Tissue homogenates were prepared in phosphate buffer (50 mM, pH 7.0). The assay mixture contained H_2O_2 (30 mM) in phosphate buffer, and the decomposition rate of H_2O_2 was monitored spectrophotometrically at 240 nm for 1 min. One unit of CAT activity was defined as the amount of enzyme decomposing 1 µmol of H_2O_2 per minute, expressed as U/mg protein using the molar extinction coefficient of H_2O_2 (43.6 $M^{-1}cm^{-1}$).

Superoxide dismutase (SOD) activity

Assayed following the method of Beauchamp and Fridovich [34]. The assay system consisted of 50 mM phosphate buffer (pH 7.8), 0.1 mM EDTA, 13 mM methionine, 75 µM nitroblue tetrazolium (NBT), and 2 µM riboflavin. Samples were illuminated under fluorescent light for 10 min, and absorbance was read at 560 nm. One unit of SOD activity was defined as the amount of enzyme required to inhibit NBT reduction by 50%, and the results were expressed as U/mg protein.

Malondialdehyde (MDA) levels

Estimated by the thiobarbituric acid reactive substances (TBARS) assay according to Ohkawa et al. [35]. Tissue homogenates were mixed with thiobarbituric acid (0.67%) and trichloroacetic acid (10%) and heated at 95 °C for 30 min. After cooling and centrifugation, absorbance was measured at 532 nm. MDA concentration was calculated using the extinction coefficient (1.56×10^5 $M^{-1}cm^{-1}$) and expressed as nmol MDA/mg protein.

Histological examinations

The hippocampal samples were fixed in 10% neutral buffered formalin, dehydrated through a graded series of alcohols, cleared in methyl benzoate, and embedded in paraffin wax at 58–62 °C. Sections of 5 µm thickness were cut and stained with Harris' hematoxylin and eosin stain [36]. Microscopic examination was performed to describe the general histological architecture of the hippocampus. The observations focused on morphological alterations such as nuclear pyknosis, neuronal shrinkage, vacuolation, cellular atrophy and proliferation of glial cell. The findings were documented qualitatively and illustrated with representative photomicrographs.

Immunohistochemical examinations

The expression of caspase-3 and interleukin – 6 (IL-6). According to ABclonal kit method (ABclonal Technology Company, USA), formalin-fixed, paraffin-embedded hippocampal tissue slices were sectioned at a thickness of 4–5 µm. The sections were deparaffinized and rehydrated. After applying the antigen retrieval solution, endogenous peroxidase activity was inactivated for 15 min using 3% hydrogen peroxide, and then the sections were blocked for an hour. The rabbit polyclonal primary antibody (2.5% normal goat serum diluted in PBS/TBS supplemented with 0.3% Triton™ X-100, pH 7.2) for caspase-3 (ab4051) and for IL-6 (Cell Signaling, 12153 S) was applied to each section and incubated overnight in a humidified chamber at 4 °C. Then, after applying the peroxidase-labeled secondary antibody [HRP goat anti-rabbit IgG (H + L)] (Dako, EnVision FLEX, High 800021 at a 1:200 dilution), the samples were incubated for 30 min. Freshly prepared DAB substrate and chromogen (Dako, EnVision FLEX, High pH (Link) kit # K800021) were used at room temperature for 2–5 min. Hematoxylin was used as a counterstain; sections were dried and then mounted.

Histomorphometric study and image analysis

Histomorphometric analysis was used to quantify structural changes observed in the histological analysis of hippocampal tissue. After the hippocampus was histologically processed, digital images were taken at 40× magnification using a digital camera connected to a light microscope (Olympus BX43F, Olympus Corporation, Shinjuku-ku, Tokyo, Japan). Histomorphometric analysis was performed using the ImageJ software system, version 6. Spatial calibration with an object micrometer was conducted before each analysis. Five images were selected from each animal in each group. The following morphometric parameters were measured: thickness of the pyramidale layer, % caspase-3 intensity/surface area, and % interleukin-6 intensity/surface area.

Table 1 Behavioral tests results, including discrimination ratio (DR), recognition index (RI), and % alternation in various study groups

Groups parameters	control	LPS	LPS + CAP	LPS + CR	LPS + CAP + CR
DR	0.734 ± 0.134	0.207 ± 0.041*	0.438 ± 0.052#	0.571 ± 0.094##	0.644 ± 0.041##
RI	0.852 ± 0.068	0.46 ± 0.073*	0.617 ± 0.055#	0.763 ± 0.074##	0.812 ± 0.068##
% alternation	83.71 ± 4.786	38.47 ± 6.821*	53.56 ± 4.948#	73.12 ± 9.399##	79.09 ± 7.608##

Values are expressed as mean ± SD for animals in each group

* Highly significant compared with the control group ($P < 0.01$)

Significantly different compared with the LPS group ($P < 0.05$)

Highly significant compared with the LPS group ($P < 0.001$)

Table 2 NF-κB, TNF-α, IL-1β, and Aβ in various study groups

Groups parameters	Control	LPS	LPS + CAP	LPS + CR	LPS + CAP + CR
NF-κB (ng/ml)	0.762 ± 0.019	2.567 ± 0.459*	1.988 ± 0.007#	1.134 ± 0.036##	0.973 ± 0.032##
TNF-α (ng/l)	1.093 ± 0.201	3.143 ± 0.539*	2.13 ± 0.585#	1.684 ± 0.536##	1.261 ± 0.421##
IL-1β (pg/ml)	2.89 ± 0.737	6.626 ± 1.114*	5.054 ± 0.783#	4.07 ± 0.604##	3.057 ± 0.561##
Aβ (ng / l)	1.006 ± 0.129	3.79 ± 0.401*	2.087 ± 0.636#	1.514 ± 0.456##	1.272 ± 0.355##

Values are expressed as mean ± SD for animals in each group

* Highly significant compared with the control group ($P < 0.001$)

Significantly different compared with the LPS group ($P < 0.01$)

Highly significant compared with the LPS group ($P < 0.001$)

Statistical analysis

All quantitative data were expressed as mean ± deviation (SD). For histological, behavioral, and biochemical analyses (except AChE), the data were normally distributed but showed unequal variances; therefore, statistical comparisons were performed using Welch's ANOVA and Brown–Forsythe ANOVA. For acetylcholinesterase (AChE) activity, which did not follow a normal distribution, the Kruskal–Wallis test was applied as a non-parametric alternative to one-way ANOVA. A p-value < 0.05 was considered statistically significant.

Results

Behavioral tests

The values of the discrimination ratio (DR) and recognition index (RI) in the novel object recognition test, as well as the % alternation in the T-maze, showed a highly significant decrease in the LPS group (0.207 ± 0.013, 0.46 ± 0.015, and 38.47 ± 0.016, respectively; $P < 0.01$ for all) compared with the control group (0.743 ± 0.022, 0.852 ± 0.020, and 83.71 ± 0.025, respectively). However, the values in the LPS + CAP group exhibited a significant increase (0.438 ± 0.024, 0.617 ± 0.022, and 53.56 ± 0.012, respectively; $P < 0.05$ for all) compared with the LPS group. Additionally, the values in the LPS + CR group (0.571 ± 0.011, 0.763 ± 0.012, and 73.12 ± 0.017, respectively; $P < 0.001$ for all) and in the LPS + CAP + CR group (0.644 ± 0.017, 0.812 ± 0.016, and 81.42 ± 0.015, respectively; $P < 0.001$ for all) showed a highly significant increase compared to those in the LPS group (Table 1).

Enzyme-linked immunosorbent assay (ELISA)

The nuclear factor kappa B (NF-κB), tumor necrosis factor-α (TNF-α), Interleukin-1β (IL-1β), amyloid beta (Aβ) in various study groups

Values of NF-κB, TNF-α, IL-1β, and Aβ concentrations in the LPS group showed a highly significant increase (2.612 ± 0.171 ng/ml, 3.143 ± 0.026 ng/l, 6.626 ± 0.128 pg/ml, and 3.79 ± 0.014 ng/l, respectively; $P < 0.001$ for all) compared with the control group (0.762 ± 0.06 ng/ml, 1.093 ± 0.014 ng/l, 2.89 ± 0.018 pg/ml, and 1.006 ± 0.032 ng/l, respectively). Additionally, the values in the LPS + CAP-treated animals were found to be significantly decreased (1.847 ± 0.012 ng/ml, 2.13 ± 0.021 ng/l, 5.054 ± 0.107 pg/ml, and 2.087 ± 0.025 ng/l, respectively; $P < 0.01$ for all) compared with the LPS group. Meanwhile, there was a highly significant reduction in the LPS + CR group (1.229 ± 0.013 ng/ml, 1.684 ± 0.031 ng/l, 4.07 ± 0.015 pg/ml, and 1.564 ± 0.018 ng/l, respectively; $P < 0.001$ for all) and in the LPS + CAP + CR group (0.897 ± 0.021 ng/ml, 1.261 ± 0.011 ng/l, 3.057 ± 0.014 pg/ml, and 1.272 ± 0.027 ng/l, respectively; $P < 0.001$ for all) compared with the LPS group (Table 2).

Angiotensin- converting enzyme (ACE) and choline acetyltransferase (ChAT) levels in various study groups

ACE and ChAT levels. A highly significant increase in ACE activity (1.248 ± 0.118 U/L tissue; $P < 0.001$) and a highly significant decrease in ChAT activity (1.13 ± 0.019 ng/L; $P < 0.001$) were observed in the LPS group compared to the control group (0.376 ± 0.02 U/L tissue for ACE and 4.39 ± 0.024 ng/L for ChAT). However, the

Table 3 ACE, AChE, and chat levels in various study groups

Groups parameters	Control	LPS	LPS + CAP	LPS + CR	LPS + CAP + CR
ACE	0.376 ± 0.064	1.248 ± 0.486*	0.871 ± 0.113 #	0.654 ± 0.078##	0.407 ± 0.084##
AChE	0.749 ± 0.069	2.193 ± 0.47*	1.429 ± 0.562#	1.084 ± 0.383##	0.801 ± 0.101##
ChAT	4.39 ± 0.067	1.13 ± 0.026*	2.34 ± 0.643#	3.05 ± 0.025##	4.09 ± 0.245##

Values are expressed as mean ± SD for animals in each group

* Highly significant compared with the control group ($P < 0.001$)

#Significant compared with the LPS group ($P < 0.05$)

Highly significant compared with the LPS group ($P < 0.001$)

Table 4 CAT, SOD, and MDA levels in various study groups

Groups parameters	Control	LPS	LPS + CAP	LPS + CR	LPS + CAP + CR
CAT	9.841 ± 0.428	3.06 ± 0.895*	5.196 ± 0.741#	6.94 ± 0.912##	8.773 ± 0.738##
SOD	363.47 ± 51.28	164.01 ± 6.663*	245.63 ± 49.02#	320.05 ± 0.86##	340.165 ± 24.781##
MDA	86.447 ± 6.153	247.185 ± 43.225*	178.436 ± 14.043#	119.57 ± 2.99##	91.248 ± 6.411##

Values are expressed as mean ± SD for animals in each group

* Highly significant compared with the control group ($P < 0.001$)

#Significant compared with the LPS group ($P < 0.01$)

Highly significant compared with the LPS group ($P < 0.001$)

activity of ACE in the LPS + CAP group was significantly decreased (0.871 ± 0.032 U/L tissue; $P < 0.05$), while the activity of ChAT was significantly increased (2.34 ± 0.128 ng/L; $P < 0.05$) compared with the LPS group. Meanwhile, the ACE activity was found to be highly significant reduction in the LPS + CR group (0.653 ± 0.014 U/L tissue; $P < 0.001$) and in the LPS + CAP + CR group (0.407 ± 0.012 U/L tissue; $P < 0.001$) compared with the LPS group. Additionally, the values of ChAT levels in the LPS + CR group and the LPS + CAP + CR group showed a highly significant increase (3.05 ± 0.011 ng/l and 4.09 ± 0.002 ng/l, respectively; $P < 0.001$ for both) compared with LPS-administered animals (Table 3).

Acetyle cholinesterase (AChE) level

As shown in Table 3, the results indicate that AChE activity in the LPS group was significantly higher (2.193 ± 0.117 nmol/mg tissue, $P < 0.001$) than in the control group (0.749 ± 0.0232 nmol/mg tissue). Furthermore, AChE activity in the LPS + CAP group was significantly lower (1.429 ± 0.021 nmol/mg tissue, $P < 0.05$) than in the LPS group. However, AChE activity in the LPS + CR group and the LPS + CAP + CR group showed a highly significant increase (1.084 ± 0.012 nmol/mg tissue and 0.801 ± 0.012 nmol/mg tissue, respectively; $P < 0.001$ for both) compared to that in the LPS group.

Spectrophotometry. The levels of catalase (CAT), superoxide dismutase (SOD), and malondialdehyde (MDA) in various study groups

In LPS-administered animals, the CAT and SOD activities showed a highly significant decrease, while MDA levels showed a highly significant increase (3.05 ± 0.005 U/g and 164.01 ± 2.483 U/g for CAT and SOD, respectively, and 247.185 ± 0.881 nmol/g tissue for MDA; $P < 0.001$ for all) compared with control animals (9.841 ± 0.02 U/g, 363.47 ± 0.651 U/g, and 86.447 ± 0.11 nmol/g tissue, respectively). In the LPS + CAP group, CAT and SOD activity showed a significant increase, while MDA levels significantly decreased (5.196 ± 0.026 U/g and 245.63 ± 0.711 U/g for CAT and SOD, respectively, and 178.436 ± 0.166 nmol/g tissue for MDA; $P < 0.01$ for all) compared with the LPS group. However, CAT and SOD activities showed a highly significant increase, while MDA levels exhibited a highly significant decrease in both the LPS + CR group (6.94 ± 0.083 U/g and 320.05 ± 0.318 U/g for CAT and SOD, respectively, and 119.57 ± 1.116 nmol/g tissue for MDA; $P < 0.001$ for all) and the LPS + CAP + CR group (8.773 ± 0.007 U/g, 340.165 ± 0.109 U/g for CAT and SOD, respectively, and 91.248 ± 0.138 nmol/g tissue for MDA; $P < 0.001$ for all) compared with the LPS- administered animals (Table 4).

Histological findings of the hippocampus in various study groups

In the control group, histological analysis of the hippocampus revealed its characteristic bilateral, incurved, and seahorse-shaped structure, encompassing the cornu ammonis regions (CA1 and CA2, composed of small pyramidal cells) and (CA3 and CA4, composed of large pyramidal cells), as well as the dentate gyrus (DG). Each region of Cornu Ammonis consisted of five areas: stratum alveolus (SA), stratum oriens (SO), stratum pyramidale (SP), stratum radiatum (SR), and stratum lacunosum-moleculare (SL-M) (Fig. 1a). The SP of CA1 in the control group consisted of 4–5 layers of small

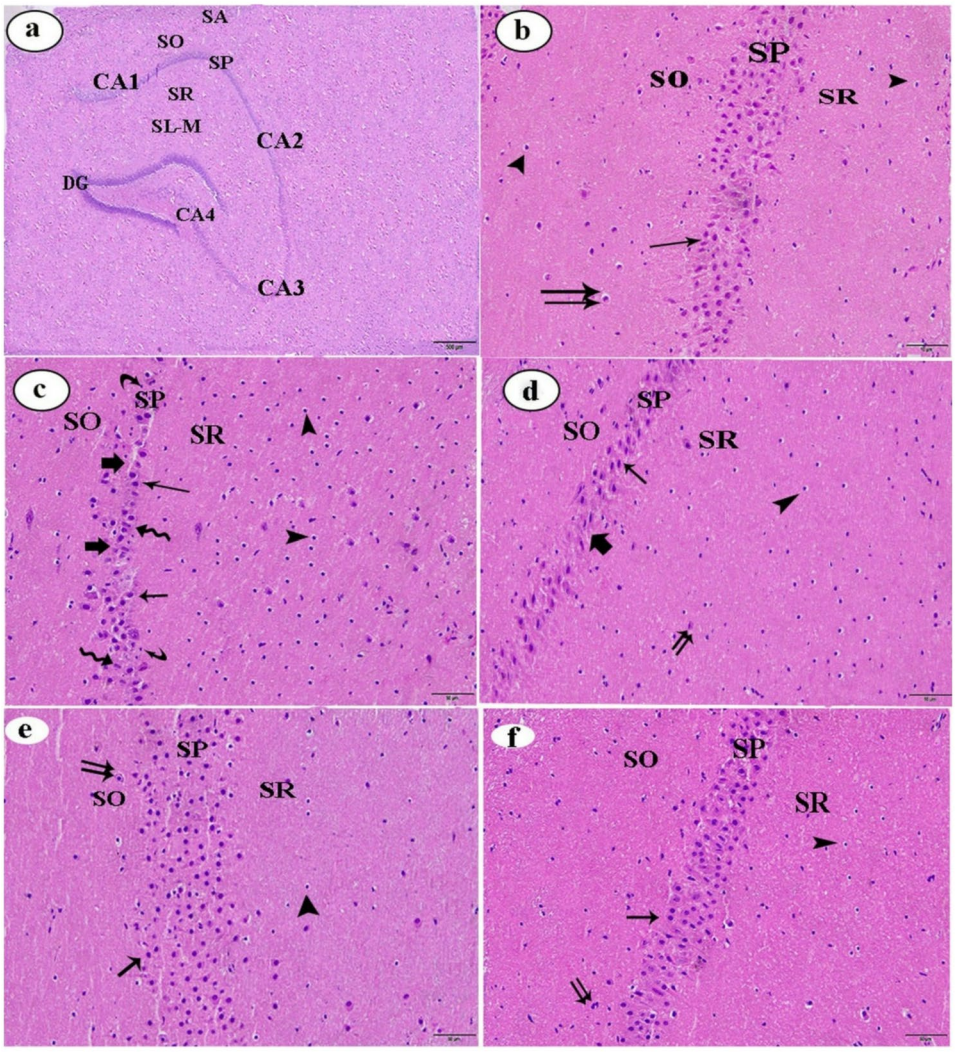

Fig. 1 (**a**-**f**): Photomicrographs of hippocampal sections from male albino rats stained with H&E (original magnification: a, X200; b-f, X400). (**a** & **b**) Low and high magnifications of hippocampal sections from the control group. (**c**) Section from the LPS group. (**d**) Section from the LPS + CAP group. (**e**) Section from the LPS + CR group. (**f**) Section from the LPS + CAP + CR group. Stratum pyramidale (SP), stratum oriens (SO), stratum radiatum (SR). Pyramidal cells (thin arrow), neuroglia (arrowhead), blood capillaries (double arrow), dispersed vacuolization (thick arrow), shrunken neurons (curved arrow), atrophied and elongated cells (zigzag arrow). H&E: haematoxylin and eosin; LPS: lipopolysaccharide; CAP: captopril; CR: crocin

pyramidal neurons. Neuroglial cells and blood capillaries with normal morphology were observed in the SO and SR (Fig. 1b). In contrast to the control group, hippocampal tissue from the LPS group exhibited severe histopathological alterations in the CA1 region. The SP showed significant vacuolization, reduced neuronal layers (2–3), pyknotic nuclei, neuronal shrinkage, cellular atrophy, and irregularly shaped cells. Gliosis was prominent in the SO and SR, indicating glial cell proliferation (Fig. 1c).

Compared with the LPS group, hippocampal tissue from the LPS + CAP group retained its normal appearance to some extent. In the CA1 region, the SP retained 2–3 discrete neuronal layers, with reduced pyknotic nuclei and decreased vacuolization. Moreover, moderate gliosis, indicated by diminished glial cell proliferation, was observed in the SO and SR (Fig. 1d). Histological investigation of the hippocampal sections from the LPS + CR and LPS + CAP + CR groups revealed substantial preservation of hippocampal architecture compared with the LPS group. The SP exhibited marked improvement, with neurons displaying normal morphology. Restoration of glial cell distribution and blood capillaries integrity was observed in the SO and SR (Fig. 1e and f, respectively).

Immunohistochemical findings of the hippocampus in various study groups

The expression of caspase-3 and interleukin-6 (IL-6)

In the control group, immunohistochemical analysis of caspase-3 and IL-6 expression in hippocampal tissues revealed minimal immunoreactivity, indicated by very weak brown staining in the SP, SO, and SR (Figs. 2a and 3a, respectively). Conversely, the LPS-administered group exhibited pronounced immunoreactivity for caspase-3 and IL-6, with intense brown staining in the same layers (Figs. 2b and 3b, respectively). Compared to the LPS-administered group, the LPS + CAP, LPS + CR, and LPS + CAP + CR groups exhibited weak caspase-3 and IL-6 immunoreactivity, as indicated by faint brown staining in the SP, SO, and SR of the CA1 region (Figs. 2c, d, and e, respectively, for caspase-3 expression, and Figs. 3c, d, and e, respectively, for IL-6).

Histomorphometric findings of the hippocampus in various study groups

Thickness of the SP of the CA1

There was a statistically significant decrease in the thickness of the SP of the CA1 in the LPS-administered group (46.50 ± 0.155 µm; $P < 0.05$) relative to the control group (69.38 ± 0.045 µm). Meanwhile, there was a non-significant change in the thickness of the SP of the CA1 (43.79 ± 0.291 µm; $P > 0.05$) in the LPS + CAP group relative to the LPS-administered group. Compared to the LPS group, the LPS + CR group and LPS + CAP + CR group showed a statistically highly significant increase in the thickness of the SP of the CA1 (77.42 ± 0.494 µm and 66.48 ± 0.199 µm, respectively; $P < 0.001$ for both) (Fig. 4a; Table 5).

Intensity of caspase-3 and IL-6 in the CA1 region of hippocampal sections

There was a highly significant increase in the intensity of caspase-3 and IL-6 in the CA1 region of hippocampal sections in the LPS group (4.210 ± 0.132 and 9.03 ± 0.154, respectively; $P < 0.001$ for both) compared to the control group (1.051 ± 0.341 and 1.17 ± 0.087, respectively). Conversely, the LPS + CAP group exhibited a significantly reduced staining intensity of caspase-3 and IL-6 in the CA1 region (2.283 ± 0.098 and 7.21 ± 0.201; $P < 0.05$ for both) compared to the LPS-induced group. Furthermore, the LPS + CR group showed a highly significant reduction in caspase-3 staining intensity (1.789 ± 0.214; $P < 0.001$) and a significant reduction in IL-6 staining intensity (5.48 ± 0.132; $P < 0.05$) relative to the LPS-treated group. However, the LPS + CAP + CR group exhibited a highly significant decrease in caspase-3 and IL-6 intensity in the CA1 region (1.14 ± 0.211 and 1.742 ± 0.102, respectively; $P < 0.001$ for both) (Fig. 4b and c, respectively; Table 5).

Discussion

Behavioral tests are employed to evaluate their impact on cognitive functions, memory, and overall behavior. These tests help link the LPS-induced inflammation to behavioral changes, mainly in models of neurodegenerative diseases such as AD [37]. The present study demonstrated that the LPS group experienced a highly significant decrease in DR and RI in the novel object recognition task, as well as in alternation (%) in the T-maze test. The current results are reinforced by Frühauf et al. [38], Khan et al. [39], and Alshehri et al. [40], who explained that behavioral test performance was found to be reduced as a result of increased cytokine levels. In parallel with these results, reports from Bassi et al. [41], Okuyama et al. [42], and Lee et al. [43], who observed that LPS-induced changes in behavioral tests such as the novel object recognition task and T-maze. A possible explanation for these findings is the increase in LPS-induced neuronal cell death and the gradual neuronal loss, which lead to learning and memory dysfunction, as documented by Smith et al. [44] and Kranjac et al. [45].

The present findings in the LPS group revealed a highly significant elevation in the concentrations of NF-κB, TNF-α, IL-1β, Aβ, ACE and AChE activity, along with a highly significant reduction in ChAT levels in the homogenate of the brain hippocampus. Similarly, LPS activates NF-κB transcription factors, which play a critical role in various physiological processes, including synaptic plasticity related to learning and memory [43, 46, 47]. Similarly, when LPS binds to TLR4, triggering MyD88-dependent signaling, it activates the NF-κB pathway. NF-κB then translocates to the nucleus, inducing the transcription of proinflammatory cytokines such as IL-1β, IL-6, and TNF-α, thereby driving inflammation [48–50].

Evidence linking acute systemic inflammation, secondary neuroinflammation, and the accumulation of Aβ plaques in the brain is strengthened by the current study. The current findings are similar to those studies hypothesized that LPS-induced neuroinflammation impairs memory performance through elevated Aβ [51, 52].

ACE cooperates with LPS in the playing roles in the inflammatory pathways and contributes to neurodegenerative illnesses like AD [53]. Our observation is in agreement with the previous studies reported that LPS exposure triggers inflammatory pathways, including NF-κB signaling, and this response is linked to enhanced immune activity, contributing to elevated ACE levels [54, 55]. Additionally, our findings align with those of other researchers who have demonstrated that LPS administration activates localized renin angiotensin system (RAS)

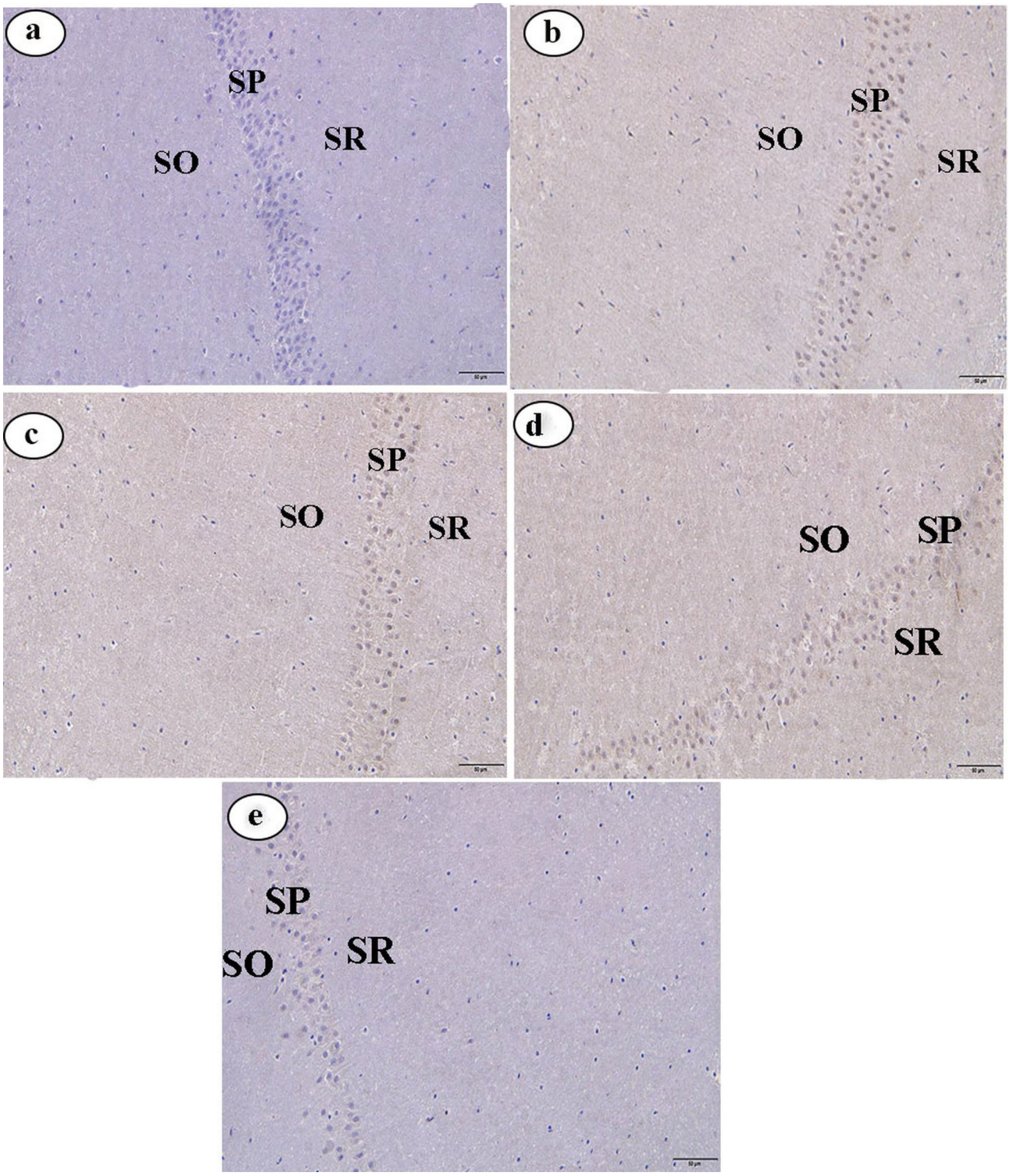

Fig. 2 (**a**-**e**) Photomicrographs of hippocampal sections from male albino rats immunostained for caspase-3 (original magnification: X400). (**a**) Hippocampal section from the control group. (**b**) Section from the LPS group. (**c**) Section from the LPS + CAP group. (**d**) Section from the LPS + CR group. (**e**) Section from the LPS + CAP + CR group. Stratum pyramidale (SP), stratum oriens (SO), and stratum radiatum (SR)

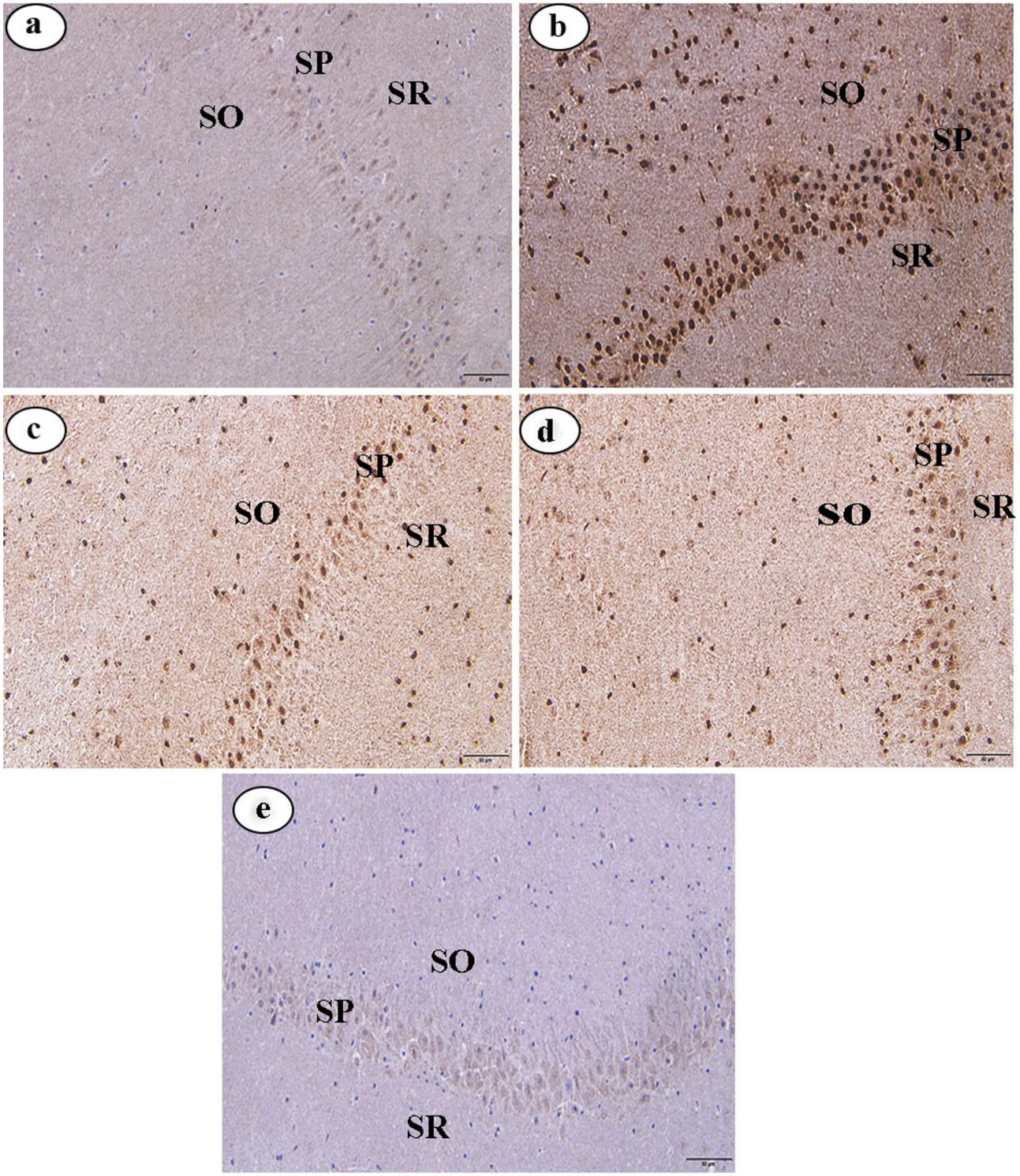

Fig. 3 (**a**-**e**) Photomicrographs of hippocampal sections from male albino rats immunostained for IL-6 (original magnification: X400). (**a**) Hippocampal section from the control group. (**b**) Section from the LPS group. (**c**) Section from the LPS + CAP group. (**d**) Hippocampal section from the LPS + CR group. (**e**) Section from the LPS + CAP + CR group. Stratum pyramidale (SP), stratum oriens (SO), and stratum radiatum (SR)

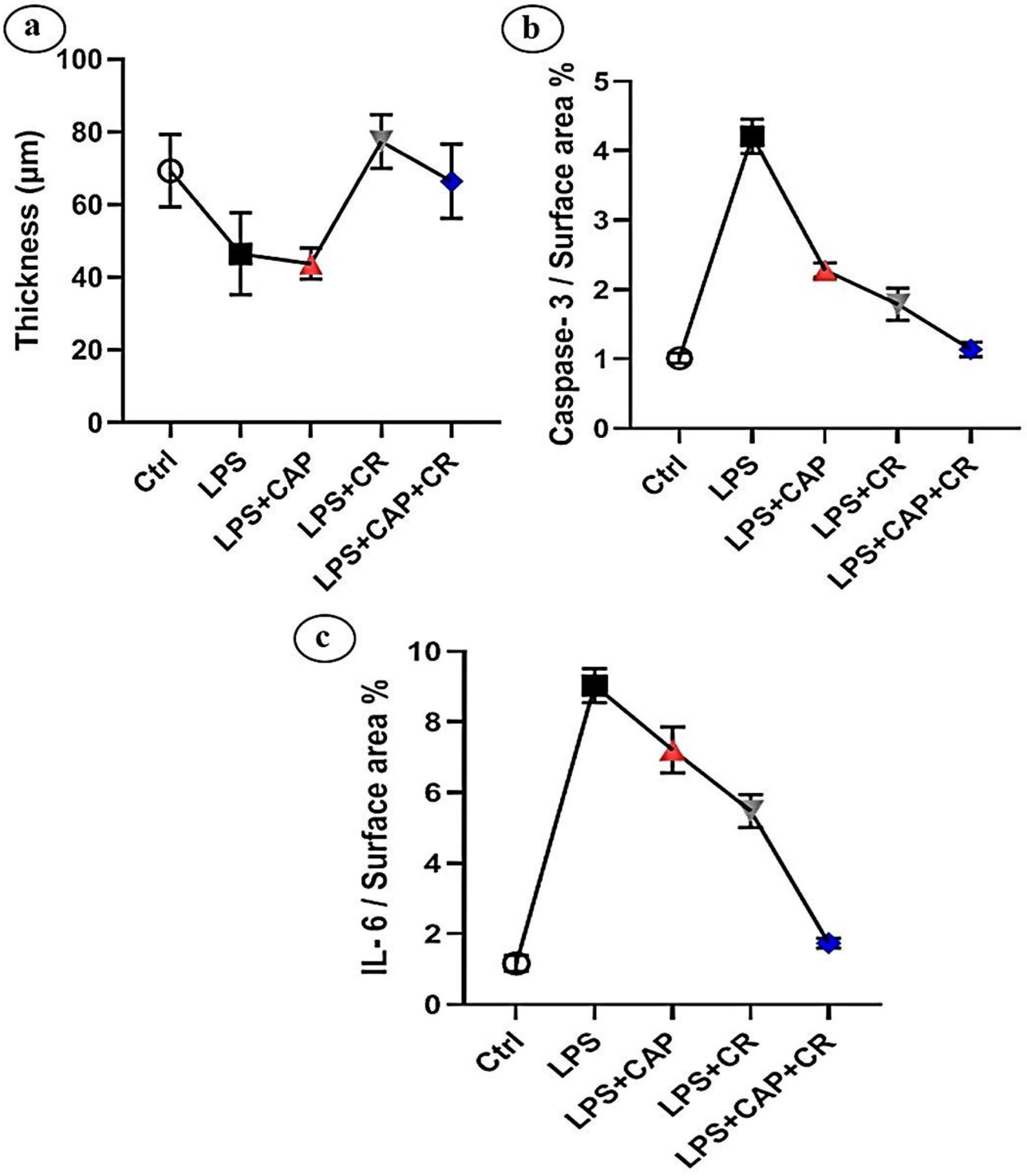

Fig. 4 (**a**-**c**) Photomicrographs of morphometric results of the hippocampal sections of the rats in various study groups. (**a**) Histogram of the thickness of the SP of the CA1 region of all groups. (**b**) Histogram of the intensity color of immunohistochemical staining for caspase-3 in CA1 region of all groups. (**c**) Histogram of the intensity of immunohistochemical staining for IL-6 in CA1 region of all groups

in the brain by increasing ACE levels [28, 56]. ACh is an excitatory neurotransmitter that plays an important role in memory, learning, and higher cognitive functions in the central cholinergic nervous system. ChAT regulates its synthesis and release, whereas AChE catalyzes its breakdown [57]. Additionally, in accordance with the present results, several supporting evidences have revealed that LPS induces an increase in AChE and

Table 5 Morphometric results of the thickness of the SP area in the CA1 region and the intensity of immunohistochemical staining for caspase-3 and IL-6 in the CA1 region

Groups parameters	Control	LPS	LPS + CAP	LPS + CR	LPS + CAP + CR
Thickness	69.38 ± 10.03	46.49 ± 11.256**	43.79 ± 4.279*	77.41 ± 7.378###	66.48 ± 10.192 ###
Intensity of caspase-3	1.015 ± 0.076	4.21 ± 0.245##	2.283 ± 0.104#	1.789 ± 0.231###	1.14 ± 0.104###
Intensity of IL-6	1.17 ± 0.228	9.03 ± 0.479##	7.21 ± 0.649#	5.48 ± 0.463#	1.742 ± 0.138###

Values are expressed as mean ± SD for animals in each group

* Non-significant compared with the LPS group ($P > 0.05$)

** Significant compared with the control group ($P < 0.01$)

Significant compared with the LPS group ($P < 0.01$)

Highly significant compared with the control-group ($P < 0.001$)

Highly significant compared with the LPS group ($P < 0.001$)

a decrease in ChAT levels [58–60]. The present results may be attributed to the idea that the increase in AChE and the decrease in ChAT levels following LPS exposure result from the activation of inflammatory pathways, particularly via NF-κB signaling and inflammatory cytokines, which can hinder ACh synthesis [61, 62].

Additionally, the present data revealed that the LPS group showed a highly significant decrease in CAT and SOD levels and a highly significant increase in MDA levels in the brain hippocampal homogenate. These results are in consistent with different studies confirmed that the LPS administration increased the levels of MDA and disrupted the endogenous antioxidant levels, which was evident by decreased SOD and catalase [43, 63, 64].

A possible interpretation of these results aligns with the findings of Ayala et al. [65] and Essadek et al. [66], who demonstrated that LPS stimulates immune cells to produce ROS, leading to the release of inflammatory cytokines. This inflammatory response can result in increased lipid peroxidation and antioxidant depletion.

At histopathological level, hippocampal tissue of the LPS group showed severe histological changes in most areas of the CA1 region. These changes included significant vacuolization, reduction of the pyramidal cell layers to 2–3 layers of neurons with pyknotic nuclei, neuronal shrinkage, cellular atrophy, and the presence of some cells with irregularly shaped outlines. Additionally, there was clear gliosis in the SO and SR. These findings are in agreement with Bahaidrah et al. [67] and He et al. [68], who noticed that the histological effect of LPS on hippocampal tissue demonstrated the presence of neurodegeneration with darker neuronal cells than the control group. Also, there were cell shrinkage, darker and elongated-looking cells, and augmented apoptotic neurons. Our results could be attributed to the fact that LPS administration triggers an immune response that leads to several histological changes in the brain via microglial activation, which ends in the release of cytokines. These cytokines contribute to neuroinflammation and can lead to neuronal injury and death as well as synaptic disruption. This synaptic disruption is associated with neuronal cell damage as documented by He et al. [68]. Additional evidence has shown that LPS generates free radicals, leading to the peroxidative destruction of brain lipid membranes and subsequent severe brain damage, including necrosis [69]. Also, the present findings showed that LPS administration increased caspase-3 and IL-6 expression in the hippocampal tissues. Similarly, Beurel et al. [70] and Sangaran et al. [71] found that injecting LPS at specific concentrations increases the secretion of caspase-3, a critical executioner caspase implicated in apoptotic cell death, as well as an increase in IL-6 synthesis via neuroinflammatory conditions. The elevation in these values may be attributed to mechanisms involving TLR4 signaling, oxidative stress, and mitochondrial dysfunction. These pathways lead to apoptosis and inflammation resulting in significant histological and functional alterations in the brain tissue [14, 72].

As expected, the current findings for the LPS + CAP group revealed a significant increase in the discrimination ratio, ratio index, and % alternation. The present results are in agreement with the previously documented by Abrashei et al. [73] and Dong et al. [74], who suggested that the treatment with CAP, which acts as an ACE inhibitor, exerts improvement in behavioral tests. Additionally, Hou et al. [75] emphasized that CAP has a significant effect on reducing cognitive impairment and modulating behavior by reducing neuroinflammation, improving cognitive function, and mitigating the effects of neurodegenerative diseases, potentially offering therapeutic benefits in conditions such as epilepsy and AD.

Again, the present findings of the LPS + CAP revealed a significant reduction in the concentration of NF-κB, TNF-α, IL-1β, Aβ level, ACE and AChE activity, accompanied by a significant elevation of ChAT levels in the homogenate of the brain hippocampus. In line with the present study, Abareshi et al. [73] and Sahin et al. [76] indicated that the treatment with CAP decreased NF-κB concentration in the homogenate tissue. In addition, Asraf et al. [77] showed that RAS intervention by CAP ameliorated astrocytic and glial activation and reduced the production of TNF-α and IL-1β. Moreover, Bhat et al.

[78] attributed the anti-inflammatory mechanism of CAP to the inhibition of pro-inflammatory cytokine production and NF-κB as a result of ACE's reduction. Similarly, Mohapatra et al. [79] demonstrated that CAP can reduce Aβ-induced toxicity and improve cognitive functions through its anti-inflammatory effects. Furthermore, Tao et al. [80] revealed that CAP employs competitive inhibition to reduce ACE activity by attaching itself to the ACE's active site, preventing angiotensin I from becoming angiotensin II. This reduction in angiotensin II levels leads to diminishing the inflammatory response mediated by angiotensin II in various tissues, including the brain. Also, the findings of the present study are in accordance with Arkhipov et al. [81] and Beheshti et al. [82], who revealed that CAP modulates the cholinergic system indirectly by reducing neuroinflammation as a result of decreasing angiotensin type II, which can impair acetylcholine synthesis and function. This creates a supportive environment for cholinergic neurons, enhancing their function, which plays a crucial role for learning, memory, and cognitive function.

Also, the LPS + CAP group revealed a significant increase in the CAT and SOD and a highly significant decrease in MDA in the homogenate of the brain hippocampus. These results are similar to those were previously explained by Abbassi et al. [83], Ali et al. [84], and Mohapatra et al. [79], who confirmed that CAP as a ACE inhibitor significantly improves cognitive function in LPS-induced dementia in rats by potentiating the antioxidant status of brain defense system by increasing the CAT and SOD content and decreased MDA production. Our observation could be attributed to the CAP ability to cross blood-brain barrier to decrease oxidative stress and increase antioxidant enzymes, modulation of inflammatory cytokines, and inhibition of the RAS as documented by Abareshi et al. [28], Abiodun et al. [85], and Messiha et al. [86].

The hippocampal tissues of the LPS + CAP group retained its normal appearance to some extent relative to the LPS group. The SP in the CA1 region appeared with 2–3 spaced layers, a decline in the pyknotic nuclei of the pyramidal cells, decreased vacuolization, and reduction of the proliferation of glial cells in both the SO and SR. These results are in good concern with several studies accomplished by Fazal et al. [87] and Mohapatra et al. [79], who revealed that neurodegeneration was fewer in CAP-treated rats, and it exhibited improved and organized neuronal glial cells in comparison to the LPS-administered group.

The present study could be attributes captopril's neuroprotective effect to the opinion of Nestor et al. [88], Asraf et al. [77], and Abiodun et al. [85], who confirmed that CAP treatment reduced the number of damaged neurons in the hippocampus by modulation of the RAS and, as a result, ACE is reduced, which can influence cerebral blood flow and possibly affect brain tissue structure and decrease inflammatory responses in the brain, leading to improved histological changes.

Again, the current data demonstrated a moderate expression of caspase-3 and IL-6 in the LPS + CAP group compared to the LPS group. In the same line, Tzeng et al. [89] found that CAP controlled caspase-3 because it had neuroprotective effects via modifying apoptotic pathways, which are consistent with our findings. Our observation could be attributed to the explanation of Abareshi et al. [28], who confirmed that CAP has anti-inflammatory characteristics by reducing the release of inflammatory cytokines such as IL-6, hence alleviating neuroinflammation.

The current study focused on crocin, as a natural compound that alleviates LPS-induced behavioral, biochemical, histopathological, and immunohistochemical abnormalities associated with memory impairments. Behavioral tests are frequently engaged to estimate crocin's effects on AD [90]. Our present data showed that the oral administration of CR in LPS + CR and LPS + CAP + CR groups showed a highly significant increase in behavioral tests. The present study is in consonance with the findings of Pitsikas and Tarantilis [91] and Radahmadi et al. [92], who postulated that CR mitigates the deleterious effect of LPS on memory impairment by elevating discrimination ratio, ratio index, and % alternation. In the same context, Singh et al. [93] and Mazumder et al. [24] clarified that the inhibitory effect of CR against learning and memory impairments in behavioral tests induced by LPS occurs through multiple mechanisms. The improvement in behavioral test performance following CR administration could be due to its neuroprotective and its anti-inflammatory properties leading to enhanced memory and learning abilities [94].

Interestingly, the present findings from the LPS + CR and LPS + CAP + CR groups revealed a highly significant reduction in the concentrations of NF-κB, TNF-α, IL-1β, Aβ, ACE, and AChE activity, along with a highly significant elevation of ChAT levels in the homogenate of the brain hippocampus. These observations are consistent with several studies demonstrated that CR modulates NF-κB levels in the brain by crossing the blood-brain barrier and reaching the central nervous system, thereby enhancing its therapeutic potential [94–96].

Additionally, studies by Sadoughi [97] and Haeri et al. [98] indicated that CR alleviates inflammation in AD by targeting multiple pathways, such as reducing pro-inflammatory cytokines like TNF-α and IL-1β. In line with these findings, the reduction in these parameters in our study can be interpreted according to the opinions of Hosseini et al. [99] and Samieri et al. [100], who reported that CR dampens the inflammatory response

by several mechanisms, including blocking NF-κB translocation to the nucleus, regulating inflammatory mediators, and reducing microglial activation. Furthermore, crocin reduces the expression of pro-inflammatory markers such as TNF-α and IL-1β, which are elevated in LPS-treated models [27, 101].

Similarly, CR administration reduces Aβ accumulation due to its neuroprotective and antioxidant properties, as well as its positive effects on synaptic function [95, 102]. Additionally, CR attenuates Aβ accumulation at multiple levels, including regulating amyloid precursor protein (APP) cleavage to divert it from the amyloidogenic pathway, enhancing Aβ clearance through the stimulation of enzymes like neprilysin and autophagy pathways, and exerting anti-inflammatory effects [103].

In agreement with our findings, Ghasemnejad-Berenji [104] and Bastani et al. [105] documented that CR treatment reduces ACE levels and improves learning and memory. Similarly, Khalil et al. [106] demonstrated that CR alleviates ACE activity by blocking inflammatory pathways like NF-κB, which indirectly reduces ACE upregulation associated with inflammation. Crocin's neuroprotective effects help restore balance in the renin-angiotensin system, thereby inhibiting ACE activity and reducing the production of angiotensin II.

Crocin's ability to alter major cholinergic system components makes it a promising therapeutic treatment for illnesses associated with cholinergic dysfunction. Cr can reduce AChE and improve the level of ChAT [107], and it helps to maintain healthy ACh levels, which are essential for learning and memory [108]. The possible interpretation the present data proved that CR inhibits AChE activity and so increases synaptic availability. It can also influence cholinergic function by increasing ChAT expression or activity, which promotes the production of ACh. This helps to restore cholinergic neurotransmission and treats cognitive impairments [109, 110].

Again, our data showed that there were a highly significant increase in the CAT and SOD and a highly significant decrease in the MDA level in the LPS + CR and LPS + CAP + CR groups in the homogenate of the brain. Parallel with our results, several reports proved that CR increased CAT and SOD levels and also decreased the MDA level in the brain of treated groups [64, 108, 111]. The possible interpretation is provided by Farkhondeh et al. [111], who stated that crocin by scavenging the free radicals is capable of protecting the cells against oxidative stress damages. Also, more explanation is revealed by Salem et al. [112] who elucidated that CR enhances antioxidant enzyme levels, thereby decreasing oxidative stress markers like malondialdehyde. Also, CR acts as anti-inflammatory agent by inhibiting the expression of pro-inflammatory cytokines and enzymes, thereby reducing inflammation-induced oxidative stress. This reduction in inflammation contributes to lower MDA levels and increased antioxidant enzyme activities.

The histological examination of the hippocampal tissue in the LPS + CR group and the LPS + CAP + CR group exposed that the hippocampal construction reserved its normal appearance to a large extent compared with the LPS group hippocampus. The SP in the CA1 region displayed marked improvement, with neurons appearing with normal morphology. Furthermore, a normal distribution of glial cells and well-preserved blood capillaries were observed in the SO and SR, reflecting restored structural integrity. These results are in line with Salem et al. [112] and Hashemzaei et al. [113], who showed that after CR treatment, the hippocampal tissues appeared without any neuronal loss, with good glial cells distribution and a healthy structure to blood capillaries.

As well as, in the current study, caspase-3 and IL-6 in the CR groups (LPS + CR and LPS + CAP + CR) showed weak expression in hippocampal tissues compared with the LPS group. Similar observations were made by D'amelio et al. [114] and Dastan et al. [115], who observed that CR can decrease caspase-3 expression and reduce levels of IL-6, which is convoluted in neuroinflammation. We attribute the reduction of caspase-3 and IL-6 according to the opinion of Shahbaz et al. [116] and Yang et al. [117], who emphasized that crocin, has anti-apoptotic and anti-inflammatory properties.

The possible elucidation of the neuroprotective effects of CR that are displayed in the present study is consistant with Dastan et al. [115], who demonstrated that the protective effects of CR against LPS-induced histological changes in the brain occur through several mechanisms, such as anti-inflammatory effects, antioxidant properties, reduction of oxidative stress, and anti-apoptotic activity, all of which help to restore the normal appearance of the hippocampus. Also, this action of CR was explained by Shahidani et al. [118], who stated that crocin can stimulate biological activity that may enhance developmental and hippocampal neurogenesis and neuronal repair.

Conclusion

The present study demonstrated that LPS exposure activates NF-κB signaling and increases pro-inflammatory cytokines, thereby influencing Aβ production through NF-κB and ACE activity. LPS also impairs cholinergic neurons and promotes oxidative stress, accelerating memory deficits, while histological and immunohistochemical analyses confirmed hippocampal damage and increased immunostaining. In contrast, CR exhibited multi-target ameliorative mechanisms by attenuating NF-κB activation, reducing inflammatory cytokines, decreasing ACE activity, and enhancing both Aβ clearance and cholinergic function. Furthermore, CR improved the antioxidant defense system by modulating

SOD and CAT activity, restoring the balance between oxidative stress and antioxidant capacity. Importantly, this study highlights crocin's multifaceted role in improving behavioral outcomes and mitigating neuroinflammation, oxidative stress, and histological alterations, all of which are critical in neurodegenerative conditions. These findings not only expand the current understanding of crocin's mechanisms but also suggest its possible translational value as a natural therapeutic candidate for oxidative stress–related neurodegenerative disorders. While the study presents compelling evidence for crocin's protective effects, it is essential to consider that the complexity of neurodegenerative diseases may require multifactorial approaches beyond single compounds like crocin for effective treatment strategies.

Abbreviations

LPS	lipopolysaccharide
CAP	captopril
CR	crocin
NF-κB	nuclear factor kappa B
TNF-α	tumor necrosis factor-alpha
IL-1β	interleukin-1Beta
Aβ	amyloid beta
ACE	angiotensin converting enzyme
AChE	acetyle cholinesterase
ChAT	choline acetyle transferase
CAT	Catalase
SOD	superoxide dismutase
MDA	malondialdehyde

Acknowledgements
The authors would like to thank the Department of Zoology, Faculty of Science, Aswan University (Egypt).

Author contributions
Abd El Kader, M. A. designed the experiments. Eatemad, A. A., and Ola, M. performed the experiments. The first draft of the manuscript was written by Ahmed, M., Huda, S., and Ola, M. All authors provided comments on previous versions of the manuscript, read, and approved the final version.

Funding
Open access funding provided by The Science, Technology & Innovation Funding Authority (STDF) in cooperation with The Egyptian Knowledge Bank (EKB). This research did not receive any grant from funding agencies in the public, commercial, or not-for-profit sectors.

Data availability
This article contains all the data that was created or evaluated during the research.

Declarations

Ethics approval and consent to participate
The Animal Ethical Committee of Aswan University in Aswan, Egypt, approved all experimental methods, which were conducted in compliance with regional institutional policies. Ethical approval code ASWU/05/SC/ZO/24 – 01/0.

Consent for publication
Not applicable.

Competing interests
The authors declare no competing interests.

Author details
[1]Department of Zoology, Faculty of Science, Aswan University, Aswan 81511, Egypt
[2]Department of Medical Biochemistry, Faculty of Medicine, Aswan University, Aswan 81511, Egypt

Received: 4 March 2025 / Accepted: 7 October 2025
Published online: 25 November 2025

References

1. Calin M, Manduteanu I. Emerging nanocarriers-based approaches to diagnose and reduce vascular inflammation in atherosclerosis. Curr Med Chem. 2017;24(6):550–67.
2. Anaeigoudari A, Soukhtanloo M, Reisi P, Beheshti F, Hosseini M. Inducible nitric oxide inhibitor aminoguanidine ameliorates deleterious effects of lipopolysaccharide on memory and long-term potentiation in rats. Life Sci. 2016;158:22–30.
3. Whitton PS. Inflammation as a causative factor in the aetiology of parkinson's disease. Br J Pharmacol. 2007;150(8):963–76.
4. Zhao W, Xie W, Le W, Beers DR, He Y, Henkel JS, et al. Activated microglia initiate motor neuron injury by a nitric oxide and glutamate-mediated mechanism. J Neuropathol Exp Neurol. 2004;63(9):964–77.
5. Walter S, Neumann H, Golenbock DT, Weber JR. The LPS receptor, CD14 in experimental autoimmune encephalomyelitis and multiple sclerosis. Cell Physiol Biochem. 2006;17(3–4):167–72.
6. Thompson KJ, Tobin AB. Crosstalk between the M1 muscarinic acetylcholine receptor and the endocannabinoid system: A relevance for alzheimer's disease? Cell Signal. 2020;70:109545.
7. Lin CC, Kuo IC, Wu LW, Kuo ML, Lee HC, Lee TS. Up-regulation of COX-2/PGE2 by endothelin-1 via MAPK-dependent NF-κB pathway in mouse brain microvascular endothelial cells. Cell Communication Signal. 2013;11(1):8.
8. Gupta SC, Kim JH, Prasad S, Aggarwal BB. Regulation of survival, proliferation, invasion, angiogenesis, and metastasis of tumor cells through modulation of inflammatory pathways by nutraceuticals. Cancer Metastasis Rev. 2010;29(3):405–34.
9. Gupta SC, Sundaram C, Reuter S, Aggarwal BB. Inhibiting NF-κB activation by small molecules as a therapeutic strategy. Biochim Et Biophys Acta (BBA) - Gene Regul Mech. 2010;1799(10–12):775–87.
10. Hansen MK, O'Connor KA, Goehler LE, Watkins LR, Maier SF. Effects of vagotomy on serum endotoxin, cytokines, and corticosterone after intraperitoneal lipopolysaccharide. Am J Physiol - Regul Integr Comp Physiol. 2000;278(2):R331–6.
11. Lehnardt S, Massillon L, Follett P, Jensen FE, Ratan R, Rosenberg PA, et al. Activation of innate immunity in the CNS triggers neurodegeneration through a Toll-like receptor 4-dependent pathway. Proc Natl Acad Sci USA. 2003;100(14):8514–9.
12. Sun J, Wang L, Jiang Y, Zhao J, Zhang X, Zhang Y, et al. IL-17A is implicated in lipopolysaccharide-induced neuroinflammation and cognitive impairment in aged rats via microglial activation. J Neuroinflamm. 2015;12:1–12.
13. Zakaria R, Wan Yaacob WM, Othman Z, Long I, Ahmad AH, Al-Rahbi B. Lipopolysaccharide-induced memory impairment in rats: a model of alzheimer's disease. Physiol Res. 2017;66.
14. Muhammad T, Ikram M, Ullah R, Rehman SU, Kim MO. Hesperetin, a citrus flavonoid, attenuates LPS-induced neuroinflammation, apoptosis, and memory impairments by modulating TLR4/NF-κB signaling. Nutrients. 2019;11(3):648.
15. Torika N, Asraf K, Roasso E, Danon A, Fleisher-Berkovich S. Angiotensin converting enzyme inhibitors ameliorate brain inflammation associated with microglial activation: possible implications for alzheimer's disease. J Neuroimmune Pharmacol. 2016;11(4):774–85.
16. AbdAlla S, Langer A, Fu X, Quitterer U. Quitterer, U. ACE Inhibition with Captopril retards the development of signs of neurodegeneration in an animal model of alzheimer's disease. Int J Mol Sci. 2013;14(8):16917–42.
17. Arjmand Abbassi Y, Mohammadi M, Eidi A. Protective effects of captopril and valsartan on memory function and gene expression of brain-derived neurotrophic factor (BDNF) in experimental model of alzheimer's disease in rats. 2015;23(100):22–35.
18. Mostafa F, Mantawy EM, Said RS, Azab SS, El-Demerdash E. Captopril attenuates oxidative stress and neuroinflammation implicated in cisplatin-induced cognitive deficits in rats. Psychopharmacology. 2025;242(3):563–78.

19. Kar F, Hacioglu C, Uslu S, Kanbak G. Curcumin acts as post-protective effects on rat hippocampal synaptosomes in a neuronal model of aluminum-induced toxicity. Neurochem Res. 2019;44:2020–9.
20. Xi L, Qian Z, Shen X, Wen N, Zhang Y. Crocetin prevents dexamethasone-induced insulin resistance in rats. Planta Med. 2005;71(10):917–22.
21. Wang C, Wang C, Gao W, Zhang T, Shi B, Zhou X, et al. Investigation of the neuroprotective effects of Crocin via antioxidant activities in HT22 cells and in mice with alzheimer's disease. Int J Mol Med. 2019;43:956–66.
22. Ajami A, Hosseini SH, Taghipour M, Khalilian A. Changes in serum levels of brain-derived neurotrophic factor and nerve growth factor-beta in schizophrenic patients before and after treatment. Scand J Immunol. 2014;80(1):36–42.
23. Latif A, Parveen S, Malik I, Ullah N, Khan AR, Ahmad S, et al. New multitarget directed benzimidazole-2-thiol-based heterocycles as prospective anti-radical and anti-Alzheimer's agents. Drug Dev Res. 2021;82(2):207–16. 21.
24. Mazumder AG, Sharma P, Patial V, Singh D. Crocin attenuates kindling development and associated cognitive impairments in mice via inhibiting reactive oxygen species-mediated NF-κB activation. Basic Clin Pharmacol Toxicol. 2017;120(5):426–33.
25. Lv B, Huo F, Zhu Z, Xu Z, Dang X, Chen T, et al. Crocin upregulates CX3CR1 expression by suppressing NF- κB/YY1 signaling and inhibiting lipopolysaccharide-induced microglial activation. Neurochem Res. 2016;41:1949–57.
26. Papandreou MA, Tsachaki M, Efthimiopoulos S, Cordopatis P, Lamari FN, Margarity M. Memory enhancing effects of saffron in aged mice are correlated with antioxidant protection. Behav Brain Res. 2011;219:197–204.
27. Ghotbeddin Z, Tabandeh MR, Pourmahdi Borujeni M, Fahimi Truski F, Zalaki Ghorbani Pour MR, Tabrizian L. Crocin mitigated cognitive impairment and brain molecular alterations induced by different intensities of prenatal hypoxia in neonatal rats. Brain Behav. 2021;11(4):e02078.
28. Abareshi A, Hosseini M, Beheshti F, Norouzi F, Khazaei M, Sadeghnia HR, et al. The effects of Captopril on lipopolysaccharide-induced learning and memory impairments and the brain cytokine levels and oxidative damage in rats. Life Sci. 2016;167:46–56.
29. Yuan Y, Zhou J, Ma L, Liu X, Wang T, Zheng Y, et al. The effect of Crocin on memory, hippocampal acetylcholine level, and apoptosis in a rat model of cerebral ischemia. Biomed Pharmacother. 2020;130:110543.
30. Onaolapo AY, Onaolapo OJ. Caffeine's influence on object recognition and working memory in prepubertal mice and its modulation by gender. Pathophysiology. 2015;22(4):223–30.
31. Grzeda E, Wiśniewska RJ, Wiśniewski K. Effect of an NMDA receptor agonist on T-maze and passive avoidance test in 12-week streptozotocin-induced diabetic rats. Pharmacol Rep. 2007;59(6):656–63.
32. Ellman GL, Courtney KD, Andres JRV, Featherstone RA. A new and rapid colorimetric determination of acetylcholinesterase activity. Biochem Pharmacol. 1961;7(2):88–95.
33. Aebi H. Catalase in vitro. Methods Enzymol. 1984;105:121–6.
34. Beauchamp C, Fridovich I. Superoxide dismutase: improved assays and an assay applicable to acrylamide gels. Anal Biochem. 1971;44(1):276–87.
35. Ohkawa H, Ohishi N, Yagi K. Assay for lipid peroxides in animal tissues by thiobarbituric acid reaction. Anal Biochem. 1979;95(2):351–8.
36. Harris HF. On the rapid conversion of haematoxylin into haematein in staining reactions. J Appl Microscopy. 1900;3(3):777–80.
37. Boitard C, Cavaroc A, Sauvant J, Aubert A, Castanon N, Layé S, Brain, et al. Behav Immun. 2014;40:9–17.
38. Frühauf PKS, Porto Ineu R, Tomazi L, Duarte T, Mello CF, Rubin MA. Spermine reverses lipopolysaccharide-induced memory deficit in mice. J Neuroinflamm. 2015;12:1–11.
39. Khan MS, Muhammad T, Ikram M, Kim MO. Dietary supplementation of the antioxidant Curcumin halts systemic LPS-induced neuroinflammation-associated neurodegeneration and memory/synaptic impairment via the JNK/NF-κB/Akt signaling pathway in adult rats. Oxidative Med Cell Longev. 2019;1:7860650.
40. Alshehri S, Imam SS. Rosinidin attenuates lipopolysaccharide-induced memory impairment in rats: possible mechanisms of action include antioxidant and anti-inflammatory effects. Biomolecules. 2021;11(12):1747.
41. Bassi GS, Kanashiro A, Coimbra NC, Terrando N, Britto LRG, Cunha FQ, et al. Lipopolysaccharide-induced sickness behaviour evaluated in different models of anxiety and innate fear in rats. Basic Clin Pharmacol Toxicol. 2012;110(4):359–69.
42. Okuyama S, Makihata N, Kubota Y, Egashira N, Imuta M, Yamada S, et al. Suppresses lipopolysaccharide-induced inflammation in the mouse brain. Int J Mol Sci. 2013;14(5):9767–78.
43. Lee B, Sur B, Yeom M, Shim I, Lee H, Hahm DH. Ginsenoside Rg3 alleviates lipopolysaccharide-induced learning and memory impairments by anti-inflammatory activity in rats. Biomolecules Ther. 2013;21(5):381.
44. Smith JA, Das A, Ray SK, Banik NL. Role of pro-inflammatory cytokines released from microglia in neurodegenerative diseases. Brain Res Bull. 2012;87(1):10–20.
45. Kranjac D, McLinden KA, Kljakic O, Funes S, Benner J, Zhang Y, et al. Peripheral bacterial endotoxin administration triggers both memory consolidation and reconsolidation deficits in mice. Brain Behav Immun. 2012;26:109–21.
46. Sharma R, Lee S, Choi TG, Jung Y, Kim J, Kim YS, et al. Dendrimer-mediated targeted delivery of Sinomenine for the treatment of acute neuroinflammation in traumatic brain injury. J Controlled Release. 2020;323:361–75.
47. Sun E, Motolani A, Campos L, Lu T. The pivotal role of NF-κB in the pathogenesis and therapeutics of alzheimer's disease. Int J Mol Sci. 2022;23:8972.
48. Zhan X, Stamova B, Sharp FR. Lipopolysaccharide associates with amyloid plaques, neurons, and oligodendrocytes in alzheimer's disease brain: A review. Front Aging Neurosci. 2018;10:42.
49. Covert MW, Leung TH, Gaston JE, Baltimore D. Achieving stability of lipopolysaccharide-induced NF-κB activation. Science. 2005;309:1854–7.
50. Rahim NS, Abdul-Rahman PS, Renu K, Leong XF, Asmadi AY, Budin SB, et al. Virgin coconut oil-induced neuroprotection in lipopolysaccharide-challenged rats is mediated, in part, through cholinergic, anti-oxidative, and anti-inflammatory pathways. J Diet Supplements. 2021;18:655–81.
51. Choe K, Kim J, Han J, Lee Y, Park JH, Kim S, et al. Lupeol protects against LPS-induced neuroinflammation and amyloid beta in adult mouse hippocampus. Front Nutr. 2024;11:1414696.
52. Feng V, Liu X, Yu T, Zhang Y, Wu H, Zhao J, et al. Lipopolysaccharide, immune biomarkers, and cerebral amyloid-beta deposition in older adults with mild cognitive impairment and major depressive disorder. Am J Geriatric Psychiatry. 2023;31:786–95.
53. Dang R, Liu X, Wang X, Wang W, Ding J, Chen S, et al. Activation of angiotensin-converting enzyme 2/angiotensin (1–7)/Mas receptor axis triggers autophagy and suppresses microglia Proinflammatory polarization via forkhead box class O1 signaling. Aging Cell. 2021;20:e13480.
54. Ahmad SF, Zoheir KM, Abdel-Hamied HE, Attia SM, Bakheet SA, Ashour AE, et al. Regulation of TNF-α and NF-κB activation through the JAK/STAT signaling pathway downstream of Histamine 4 receptor in a rat model of LPS-induced joint inflammation. Immunobiology. 2015;220:889–98.
55. Urmila A, Rashmi P, Nilam G, Subhash B. Recent advances in the endogenous brain renin-angiotensin system and drugs acting on it. J Renin-Angiotensin-Aldosterone Syst. 2021;9293553.
56. Gong X, Hu H, Qiao Y, Xu P, Yang M. The involvement of renin-angiotensin system in lipopolysaccharide-induced behavioral changes, neuro-inflammation, and disturbed insulin signaling. Neuropharmacology. 2019;10.
57. Bekdash RA. The cholinergic system, the adrenergic system, and the neuropathology of alzheimer's disease. Int J Mol Sci. 2021;22:1273. https://doi.org/10.3390/ijms22031273.
58. Liu Y, Ma W, Zhang P, He S, Huang D, Wang H, et al. Galantamine improves cognition, hippocampal inflammation, and synaptic plasticity impairments induced by lipopolysaccharide in mice. J Neuroinflamm. 2018;15:1–15. https://doi.org/10.1186/s12974-018-1141-5.
59. Mitra S, Behbahani H, Eriksdotter M. Innovative therapy for alzheimer's disease—with focus on biodelivery of NGF. Front NeuroSci. 2019;13:38.
60. Llorente-Ovejero A, Solé M, Pavia J, Giménez-Llort L, Villegas S. Specific phospholipid modulation by muscarinic signaling in a rat lesion model of alzheimer's disease. ACS Chem Neurosci. 2021;12:2167–81.
61. Luo H, Jin Y, Kim ID, Lee JK. Apelin-13 suppresses neuroinflammation against cognitive deficit in a streptozotocin-induced rat model of alzheimer's disease through activation of BDNF-TrkB signaling pathway. Front Pharmacol. 2019;10:395.
62. Li Y, Li P, Xu Y, Li Y, Jiang B, Xie J, et al. Circular RNA expression profile of alzheimer's disease and its clinical significance as biomarkers for the disease risk and progression. Int J Biochem Cell Biol. 2020;123:105747.
63. Sadraie S, Golmohammadi T, Barzegar-Fallah A, Azizi-Malekabadi H, Khaksari M, Momeny M, et al. Berberine ameliorates lipopolysaccharide-induced learning and memory deficit in the rat: insights into underlying molecular mechanisms. Metab Brain Dis. 2018;34:245–55.
64. Wang H, Guo C, Li Y, Yang W, Hu Y, Zhang D, et al. Mogrol attenuates lipopolysaccharide (LPS)-induced memory impairment and neuroinflammatory responses in mice. J Asian Nat Prod Res. 2019;22:864–78.

65. Ayala A, Muñoz MF, Argüelles S. Lipid peroxidation: production, metabolism, and signaling mechanisms of malondialdehyde and 4-hydroxy-2-nonenal. Oxid Med Cell Longev. 2014;360438.
66. Essadek S, Smaili S, El Arfaoui L, Taleb H, Mouzdahir Z, Boulbaroud S, et al. Effects of a short-term lipopolysaccharide challenge on mouse brain and liver peroxisomal antioxidant and β-oxidative functions: protective action of Argan oil. Pharmaceuticals. 2022;15(4):465.
67. Bahaidrah KA, Alzahrani NA, Aldhahri RS, Mansouri RA, Alghamdi BS. Effects of different lipopolysaccharide doses on short- and long-term Spatial memory and hippocampus morphology in an experimental alzheimer's disease model. Clin Translational Neurosci. 2022;6(3):20.
68. He Q, Qi Q, Ibeanu GC, Li PA. B355252 suppresses LPS-induced neuroinflammation in the mouse brain. Brain Sci. 2024;14(5):467.
69. Nazanin K, Bagher S. Antioxidant, histopathological and biochemical outcomes of short-term exposure to LPS in liver and brain of rat: the protective role of N-acetylcysteine and S-methylcysteine. Saudi Pharm J. 2021;29(3):280–9.
70. Beurel E, Jope RS. Lipopolysaccharide-induced interleukin-6 production is controlled by glycogen synthase kinase-3 and STAT3 in the brain. J Neuroinflammation. 2009;6:9.
71. Sangaran PG, Ibrahim ZA, Chik Z, Mohamed Z, Ahmadiani A. LPS preconditioning attenuates apoptosis mechanism by inhibiting NF-κB and caspase-3 activity: TLR4 pre-activation in the signaling pathway of LPS-induced neuroprotection. Mol Neurobiol. 2021;58:2407–22.
72. Zhang H, Guo M, Yu J, Li Y, Zhao Y, Zhang J, et al. Inhibitory effect of fasudil on activation and inflammatory response of mouse astrocytes induced by lipopolysaccharide and its mechanism. Cell Mol Immunol. 2018;34(6):505–10.
73. Abareshi A, Anaeigoudari A, Norouzi F, Marefati N, Beheshti F, Saeedjalali M, et al. The effects of Captopril on lipopolysaccharide-induced sickness behaviors in rats. Vet Res Forum. 2019;10(3):199–204.
74. Dong X, Fan J, Lin D, Wang X, Kuang H, Gong L, et al. Captopril alleviates epilepsy and cognitive impairment by Attenuation of C3-mediated inflammation and synaptic phagocytosis. J Neuroinflammation. 2022;19(1):226.
75. Hou DR, Wang Y, Zhou L. Altered angiotensin-converting enzyme and its effects on the brain in a rat model of alzheimer's disease. Chin Med J (Engl). 2008;121(22):2320–3.
76. Sahin B, Ergul MC. Captopril exhibits protective effects through anti-inflammatory and anti-apoptotic pathways against hydrogen peroxide-induced oxidative stress in C6 glioma cells. Metab Brain Dis. 2022;37(4):1221–30.
77. Asraf K, Torika N, Apte RN, Fleisher-Berkovich S. Microglial activation is modulated by captopril: in vitro and in vivo studies. Front Cell Neurosci. 2018;12:116.
78. Bhat SA, Goel R, Shukla R, Hanif K. Angiotensin receptor Blockade modulates NF-κB and STAT3 signaling and inhibits glial activation and neuroinflammation better than angiotensin-converting enzyme Inhibition. Mol Neurobiol. 2016;53:6950–67.
79. Mohapatra S, Andrew S, Paula S. SARS-CoV-2 infection increases the gene expression profile for alzheimer's disease risk. Methods Clin Dev. 2022;27:217–29.
80. Tao MX, Xue X, Gao L, Lu JL, Zhou JS, Jiang T, et al. Involvement of angiotensin-(1–7) in the neuroprotection of Captopril against focal cerebral ischemia. Neurosci Lett. 2018;687:16–21.
81. Arkhipov VI, Pershina EV, Levin S. The role of anti-inflammatory cytokines in memory processing in a healthy brain. Behav Brain Res. 2019;367:111–6.
82. Beheshti F, Akbari HR, Baghcheghi Y, Mansouritorghabeh F, Mortazavi Sani SS, Hosseini M. Beneficial effects of angiotensin-converting enzyme Inhibition on scopolamine-induced learning and memory impairment in rats: the roles of brain-derived neurotrophic factor, nitric oxide and neuroinflammation. Clin Exp Hypertens. 2021;43(6):505–15.
83. Abbassi YA, Mohammadi MT, Foroshani MS, Sarshoori JR. Captopril and Valsartan May improve cognitive function through potentiation of the brain antioxidant defense system and Attenuation of oxidative/nitrosative damage in STZ-induced dementia in rats. Adv Pharm Bull. 2016;6(4):531.
84. Ali MRAA, Abo-Youssef AMH, Messiha BAS, Khattab MM. Tempol and Perindopril protect against lipopolysaccharide-induced cognition impairment and amyloidogenesis by modulating brain-derived neurotrophic factor, neuroinflammation and oxido-nitrosative stress. Naunyn Schmiedebergs Arch Pharmacol. 2016;389:637–56.
85. Abiodun OA, Ola MS. Role of brain renin-angiotensin system in neurodegeneration: an update. Saudi J Biol Sci. 2020;27(3):905–12.
86. Messiha BA, Ali MR, Khattab MM, Abo-Youssef AM. Perindopril ameliorates experimental alzheimer's disease progression: role of amyloid β degradation, central Estrogen receptor and hyperlipidemic-lipid raft signaling. Inflammopharmacology. 2020;28:1343–64.
87. Fazal K, Perera G, Khondoker M, Howard R, Stewart R. Associations of centrally acting ACE inhibitors with cognitive decline and survival in alzheimer's disease. BJPsych Open. 2017;3(4):158–64.
88. Nestor J, Arinuma Y, Huerta TS, Kowal C, Nasiri E, Kello N, et al. Lupus antibodies induce behavioral changes mediated by microglia and blocked by ACE inhibitors. J Exp Med. 2018;215(10):2554–66.
89. Tzeng TT, Tsay HJ, Chang L, Hsu CL, Lai TH, Huang FL, et al. Caspase 3 involves in neuroplasticity, microglial activation and neurogenesis in the mice hippocampus after intracerebral injection of Kainic acid. J Biomed Sci. 2013;20:1–16.
90. Antunes M, Biala G. The novel objects recognition memory: neurobiology, test procedure, and its modifications. Cogn Process. 2012;13:93–110.
91. Pitsikas N, Tarantilis PA. Crocins, the active constituents of crocus sativus L., counteracted apomorphine-induced performance deficits in the novel object recognition task, but not novel object location task, in rats. Neurosci Lett. 2017;644:37–42.
92. Radahmadi M, Hosseini DA, Pourshanazari AA. Effects of Crocin on locomotor activity as well as novel object recognition and object location memories in chronic restraint stressed rats. Physiol Pharmacol. 2020;24(2):123–32.
93. Singh D. Neuropharmacological aspects of crocus sativus L.: A review of preclinical studies and ongoing clinical research. CNS Neurol Disord Drug Targets. 2015;14(7):880–902.
94. Dastgerdi AH, Radahmadi M, Pourshanazari AA, Dastgerdi HH. Effects of Crocin on learning and memory in rats under chronic restraint stress with special focus on the hippocampal and frontal cortex corticosterone levels. Adv Biomed Res. 2017;6(1):157.
95. Cirmi S, Ferlazzo N, Lombardo GE, Ventura-Spagnolo E, Gangemi S, Calapai G, et al. Neurodegenerative diseases: might citrus flavonoids play a protective role? Molecules. 2016;21(10):1312.
96. Zhang L, Previn R, Lu L, Liao RF, Jin Y, Wang RK. Crocin, a natural product, attenuates lipopolysaccharide-induced anxiety and depressive-like behaviors through suppressing NF-κB and NLRP3 signaling pathway. Brain Res Bull. 2018;142:352–9.
97. Sadoughi D. The effect of Crocin on apoptotic, inflammatory, BDNF, Pt, and Aβ40 indicators and neuronal density of CA1, CA2, and CA3 regions of hippocampus in the model of alzheimer suffering rats induced with Trimethyltin chloride. Comp Clin Pathol. 2019;28(5):1403–13.
98. Haeri P, Mohammadipour A, Heidari Z, Ebrahimzadeh-Bideskan A. Neuroprotective effect of Crocin on substantia Nigra in MPTP-induced parkinson's disease model of mice. Anat Sci Int. 2019;94:119–27.
99. Hosseini A, Razavi BM, Hosseinzadeh H. Pharmacokinetic properties of saffron and its active components. Eur J Drug Metab Pharmacokinet. 2018;43:383–90.
100. Samieri C, Perier MC, Gaye B, Proust-Lima C, Helmer C, Dartigues JF, et al. Association of cardiovascular health level in older age with cognitive decline and incident dementia. JAMA. 2018;320(7):657–64.
101. Dastan M, Rajaei Z, Sharifi M, Salehi H. Crocin improves cognitive impairment in LPS-treated rats by anti-apoptotic, anti-inflammatory and antioxidant activities. 2024.
102. Alizadehmoghaddam S, Pourabdolhossein F, Najafzadehvarzi H, Sarbishegi M, Saleki K, Nouri HR. Crocin attenuates the lipopolysaccharide-induced neuroinflammation via expression of AIM2 and NLRP1 inflammasome in an experimental model of parkinson's disease. Heliyon. 2024;10.
103. Yousefsani BS, Mehri S, Pourahmad J, Hosseinzadeh H. Protective effect of Crocin against mitochondrial damage and memory deficit induced by beta-amyloid in the hippocampus of rats. Iran J Pharm Res. 2021;20(2):79.
104. Ghasemnejad-Berenji M. Immunomodulatory and anti-inflammatory potential of Crocin in COVID-19 treatment. J Food Biochem. 2021;45(5):e13718.
105. Bastani S, Vahedian V, Rashidi M, Mir A, Mirzaei S, Alipourfard I, et al. An evaluation on potential anti-oxidant and anti-inflammatory effects of Crocin. Biomed Pharmacother. 2022;153:113297.
106. Khalil A, Tazeddinova D, Aljoumaa K, Kazhmukhanbetkyzy ZA, Orazov A, Toshev AD. Carotenoids: therapeutic strategy in the battle against viral emerging diseases, COVID-19: an overview. Prev Nutr Food Sci. 2021;26(3):241.
107. Saeedi M, Rashidy-Pour A. Association between chronic stress and alzheimer's disease: therapeutic effects of saffron. Biomed Pharmacother. 2021;133:110995.

108. Krishnaswamy VKD, Alugoju P, Periyasamy L. Effect of short-term oral supplementation of Crocin on age-related oxidative stress, cholinergic, and mitochondrial dysfunction in rat cerebral cortex. Life Sci. 2020;263:118545.
109. Geromichalos GD, Lamari FN, Papandreou MA, Trafalis DT, Margarity M, Papageorgiou A, et al. Saffron as a source of novel acetylcholinesterase inhibitors: molecular Docking and in vitro enzymatic studies. J Agric Food Chem. 2012;60(24):6131–8.
110. Ahmad AS, Ansari MA, Ahmad M, Saleem S. Pharmacological potential of Crocin and Crocetin in improving cognitive deficits via modulation of oxidative stress and cholinergic function: implications in alzheimer's disease. ACS Omega. 2021;6(45):30541–52.
111. Farkhondeh T, Samarghandian S, Yazdi HS, Samini F. The protective effects of Crocin in the management of neurodegenerative diseases: A review. Am J Neurodegener Dis. 2018;7(1):1.
112. Salem M, Shaheen M, Tabbara A, Borjac J. Saffron extract and Crocin exert anti-inflammatory and anti-oxidative effects in a repetitive mild traumatic brain injury mouse model. Sci Rep. 2022;12(1):5004.
113. Hashemzaei M, Mamoulakis C, Tsarouhas K, Georgiadis G, Lazopoulos G, Tsatsakis A, et al. Crocin: A fighter against inflammation and pain. Food Chem Toxicol. 2020;143:111521.
114. D'amelio M, Cavallucci V, Cecconi F. Neuronal caspase-3 signaling: not only cell death. Cell Death Differ. 2010;17(7):1104–14.
115. Dastan M, Rajaei Z, Sharifi M, Salehi H. Crocin improves cognitive impairment in LPS-treated rats through anti-apoptotic, anti-inflammatory, and antioxidant activities. Mol Neurobiol. 2024;1–12.
116. Shahbaz K, Chang D, Zhou X, Low M, Seto SW, Li CG. Crocins for ischemic stroke: A review of current evidence. Front Pharmacol. 2022;13:825842.
117. Yang X, Liao KH, Deng IB, Zhang LC. Crocin plays a neuroprotective role against hypoxia-ischemia in neonatal rats via Inhibition of interleukin-6, caspase 3 and Bcl-2-associated X protein signaling pathway. Ibrain. 2022;8(3):413–28.
118. Shahidani S, Rajaei Z, Alaei H. Pretreatment with Crocin along with treadmill exercise ameliorates motor and memory deficits in Hemiparkinsonian rats by anti-inflammatory and antioxidant mechanisms. Metab Brain Dis. 2019;34:459–68.

Publisher's note

Springer Nature remains neutral with regard to jurisdictional claims in published maps and institutional affiliations.