Xi'an Shiyou Daxue Xuebao (Ziran Kexue Ban)/
Journal of Xi'an Shiyou University, Natural Sciences Edition
ISSN: 1673-064X
E-Publication: Online Open Access
Vol: 68 Issue 01 | 2025
DOI: 10.5281/zenodo.14723216

EFFECTS OF TOBACCO (*NICOTIANA TABACUM)* SMOKE ON LIPID PROFILE AND HEART STRUCTURE IN CHICKENS

JAWERIA FATIMA
M.Phill Researcher, School of Zoology Minhaj University Lahore. Email: javeriawaseem009@gmail.com

Dr. IRUM NAUREEN
Assistant Professor, School of Zoology, Minhaj University Lahore, Pakistan.
Email: dr.irumnaureen@mul.edu.pk

AISHA SALEEM*
Beijing University of Chemical Technology, School of Life Sciences, Beijing, China.
*Corresponding Author Email: aishasaleem160@gmail.com,
ORCID ID: https://orcid.org/0000-0003-4635-363.

HASSAM AHMED RAMAY
M.Phill Researcher, School of Zoology, Minhaj University Lahore. Email: hasamahmedramay@gmail.com

ASIFA MOBEEN
M.Phill Researcher, School of Zoology, Minhaj University Lahore. Email: asifamobeen29@gmail.com

Dr. AHSAN UL MOAZAM
Sindh Agriculture University, Tandojam. Email: moazamshabir78@gmail.com

ISHA AMAN
M.Phill Researcher, School of Zoology, Minhaj University Lahore. Email: eishaaman03@gmail.com

Abstract

Smoking is a worldwide problem and it affects both actively and passively. It affects the health of human being as well as animals. The smoking leads to the disturb whole system of the body and harms each organ of body. Tobacco smoke is expected to lead to heart failure and cardiomyopathy. Smoking has a direct impact on cardiovascular system. The objective of the current research study to evaluate effect of tobacco (*Nicotiana tabacum)* smoke on level of lipid profile in chickens and to determine the histopathological changes in heart tissue of chickens due to exposure of tobacco (*Nicotiana tabacum)* smoke. A set of 15 chickens were used for this research at the age of the chickens 16 weeks to 18 weeks. Chicken was divided in to three groups into control group, experimental group one and two. Cigarette were purchased from the market and given to the chickens in the form of tobacco smoke for 30 days. Passive smoking exposure technique was used. It was concluded that the lipid profile of experimental group one and two disturbed, the concentration of bad cholesterol e.g., LDL, total cholesterol, VLDL and triglycerides increased while the concentration of good cholesterol HDL decreased due to the passive smoking exposure. The histopathology of heart tissues of control group remained normal, no tissue changes were seen and cardiac muscles were normal, while the heart tissue of showed the mild congestion, shrinkage and atrophy of cardiac muscle fibers was seen and also mild congestion was seen in the myocardium.

Index Terms: Cardiovascular Disease, HDL, LDL, VLDL, *Nicotiana Tabacum.*

Xi'an Shiyou Daxue Xuebao (Ziran Kexue Ban)/
Journal of Xi'an Shiyou University, Natural Sciences Edition
ISSN: 1673-064X
E-Publication: Online Open Access
Vol: 68 Issue 01 | 2025
DOI: 10.5281/zenodo.14723216

1. INTRODUCTION

Smoking is a worldwide problem and it affects both actively and passively. It affects the health of human being as well as animals. Tobacco smoking is considered as higher risk of Cardiovascular disease and disturb whole system of the body and harms each organs, such as heart failure, and cardiomyopathy [1]. The word “tobacco" mentions to a variability of plants of the Solanaceae family genus Nicotiana [2]. 8 million people are killed each year due to smoking. The inhaling of such smoke is known as passive smoking. The words "passive smoking" and "exposure to ETS by nonsmokers" used interchangeably to describe the inhalation of passive smoking. One of the main modifiable risk factors for CAD (coronary artery disease) is passive smoking [3]. Passive smoking has an effect on the lipid profile and has the risk of heart disease. Poultry may become infected with several types of respiratory hazards such as smoking [4].Tobacco is chewed and sniffed very infrequently but smoked frequently. Tobacco products that are used in smoking form are kreteks, cigars, bidis and cigarrete. In 2020, there will still be a high prevalence of tobacco usage worldwide, with 7.8% of women and 36.7% of men using cigarettes (World Health Organization, 2021). Smoking was considered as responsible risk factor for 7 million fatalities and 177 million disabilities and emphasizing ongoing public health issue [5]. Tobacco use causes cancer, lung disease, strokes, cardiovascular disease, (CVD) **diabetes mellitus** and chronic obstructive pulmonary disease (COPD), which comprises pulmonary emphysema and lingering bronchitis. Tuberculosis, immune system issues and ocular disease enhanced due to tobacco smoking. Lung cancer and tobacco-related disease (92.7%), followed by COPD was (89.7%) and myocardial infarction was (84%) [6]. The smoke of cigarette or tobacco and hazardous chemicals that thicken the blood which block the arteries or blood vessel to swell or inflamed (plaque formation concept) effect of cardiovascular system [7].

A stroke is a damage of brain function brought on by an interruption in the blood flow to the brain. A stroke is considered as the important causes of disability and death worldwide in adult men and women and studies showed that due to smoking stroke occurred [8]. Heart attack may results this Coronary arteries disease, Cardiac arrest, Arrhythmias – such as atrial fibrillation, Failure of heart, Cardiogenic-shock [9]. The accumulation of the plaque inside the arteries the opening end narrowed and blood properly not transfer to the different parts of the body this condition called Atherosclerosis. Tobacco smoking promotes the formation of plaque in blood veins or arteries [10]. An abdominal aortic aneurysm (AAA) is a life intimidating issue and a bulge or weak spot that develops in the aorta's segment that runs through the abdomen. Smoking is a known factor in the early aortic damage that might result in an aneurysm. A ruptured abdominal aortic aneurysm poses a serious threat to life; smoking is virtually always the cause of abdominal aortic aneurysm deaths [11] PAD **(peripheral artery disease)** refers to atherosclerotic occlusion disease, which encompasses arterial stenosis and occlusion brought on by atherosclerotic plaques, arterial inflammation and thrombosis, arterial dilatation (AD), external pressure lesions peripheral artery dysfunction [12].

Xi'an Shiyou Daxue Xuebao (Ziran Kexue Ban)/
Journal of Xi'an Shiyou University, Natural Sciences Edition
ISSN: 1673-064X
E-Publication: Online Open Access
Vol: 68 Issue 01 | 2025
DOI: 10.5281/zenodo.14723216

2. RESEARCH DESIGN AND METHADOLOGY

2.1 Study area

This study was carried out at Minhaj University Lahore.

2.2 Animal Housing

Fifteen chickens at the age of 18 weeks were purchased from the University of Veterinary and Animal Sciences (UVAS) Lahore. The chickens were kept under wooden cage in the regulated environment in the animal house in Minhaj University Lahore. Cigarette were purchased from the market and given to the chickens in the form of tobacco smoke. Passive smoking exposure technique was used.

2.3 Divisions of the Groups

Animals were divided into following 3 groups. **Group 1**: (Control group 1) were remain untreated. **Group 2:** (Experimental group 1 -exposed to smoke of 4 cigarette /day) **Group 3:** (Experimental group 2 -exposed to the smoke of 2 cigarette /day). Control group was not exposed to the passive smoking while the experimental groups (EG1 and EG2) were exposed to cigarrete passive smoking 4 cigarrete and 2 cigarrete per day respectively.

2.4 Smoking Technique

Commonly two types of smoking techniques are used. Active Smoking and Passive Smoking. Active smoking is voluntarily inhalation of the tobacco smoke and while passive is involuntarily inhalation of smoke. In this research study passive smoking technique was used for the examination of lipid profile and heart structure of the chickens. This is also known as second-hand smoke (SHS). Passive smoking means inhalation of the tobacco smoke by the person other than smokers or indirect inhalation of smoke. Passive smoking exposure was provided for the duration of 30 days to the both experimental group 1(EG1) and experimental group (EG2) 2 with 4 cigarrete and 2 cigarrete per day respectively.

2.5 Collection of Blood

After completing the 30 days of experiment all chickens were dissected and blood serum was collected from all experimental and control group of chickens and blood was collected in dry and clean serum collection tubes allow to clot to separate out of serum. After centrifugation at 3000 rpm, serum was stored in an Eppendrof tube in refrigerator.

2.6 Chickens' dissection and organ weight

Body weight of each animal's was recorded at the start of the experiment as an initial weight and at the end of the experiment as a final weight. All the animals sacrificed in the animal house of zoology department Minhaj University Lahore. After collection of blood samples chickens were placed in dissection tray and all the organs were exposed. The heart of the chicken was exposed and separated after cutting with the help of forceps (tweezers) and scissor and organ weight was measured separately. After measuring the weight of each chicken heart, the heart samples of all groups were stored in 10% formalin

ISSN: 1673-064X
E-Publication: Online Open Access
Vol: 68 Issue 01 | 2025
DOI: 10.5281/zenodo.14723216

solution at 4^0C for histological analysis. Weight of heart was measured with help of digital weight balance in zoology lab of Minhaj University Lahore.

2.7 Histopathology of Heart

Chicken heart tissues were preserved in 10% formalin Solution for three days to avoid cross linking and deterioration. Tissue was embedded in molten form of paraffin wax before sectioning with micro-tome. For exposing the tissue, from the box surfaces wax was scraped. Before sectioning, on ice tray box were refrigerated for 10 minutes. Sections were created by rotating micro-tome. Tissue slices of 5µm (micrometer) were made and placed in hot water bath carefully then lifted to slides that were charged. Subsequently keeping at 37^0C for 120 minutes, all slides were labeled cautiously. Clear cells were stained by Hemotoxin and eosin respectively. The tissue was covered with cover slips and inspected under a microscope with low and high resolution.

2.8 Processing and Photography

Histology slides that were selected after being micro-photography, for the adjustment, clarity,re-sizing Adobe Photoshop was used and for cropping along with stars Snipping tool was used.

2.9 Statistical Analysis

Data analysis was done by using Graph Pad Prism version 11.0 and on experimental data unpaired t-test statistics was applied for determining the mean, standard deviation and p-value for each parameter. P value provides the possible significant effect of lipid profile in standard group and experimental groups.

3. RESULTS

In this study 15 chickens were used for experiment and examined the effects of Tobacco (*Nicotiana tabacum)* smoke on lipid profile and heart structure in chickens. Compare parameters to observe those statistically identifying similarities and distinction among them.

Table 1: After the consumption of feed and exposure of passive smoking the values of body weight gain in terms of (Mean ± SEM) of all animals all groups are following

Groups	Control Group (CG) (Kg)	Experimental Group1 (EG1) (Kg)	Experimental Group (EG2) (Kg)
Weight Gain	0.487±0.0259	0.462± 0.0455	0.471±0.044

Mean ± SEM is expressed values a= Control Vs Experimental group b= diet + exposed to smoke of 4 cigarette /day, c= diet + exposed to the smoke of 2 cigarette /day, $P < 0.05$*, $P<0.01$**, $P<0.001$**

Xi'an Shiyou Daxue Xuebao (Ziran Kexue Ban)/
Journal of Xi'an Shiyou University, Natural Sciences Edition
ISSN: 1673-064X
E-Publication: Online Open Access
Vol: 68 Issue 01 | 2025
DOI: 10.5281/zenodo.14723216

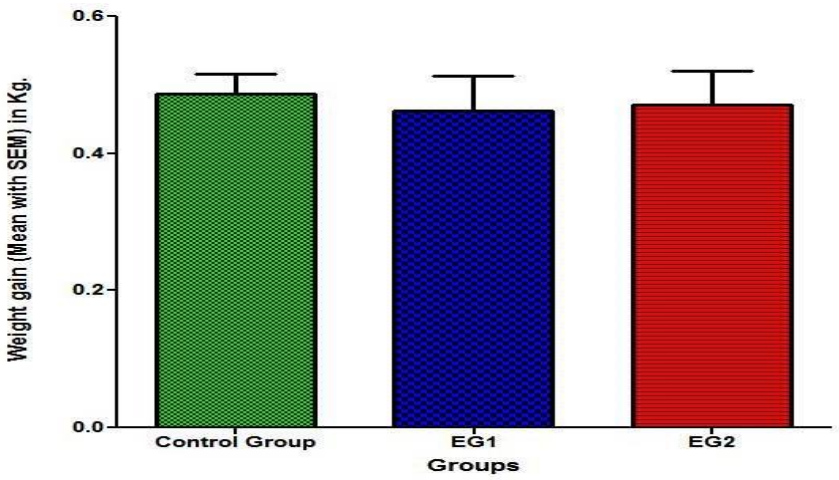

Figure 1: Morphometric analysis of chicken weight gain of the body between control group (CG) and experimental groups (EG1 and EG2). Histogram showing the body weight gain only due to feed consumption and there is no effect of passive smoking exposure on the body weight changes on all chickens

Table 2: Heart weight of control group (CG) and experimental group (EG1 and EG2) expressed in terms of (Mean ± SEM)

The values are given following table.

Groups	Control Group (CG)	Experimental Group 1 (EG1)	Experimental Group 2 (EG2)
Heart weight	5.176±0.282	3.880±0.279a*	4.212±0.208

Mean ± SEM is expressed values a= Control Vs Experimental group b= diet + exposed to smoke of 4 cigarette /day, c= diet + exposed to the smoke of 2 cigarette /day, P < 0.05*, P<0.01**, P<0.001***

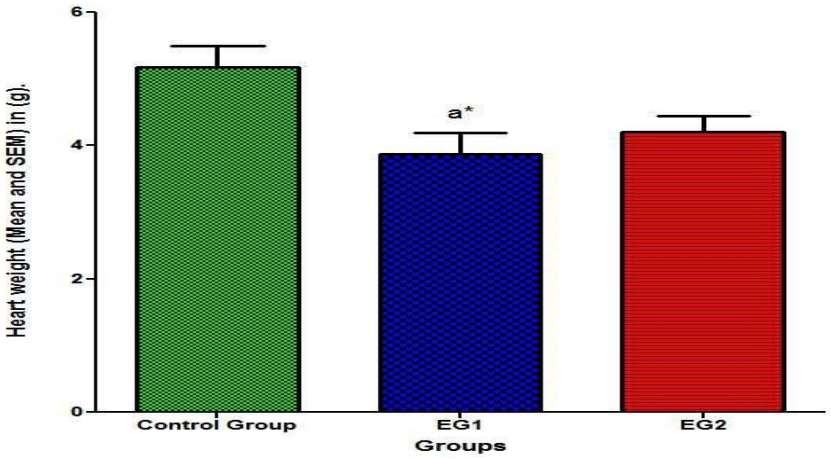

Figure 2: Morphometric comparison of total heart weight between the experimental and control groups. Histogram showing the heart weight of chickens

Xi'an Shiyou Daxue Xuebao (Ziran Kexue Ban)/
Journal of Xi'an Shiyou University, Natural Sciences Edition
ISSN: 1673-064X
E-Publication: Online Open Access
Vol: 68 Issue 01 | 2025
DOI: 10.5281/zenodo.14723216

Table 3: Lipid Profile of the control group (CG) and experimental group (EG1 and EG2) after the passive smoking exposure

Groups	Control Group (CG)	Experimental Group 1 (EG1)	Experimental Group 2 (EG2)
TC	150.8 ± 12.999	261±10.590 a***	172 ± 10.820 b**
LDL	54.8± 5.218	108±9.230 a**	81± 8.489
VLDL	39.2± 4.17	68.2±4.46a**	44.6± 3.18 a**
HDL	66± 6.066	24.72±3.29 a**	50.6±6.25 b*
TG	52.8±5.12	140±12.49a***	108±11.79 b*

Mean ± SEM is expressed values a= Control Vs Experimental group b= diet + exposed to smoke of 4 cigarette /day, c= diet + exposed to the smoke of 2 cigarette /day, P < 0.05*, P<0.01**, P<0.001***

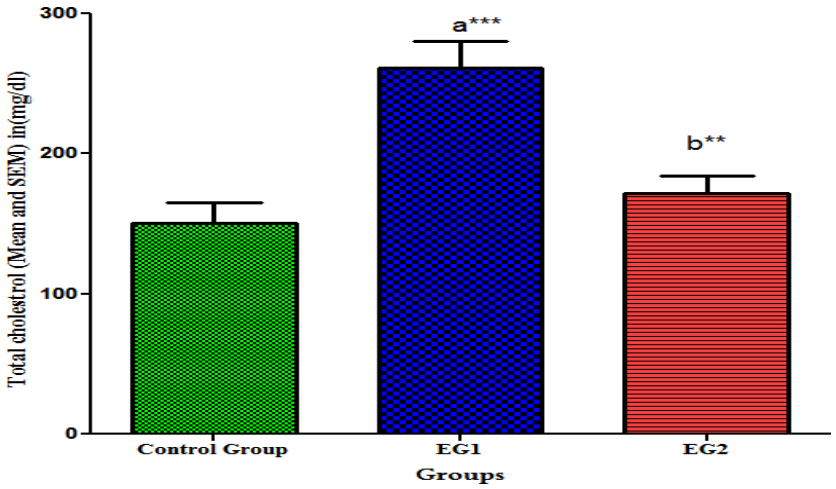

Figure 3: Comparison of total cholesterol for the control and experimental groups using morphometric analysis. Cholesterol level increased in the experimental group due to passive smoking

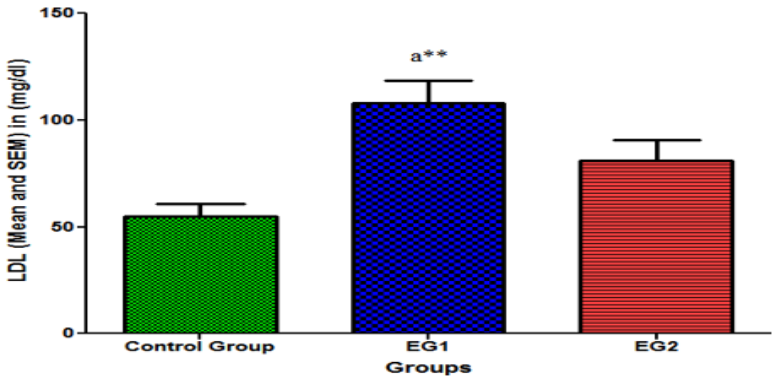

Figure 4: Morphometric analysis of low-density lipoprotein (LDL) between control and experimental groups. Histogram the LDL-C increased in the experimental group due to passive smoking

Xi'an Shiyou Daxue Xuebao (Ziran Kexue Ban)/
Journal of Xi'an Shiyou University, Natural Sciences Edition
ISSN: 1673-064X
E-Publication: Online Open Access
Vol: 68 Issue 01 | 2025
DOI: 10.5281/zenodo.14723216

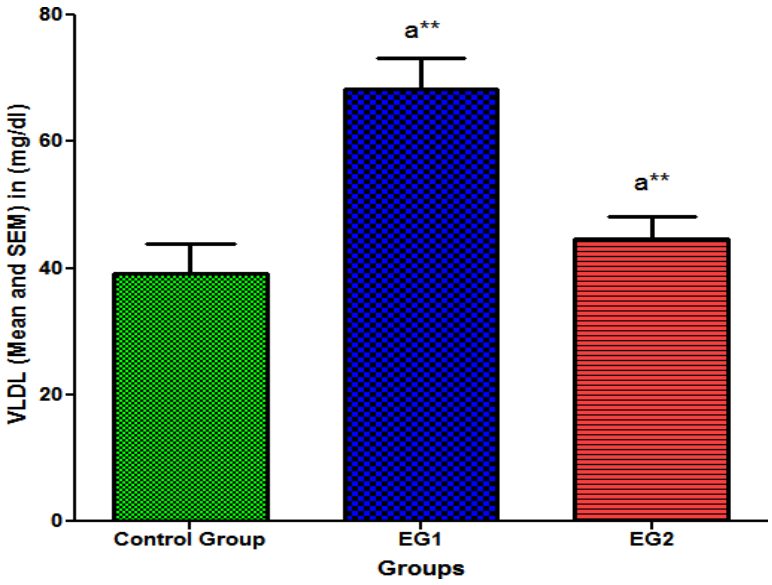

Figure 5: Morphometric analysis of very low-density lipoprotein (VLDL) between control and experimental groups. Histogram showing the concentration of the VLDL-C increased in the experimental group due to passive smoking

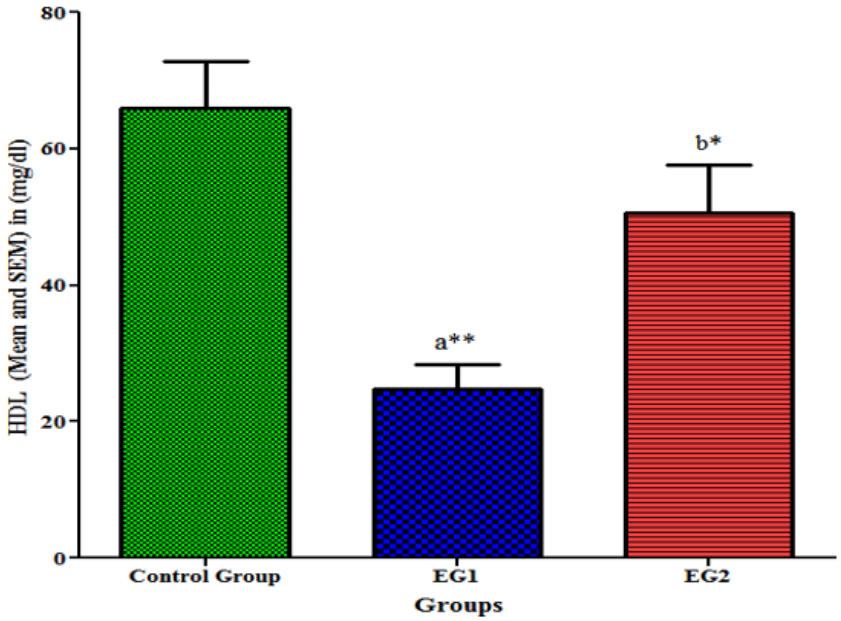

Figure 6: High-density lipoprotein (HDL) morphometric analysis across all the groups. Histogram showing the concentration of the HDL increased in the experimental group due to passive smoking

Xi'an Shiyou Daxue Xuebao (Ziran Kexue Ban)/
Journal of Xi'an Shiyou University, Natural Sciences Edition
ISSN: 1673-064X
E-Publication: Online Open Access
Vol: 68 Issue 01 | 2025
DOI: 10.5281/zenodo.14723216

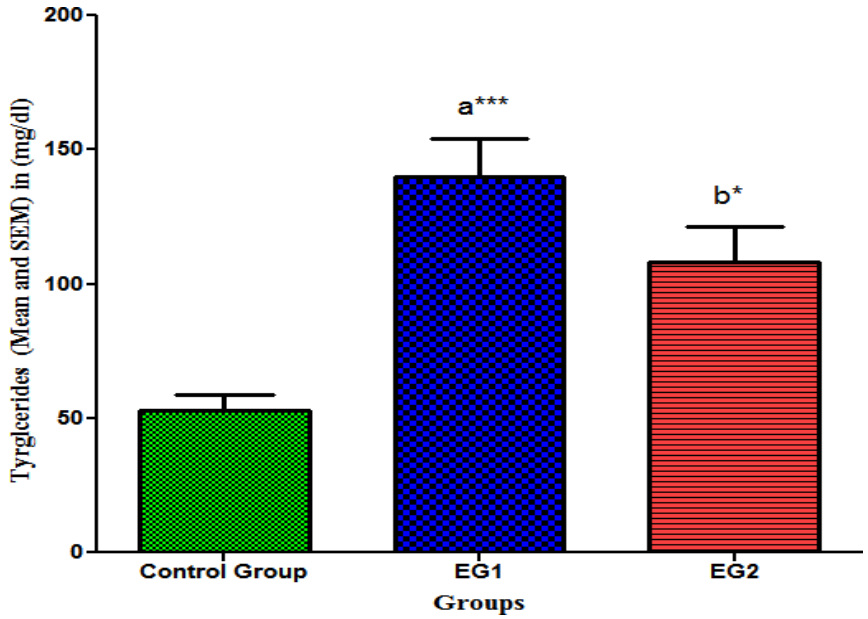

Figure 7: TG value comparison using morphometric analysis across all groups. Histogram shows the concentration of the triglycerides increased in the experimental group due to passive smoking

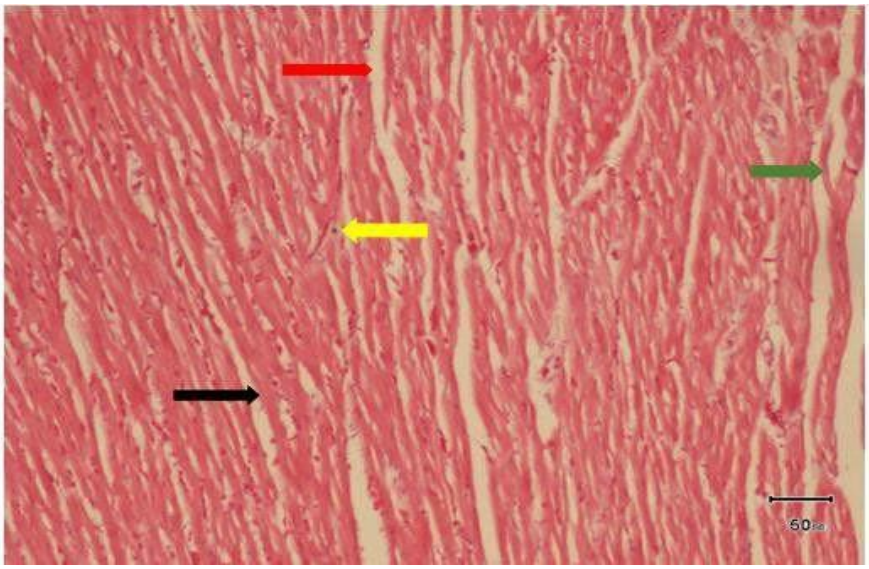

Figure 8: **Histopathological examination of heart tissue of control group (C1) at Magnification10x almost normal and no tissue changes were seen Yellow arrow: Muscle cells have a single central nucleus, Green arrow: cardiomyocyte with branches, Red Arrow: Connective tissues that contain blood vessels among muscle cells, Black arrow: sarcolemma**

Xi'an Shiyou Daxue Xuebao (Ziran Kexue Ban)/
Journal of Xi'an Shiyou University, Natural Sciences Edition
ISSN: 1673-064X
E-Publication: Online Open Access
Vol: 68 Issue 01 | 2025
DOI: 10.5281/zenodo.14723216

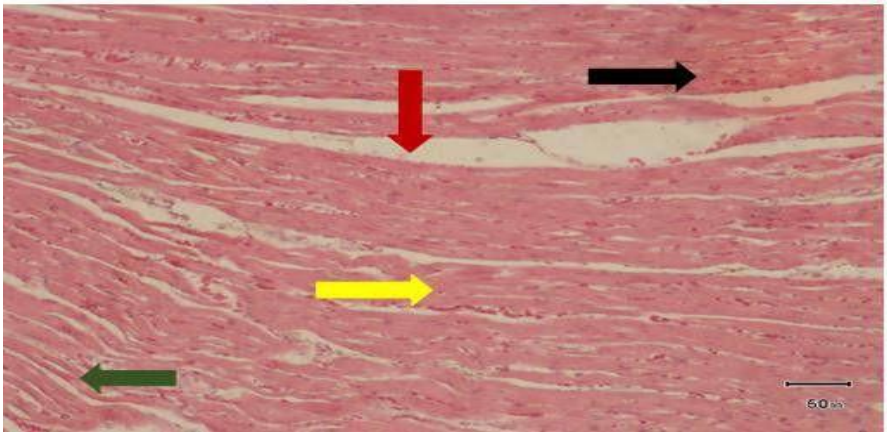

Figure 9: Histopathological examination of heart tissue at Magnification 10x of experimental group 1 (EG1) Marked fragmentation of cardiac muscle fibers and loss of sarcoplasm was seen. Black arrow: myocardial congestion, Green arrow: cardiomyocyte with branches Red Arrow: Connective tissues that contains blood vessels among muscle cells. Yellow arrow: Muscle cells have a single central nucleus

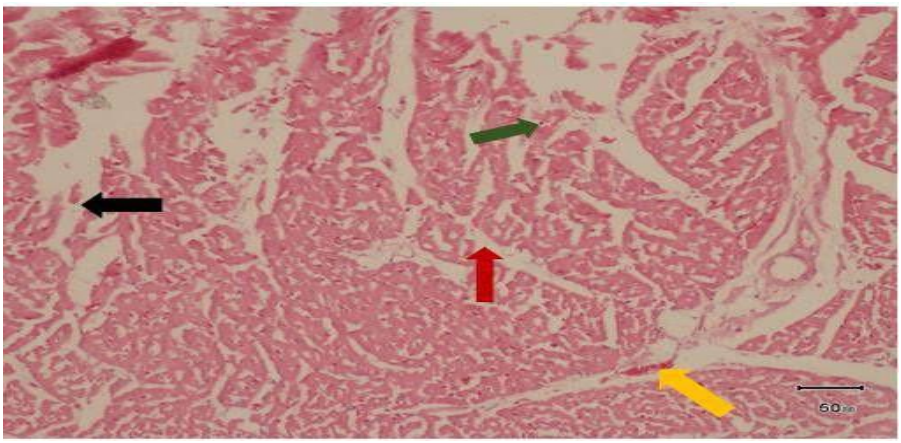

Figure 10: Histopathological examination of heart tissue at Magnification 10x of experimental group 2 (EG2) Marked fragmentation of cardiac muscle fibers and loss of sarcoplasm was seen. Black arrow: fragmentation of cardiac muscle fibers Green arrow: Muscle cells have a single central nucleus, Red Arrow: Connective tissue that contains blood vessels among muscle cells. Yellow arrow: loss of sarcoplasm

4. DISCUSSION

The present study was conducted to check the Effects of tobacco (*nicotiana tabacum)* smoke on lipid profile and heart structure in chickens at the age of 28 weeks. Same size healthy chickens were selected. All animals were kept in separate cages. All chickens

ISSN: 1673-064X
E-Publication: Online Open Access
Vol: 68 Issue 01 | 2025
DOI: 10.5281/zenodo.14723216

had their beginning and final weights recorded before and after the experiment. Passive smoking exposure was different for all groups. Capstan cigarrete was used as source of passive smoking. Passive smoking exposure was not given to the control group. To the experimental groups (EG1 and EG2) passive smoke exposure was provided. EG1 group was exposed to smoke of 4 cigarrete per day; two in morning and 2 in evening was used while the EG2 group was exposed to smoke of 2 cigarrete per day only. Various parameters like heart weight, body weight, lipid profile changes and heart histopathology were measured.

All the groups show the no changes in the body weight. So, it is concluded that body weight increased of the control group (0.487±0.0259) and experimental groups (EG1 0.462± 0.0455 and EG2 0.471±0.044) only due to feed consumption and there is no effect of passive smoking exposure on the body weight changes on all chickens as shown in Table no.1,figure 1. All the groups show the no changes in the heart weight. In the previous studies it was observed that there was no significant changing's in the weight gain of the body due to limited passive smoking exposure [13]. Heart weight increased of the control group 5.176±0.282 and experimental group 1 3.880±0.279 and experimental group 24.212±0.208 only due to feed consumption and there is no effect of passive smoking exposure on the heart weight changes on all chickens as shown in (Table no.2, figure 2).

In lipid profile the TC, LDL-C, vLDL-C, TG and HDL-C values were determined during experimentation. The mean values of the TC, VLDL-C, LDL-C, TG and HDL-C are shown in the (table no.3) respectively. Significant difference is shown by the asterisks. Concentration level the TC, VLDL-C, LDL-C, TG of experimental group 1 (EG1) compared with the control group (CG) and experimental group 2 (EG2). The concentration level of TC, VLDL, LDL and TG for the EG1 increased as compared with the EG2 and CG due to the passive smoking exposure. In the previous study [14] young smokers the Lipids considered as the energy source for the body and that level of bad cholesterol (TC, VLDL, LDL-and Triglycerides) increased while the concentration level of HDL that is known as good cholesterol decreased due to cigarrete smoking.

By increasing the intensity of smoking the lipoprotein concentration that is harmful also increased, that resulted in atherosclerosis due to the reduction in HDL-C level. In previous studies [15] investigated the toxicity effect of Nicotiana tabacum-aqueous extract from tobacco leaves among Wistar male rats on tissue and serum of liver and kidney and also lipid profile. It was concluded that decreases the good cholesterol such as HDL level and while increased the bad cholesterol such as TC, LDL and triglycerides. It had pointedly affected the lipid profile besides the liver or kidney tissue. [16] observed that LDL, TC, HDL and TG significantly higher and HDL level was very low among smokers as serum lipid levels increased the cardiovascular risk among cigarette smoker [17].

Due to higher exposure to EG1 the risks of cardiovascular disease like (Cardiac arrest, heart failure etc.) Significant difference indicated by the asterisk in the table 3 and figure 3. Histological examinations of Control Group Cardiac muscle fibers were normal. No

ISSN: 1673-064X
E-Publication: Online Open Access
Vol: 68 Issue 01 | 2025
DOI: 10.5281/zenodo.14723216

tissue changes were seen, experimental group (EG1) showed the marked fragmentation of cardiac muscle fibers and loss of sarcoplasm was seen. Some cardiac muscle fibers were fragmented and loss of sarcoplasm was seen and also shrinkage and atrophy of cardiac muscle fibers was seen and experimental group (EG2) represents that mild degeneration and necrosis was seen in the cardiomyocytes and in some mild congestion was seen in the myocardium. In previous studies [18] observed the cardiac muscle fibers fragmented and loss of sarcoplasm and transportation of toxic substance effect the heart, liver, kidney, lungs.

5. CONCLUSION

The results of the present study concluded that body weight changes were only due to feed consumption and there is no effect of passive smoking exposure on the body weight gaining and heart weight. The lipid profile due to passive smoking disturbed. The experimental group 1 (EG1) the level of bad cholesterol that is TC, TG, LDL, and VLDL increased significantly and good cholesterol-HDL decreased significantly as compared with the control group and experimental groups.

Histological examinations of Control Group Cardiac muscle fibers were normal. No tissue changes were seen, experimental group (EG1) showed the marked fragmentation of cardiac muscle fibers and loss of sarcoplasm was seen. Some cardiac muscle fibers were fragmented and loss of sarcoplasm was seen and also shrinkage and atrophy of cardiac muscle fibers was seen and experimental group (EG2) represents that mild degeneration and necrosis was seen in the cardiomyocytes and in some mild congestion was seen in the myocardium.

Reference

1) **S.**Hallit, M. Zoghbi, R. Hallit, L.Youssef, R.Costantine, N. Kheir, & S. Pascale (2017). Effect of exclusive cigarette smoking and in combination with waterpipe smoking on lipoproteins. Journal of Epidemiology and Global Health 7(4): 269 -275. https://doi. org/10.1016/j.jegh.2017.08.006

2) T.Nurhidayati, R.Y. Rahman, H.Purnobasuki, S.Hariyanto & N. Jadid (2018). Particular variety of tobacco Nicotianatabacum) exhibits distinct morphological and physiological responses against periodic waterlogging stress. Journal of Physics: Conference Series, 1028, 012035. **https://doi.org/** 10.1088/1742-6596/1028/1/012035.

3) M. Ahmad, E. Selvaraj & R.Meenakshisundaram (2015). The Effects of Active and Passive Smoking and Cardiovascular Disease. Heart and Toxins, 12(1): 437–457.PMID: 977901.

4) R. Attard, P. Dingli, C.J.M.Doggen, K. Cassar, R.Farrugia & S.B.Wettinger (2017). The impact of passive and active smoking on inflammation, lipid profile and the risk of myocardial infarction.Open Heart, 4(2): 620-630. https://doi.org/10.1136/openhrt-2017-000620.

5) Dai. Xiaochen, F. Gil Gabriela, B.Marissa, R. Noah, S. Ahmad, A. Jason Anderson, B. Catherine, C. Sinclair,F. Rachel, I. Simon HaY, H. Jiawei, L. Vincent , R. Hilary, Lawlor, Matthew J. Malloy , Laurie B. Marczak , Susan A. McLaughlin , Larissa Morikawa , Erin C. Mullany , Sneha I. Nicholson , Erin M. O'Connell , Chukwuma Okereke , Reed J. D. Sorensen , Joanna Whisnant , Aleksandr Y. Aravkin, Peng Zheng, Christopher J. L. Murray and E. Gakidou(2022). Health effects associated with smoking: a Burden of Proof study. Nature Medicine VOL (28) issue 10, page 2045–2055.

ISSN: 1673-064X
E-Publication: Online Open Access
Vol: 68 Issue 01 | 2025
DOI: 10.5281/zenodo.14723216

6) J.Szymański, A.Ostrowska, J.Pinkas, W. Giermaziak, E. Krzych Fałta & M. Jankowski (2022). Awareness of Tobacco- Related Diseases among Adults in Poland: A 2022 Nationwide Cross-Sectional Survey. International Jorunal of Environmental Research and Public Health. 19(9): 5702. https://doi.org/ 10.3390/I jer ph 19095702.

7) L.Rui, L. Wang, A.Maehara Akiko, Z. GuoXiaoya , H. Samaday, P.Giddens Don, S.Mintz Gary, W.Stone Gregg & D. Tang(2022)., Image-based biomechanical modeling for coronary atherosclerotic plaque progression and vulnerability prediction.International Journal of Cardiology (352) 1-8.https://doi.org/: 10.1016/j.ijcard.2022.02.005. Epub 2022 Feb 9.

8) B. Pan, X. Jin Xiao, L. Jun, QiuShaohong, Q. Zheng, & Pan. Mingwo (2019). The relationship between smoking and stroke.Medicine, 98(12), e14872.https:// doi.org/ 10.1097/MD.0000000000014872.

9) A.Roth Gregory, A.Mensah George & FusterValentin. (2020). The Global Burden of Cardiovascular Diseases and Risks. Journal of the American College of Cardiology, 76(25): 2980–2981.https:// doi.org/ 10.1016/j.jacc.2020.11.021.

10) B. Messner & D.Bernhard (2014). Smoking and Cardiovascular Disease: Mechanisms of Endothelial Dysfunction and Early Atherogenesis. Arteriosclerosis, Thrombosis, and Vascular Biology, 34(3):509–515.https:// doi.org/ 10.1161/ATVBAHA.113.300156.

11) D. Aune, S. Schlesinger, T.Norat & RiboliElio .(2018). Tobacco smoking and the risk of abdominal aortic aneurysm: a systematic review and meta-analysis of prospective studies. Scientific Reports, 8(1), 14786. https://doi.org/ 10.1038/s41598-018-32100-2.

12) W.Wang, T. Zhao, K. Geng, G. Yuan, Y. Chen & XuYouhua (2021). Smoking and the Pathophysiology of Peripheral Artery Disease. Frontier Cardiovascular Medicine 8(1):1-17. https://doi.org/ 10.3389/fcvm.2021.704106

13) L. Gu, J. Li, G.Pan, X. Zhou, J.Zhang, X.Lai & J. Liu (2017). Effects of Passive Smoking on Glycemic Parameters and Lipid Profiles in a Chinese Female Population. Clinical Laboratory, 63(7): 1147-1152.https:// doi.org/10.7754/Clin.Lab.2017.170102.

14) Q.Noori Raddam & M.M. Zeidan (2020). Effects of Smoking on the Level of Lipase Enzyme and Lipid Profile in Blood Serum of Young Smokers.Medico-legal, 20 (2), 814-818.

15) A.Andong Felix, A.Orji Ebele, E.Ezenwaji, Ngozi, O. Nkemakolam, D. Melefa Temitope , Chukwurah A, O. Antoinette, M. Oguch, F. Hinmikaye Faith & A. Onwurah (2020). Sub-acute oral toxicity study of aqueous extract of tobacco leaves (Nicotianatabacum-L) on lipid profile, the tissue, and serum of the liver and kidney of male Wistar rats. Biomarkers, 5(25): 1–42.https:// doi.org/10.1080/ 1354750X. 2020.1854346. Epub 2021 Jan 12.

16) P. Herath, S. Wimalasekera, T, Amarasekara M.Fernando & T.Sue (2021). Effect of cigarette smoking on smoking biomarkers, blood pressure and blood lipid levels among Sri Lankan male smokers. British Medical Journal, 22(10): 780- 797.https:// doi.org/ 10.1136/postgradmedj-2021-141016. Epub 2021 Oct 19.

17) T. Nurhidayati, R.Y.Rahman, H. Purnobasuk, S.Hariyanto and N. Jadid (2018). Particular variety of tobacco Nicotianatabacum) exhibits distinct morphological and physiological responses against periodic waterlogging stress. Journal of Physics: Conference Series, 1028, 012035.**https://doi.org/** 10.1088/1742-6596/1028/1/012035.

18) A.D. Adedayo, A.A. Tijani, A. A. Musa &T.D. Adeniyi (2011). Histological study of smoke extract of Tobacco nicotiana on the heart, liver, lungs, kidney, and testes of male Sprague-Dawley rats. Niger Med J. 52(4):217-22.https:// doi.org/:10.4103/0300-1652.93791.