MEDWIN PUBLISHERS
Committed to create value for Researchers

Journal of Natural & Ayurvedic Medicine
ISSN: 2578-4986

Anti-Arthritic Activity of Leaf of *Carissa carandas* (L) against Adjuvant- Induced Arthritis in Rat

Dar MA*, Kumar J and Sami R

Department of pharmacology, Oxford College Of Pharmacy, India

***Corresponding author:** Mehraj Ahmad Dar, Oxford College of Pharmacy, Sri padmavathi comforts gents pg near oxford college back gate Bommanahali, Bangalore-560068, India, Tel: 8904184719; Email: darmehran24@gmail.com

Review Article
Volume 3 Issue 2
Received Date: May 20, 2019
Published Date: May 31, 2019
DOI: 10.23880/jonam-16000187

Abstract

Background: *Carissa carandas* (Apocynaceae) also known as Karonda. The plant has been used in Ayurveda, Unani and Homoeopathic system medicine for over thousands of years. The leaves of this plant has shown astringent, antidiabetic, anti-inflammation and anti-pyretic activity and also used in the rheumatism.

Objectives: The present investigation was carried out to evaluate the anti-arthritic activity of ethanolic extract of leaf of *Carissa carandas* against adjuvant - induced arthritis in rat.

Materials and Methods: In this study both male as well as female Wister arts were used in the study. Arthritis was induced by injecting 0.1ml of freund's complete adjuvant intra-dermally into the left hind paw of the rats. The paw volume, hematological, biochemical, radiographic and histopathological study were evaluated.

Results: The extract shows significant reduction in the paw volume which was comparable with the standard and treated as well as normal group. The study reveals that extract as well as standard group shows mild reduction of paw volume where as in negative control sclerosis was seen. The changes in haematological parameters adjuvant induced arthritis shown there was significant increase of RBC count and haemoglobin, while there was significant decrease in WBC count and ESR of arthritic rats in comparison to control. The biochemical parameters such as ALT, ALP, and AST in arthritis induced by CFA group 2 it also showed that the administration of *Carissa carandas* at doses of 200mg and 400mg/kg in group 4, 5 and standard, in which a significant difference in the triglycerides was found.

Conclusion: The effect of anti-arthritic activity of ethanolic extract of leaf of *Carissa carandas* was investigated in the present study may be due to synergistic effect of phytoconstituents, since the plant contains the active principle which are able to target through multiple mechanisms and which is used in pathophysiology of arthritis.

Keywords: Carissa Carandas; Complete Freund's Adjuvant; Biochemical Parameters; Anti-Arthritis; Histopathology

Introduction

Carissa carandas is a species of flowering shrub in the dogbane family, Apocynaceae. It produces berry- sized fruits that are commonly used as a condiment or additive to Indian pickles and spices. It is a hardy, drought-tolerant plant that thrives well in a wide range of soils. Common names include Koromcha in Bangla and Karanda in English. Its botanical name was in recent years changed to Carissa congesta Wight (syn. C. carandas Auct formerly widely shown as *C. carandas* L.) [1]. Phytochemical screening of the root extract showed that the crude extract contained small quantities of alkaloids, flavonoids, Saponins and large amounts of cardiac glycosides, triterpenoids, phenolic compounds and tannins [2]. Earlier studies have shown that the extract of the plant possesses cardiotonic, antipyretic and antiviral activity [3-5]. Various cardiac glycosides, a triterpenoidal constituent carissone and β-sitosterol were reported from the root extract of the plant [6]. In Western Ghats region of India, the decoctions and extracts of the roots of this plant are effective remedies in the management and/or control of convulsions and epilepsy. However studies showed that root extract of *C. carandas* may produce its anticonvulsant effects via non-specific mechanisms.

Rheumatoid arthritis is a chronic inflammatory disease that affects the synovial lining between the joints and can lead to severe pain and loss of joint function. RA is a chronic autoimmune disease characterized by poly-articular inflammation associated with synovitis, otitis, and peri-articular osteopenia, often associated with erosion of subchondral bone and progressive joint space narrowing [7]. It is widely acknowledged the early diagnosis of rheumatoid arthritis (RA) and aggressive treatment to control disease activity offer the highest likelihood of preserving function and preventing disability. These features are commonly leaded to progressive joint damage, impaired function, and disability [8,10].

Since half of the patients of the RA roughly suffer from disability within 10 years of diagnosis, it is critical to effectively treat the disease early to reduce inflammation and prevent damage of bone and joint cartilage [11,12]. Treatment is commonly determined by the extent or severity of disease activity, and it is assessed by counting the number of swollen and tender joints measuring patient-reported outcomes (for example, patient global quality of life assessment), and assaying the acute phase responses, such as the erythrocyte sedimentation rate (ESR) and C-reactive protein (CRP) levels.

Materials and Methods

Collection and Authentication of Plant Material

The plant was collected from Tamil Nadu Vellore district. The plant *Carissa carandas* was authenticated by Dr. R. Sridharan, Directorate of ISM & H, and Govt. of Pondicherry. The Fruiting bodies were shade dried. It was then coarsely powdered and preserved in air tight glass container for further processing.

Extraction of Plant Material

The coarsely powder of *Carissa carandas* were extracted with ethanol in a soxhlet extractor. The extracts were concentrated in rotary flash evaporator and stored in desiccator until further use [13].

Experimental Animals

Albino rats (waster) weighing 200-250grams were selected for Anti-arthritic activity. They were procured from Raghavendra Agency, Bangalore. The animals were acclimatized for one week under laboratory Conditions. They were housed in polypropylene cages and maintained at 27°C ± 2°C under clearance for use of the animals was obtained from the institutional animal "ethical Committee'' prior to the beginning of the project work.

Complete Freund's adjuvant (CFA) induced arthritis in rats

Albino Wister rats of 200-250g were divided into five groups with six animals [14]. Total no of animals =6 (Table 1).

S.No	Group	Treatment
1	Normal control (6 animals)	Received normal saline 5ml/kg, p.o.
2	Negative control (6 animals)	Received CFA o.1 ml/kg in foot pad of left hind paw
3	Standard (6 animals)	Received Diclofenac sodium 10mg/kg, i.p
4	Low dose (12 animals) Male 6 and female 6	Received *Carissa carandas* extract 200mg/kg, p.o.
5	High dose (12 animals) Male 6 and female 6	Received *Carissa carandas* extract 400mg/kg, p.o.

Table 1: Estimation of Albino Wister rats in to Groups.

Copyright© Dar MA, et al.

Induction of Arthritis

All the animals were examined carefully; their hind paw swelling was recorded on day 0, 3, 7, 14 and 21 respectively. On day 21 the Radiographic analysis of hind limbs of arthritic and treated animals were performed by X-ray machine with a 300-mA exposition for 5 sec. blood samples were collected by puncturing the retro-orbital plexus prior to the sacrifice and the collected blood sample was used for the assessment of RBC, WBC, ESR and hemoglobin content. Later on the rats were sacrificed by over dose of inhalant anesthesia. Blood samples were collected for the estimation of biochemical parameters like, SGPT, SGOT, ALP and total protein content and triglycerides. Joint were collected and subjected for histopathological studies.

Statistical Analysis

The experimental result is represented as mean ±SEM. The data were statistical analyzed by one way analysis and variance (ANOVA) fallowed by Dunnet's comparison test. P value< 0.5 was considered as significant.

Result and Discussion

The percentage yield of the ethanolic extract were found to be 24% the ethanolic extract was found to contain alkaloids, glycosides, flavonoids, steroids, terpenoids and carbohydrates, tannins. From the acute toxicity study it was found that the extract were safe up to 4000mg/kg body weight, so one tenth of this dose (i,e 400mg/kg) was considered as high dose where as one twenty of this dose (i,e 200mg/kg) of body weight was considered as low dose. In the present investigation by standard drug Diclofenac sodium at a dose of 10mg/kg of body weight the paw volume was significantly decreased (p<0.1) from 3 day after the induction of CFA, whereas the extract significantly decreases the paw volume after the 3 day of shown in (Table 2 & Figure 1).

Treatment n=6	01 day	03 day	07 day	14 day	21 day
Control	0.001±	0.0002±	0.001±	0.0012±	0.0004±
	0.0067	0.0066	0.0065	0.0057	0.0021
Negative	0.0018 ±	2.448±	2.098±	2.523±	2.434±
	0.0067	0.05	0.0477		
Standard	0.019 ±	1.356±	1.278±	1.065±	0.967±
	0.0076	0.056***	0.0054***	0.0043***	0.0065***
Extract					
Male LD	0.018 ±	1.356±	1.398±	1.2±	0.889±
	0.0057	0.05	0.0057***	0.065**	0.005***
Female LD	0.019 ±	1.356±	1.345±	1.201±	1.123±
	0.0092	0.4300**	0.54	0.543*	0.3240*
Extract					
Male HD	0.02 ±	1.356±	1.98±	1.894±	1.745±
	0.0032	0.0320*	0.0230*	0.033	0.600***
Female HD	0.021±	1.356±	1.935±	1.798±	1.565±
	0.0048	0.6252	0.7983	0.456*	0.3364**

Table 2: Mean Changes in Paw Volume (Ml) in CFA Induced Paw Volume in Rats.
Effect of extract on mean changes of paw volume in table no 5.3. Values are present as mean ±SEM for n=6 *represents significant at (p<0.05), **represents more significant at (p<0.01), ***represents higher significant at (p<0.001) using one way ANOVA method.

Copyright© Dar MA, et al.

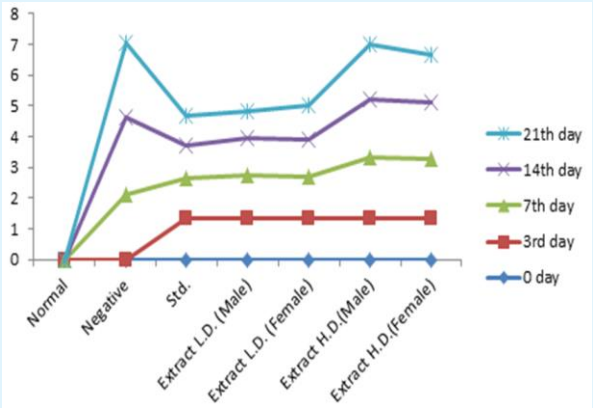

Figure 1: Effect of Ethanolic Extract of *Carissa carandas* on Paw Volume in CFA Induced Arthritis in Rats.
X axis: volume of paw.

In the Table 3 it was found that ethanol extract has got highest percentage inhibition 62.66% in female rat at a dose of 400mg/kg of body weight when compared with the low dose 200mg/kg which is 54.67%.at the end of 21th days. Standard drug Diclofenac decreases the paw volume 53.09% [15]. The radiographic images of the knee joints of all groups of rats are shown in Figure 2. It is evident from the radiographic images that adjuvant treated rats developed joint destruction, sclerosis and osteophytes and soft tissue swelling was seen. Whereas, in the extracts treated animals at a dose (400mg/kg) of body weight and standard Diclofenac at a dose of (10mg/kg) of body weight showed shows mild inflammation and no osteophytes were seen when compared to control group. In the present study, we also examined joint histopathology. The affected knee joint of each animal were removed at the end of experiment and processed by radiographs and H and E staining. The radiographs showed a significant loss of bone, periosteal bone formation and also caused soft tissues swelling. Whereas as groups treated with extract of leaf of *Carissa carandas* at a dose of (400mg/kg) of body weight and treated standard drug Diclofenac sodium at a dose of (10mg/kg) of body weight showed good protection against the CFA induced arthritis in rats. The extract treated group's shoed lowered radiographic scores when compared negative control. The images of H and E staining section of arthritic group showed disruption of normal architecture of synovial membrane with severe infiltration of lymphocytes and invasion of inflamed synovial membrane with the articular bone and loss of articular cartilage [16].

Treatments n=6	Day 1	Day 3	Day 7	Day 14	Day 21
Negative	_	_	_	_	_
Standard	_	35.59	37.44	49.45	53.09
Extract					
Male LD	_	36.56	41.78	46.78	54.67
Female LD	_	33.67	38.98	43.66	48.77
Extract					
Male HD	_	32.45	37.76	43.87	52.8
Female HD	_	36.54	42.12	49.9	62.66

Table 3: Effect of Ethanolic Extract of *Carissa carandas* on Percentage of Inhibition of Paw Volume in CFA. Induced Arthritis in Rats.

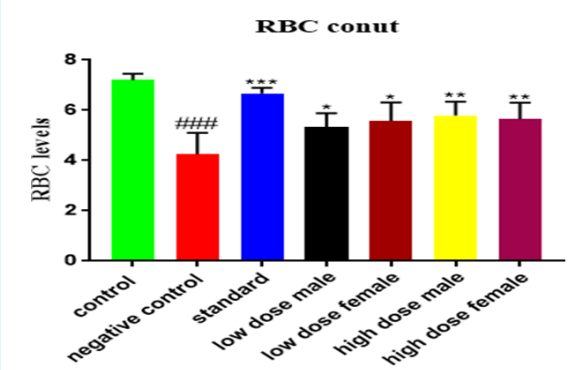

Figure 2: Effect of Ethanolic Extract of *Carissa carandas* on RBC Levels in CFA induced Arthritis in Rats.

Copyright© Dar MA, et al.

The haematological data revealed that there was an increase in RBC count and haemoglobin level, and decrease in the ESR. Further, there was a significant decrease in leukocyte count in extract treated groups while it was reverse in control group shown in Table 4 These data suggest that *Carissa carandas* ethanolic leaf extract has significant role in the arthritis [17] (Figures 3-6).

Treatment groups n=6	RBC (106 cells/mm3)	WBC (103 cells/mm3	Hemoglobin %	ESR (mm/h)
Normal 5ml gum acacia	7.201±0.1033	10.40±0.226	9.71±0.219	5.833±0.3073
Negative control 0.1ml CFA	4.250 ±0.348	15.20±0.073	6.183±0.487	15.48±0.1424
Standard 10mg/kg i.p	6.667± 0.0918	11.45±0.477	7.283±0.238	8.417±0.6284
Extract				
Male(200mg/kg)	5.333 ± 0.224	12.51±0.826	7.200±0.228	10.2±0.39
Female(200mg/kg)	5.583±0.2246	11.50±2.249	7.910±0.156	10.4±0.59
Extract				
Male(400mg/kg) p.o.	5.000 ± 0.226	10.95±1.47	8.052±0.167	8.77±0.52
Female(400mg/kg)p.o.	5.500 ± 0.268	11.20±1.43	8.50±0.2094	8.69±0.69

Table 4: Effect of Ethanolic Extract of *Carissa carandas* on RBC, WBC, ESR and Hemoglobin Content in CFA Induced Arthritis in Rats.
Values are mean SEM ± (n=6) by one way ANOVA method. * Significant at (<0.05), ** represents more significant at (<0.01) and ***represents higher significant at (<0.001) when compared with control group.

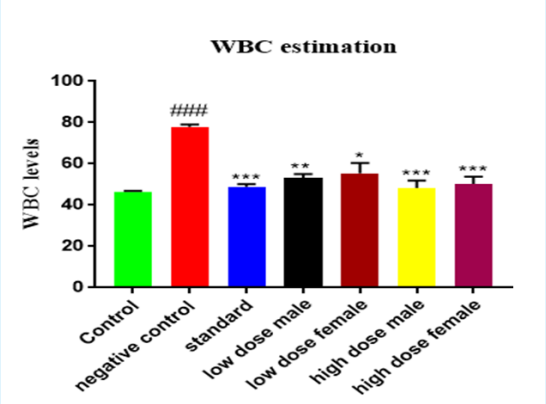

Figure 3: Effect Of Ethanolic Extract of *Carissa carandas* on WBC Levels in CFA induced Arthritis Induced in Rats.

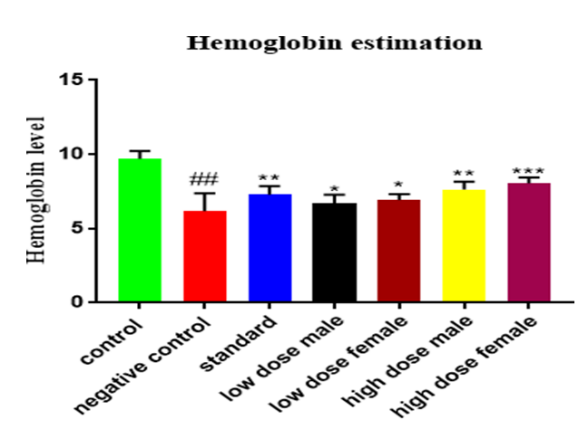

Figure 4: Effect of Extract of Ethanolic Extract of *Carissa carandas* on Haemoglobin Levels in CFA induced Arthritis in Rats.

Copyright© Dar MA, et al.

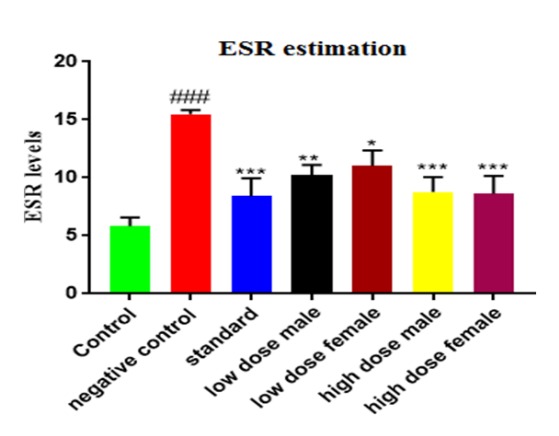

Figure 5: Effect of Ethanolic Extract of *Carissa carandas* on ESR Levels in CFA induced Arthritis in Rats.

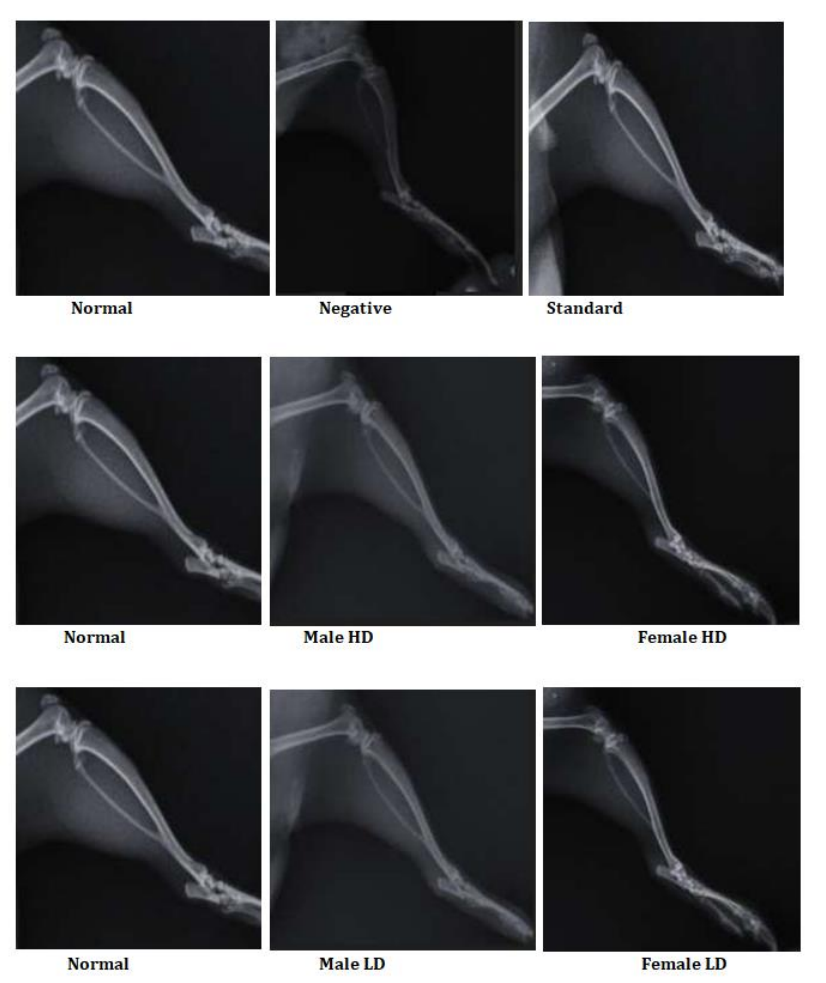

Figure 6: Effect of Ethanolic Extract of *Carissa carandas* on Hind Paw in CFA induced Arthritis in Rats.

Copyright© Dar MA, et al.

Histopathological Studies of Joint in CFA Induced Arthritis in Rats

The histopathological evaluation of CFA induced joint damage in all the groups was examined and shown in figures below (Figure 7). The description is as follows,

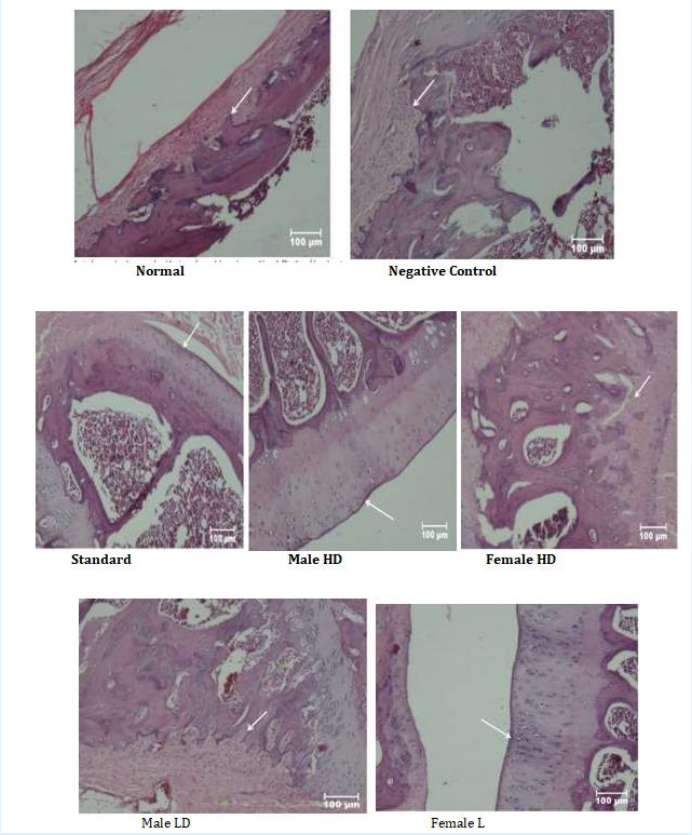

Figure 7: The histopathological Evaluation of CFA induced joint damage in the entire Group.

References

1. Morton J (1987) Fruits of Warm Climates. Miami, FL: Julia F. Morton, pp: 5-11.

2. Hegde K, Thakker SP, Joshi AB, Shastry CS, Chandrashekhar KS (2009) Anticonvulsant activity of *Carissa carandas* Linn. root extract in experimental mice. Tropical Journal of Pharmaceutical Research 8(2): 117-125.

3. Dhawan BN, Patnaik GK (1985) Investigations on some new cardio-active glycosides. Indian Drugs 22(6): 285-290.

4. Rajasekaran A, Jeyasudha V, Kalpana B, Jayakar B (1999) Preliminary phytochemical and antipyretic evaluation of *Carissa carandas*. Indian J Nat Prod 15(1): 27-29.

5. Taylor RSL, Hudson JB, Manandhar NP, Tower GHN (1996) Antiviral activities of medicinal plant of Southern Nepal. J Ethnopharmacol 53(2): 97-104.

6. Rastogi RC, Vohra MM, Rastogi RP, Dhar ML (1966) Studies on *Carissa carandas* Linn. Part I. Isolation of the cardiac active principles. Indian J Chem 4: 132.

7. Avouac J, Allanore Y (2008) Cardiovascular risk in rheumatoid arthritis: effects of anti-TNFdrugs. Expert Opin Pharmacother 9(7): 1121-1128.

8. Diarra D, Stolina M, Polzer K, Zwerina J, Ominsky MS, et al. (2007) Dickkopf-1 is a master regulator of joint remodeling. Nat Med 13(2): 156-163.

Copyright© Dar MA, et al.

9. Schett G, Hayer S, Zwerina J, Redlich K, Smolen JS (2005) Mechanisms of disease: the link between RANKL and arthritic bone disease. Nat Clin Pract Rheumatol 1(1): 47-54.

10. Schett G, Stolina M, Bolon B, Middleton S, Adlam M, et al. (2005) Analysis of the kinetics of osteoclastogenesis in arthritic rats. Arthritis Rheum 52(10): 3192-3201.

11. Emery P, Breedveld FC, Dougados M, Kalden JR, Schiff MH, et al. (2002) Early referral recommendation for newly diagnosed rheumatoid arthritis: evidence-based development of a clinical guide. Ann Rheum Dis 61(4): 290-297.

12. Furst DE, Keystone EC, Fleischmann R, Mease P, Breedveld FC, et al. (2011) Updated consensus statement on biological agents for the treatment of rheumatic diseases 2009. Annals of the Rheumatic Diseases 70: 1519-1519.

13. Maitreyi K, Mamta S, Devdas S, Sunitha J (2006) Antiulcer activity of the root bark of Oroxylum indicum against experimental gastric ulcers. Pharm Biol 44(5): 363-370.

14. Ramadan G, Al-Kahtani MA, El-Sayed WM (2011) Anti-inflammatory and anti-oxidant properties of Curcuma longa (turmeric) versus Zingiber officinale (ginger) rhizomes in rat adjuvant-induced arthritis. Inflammation 34(4): 291-301.

15. Eric GB, Lawrence JL (1996) The textbook of therapeutics drug and disease management. Baltimore: Williams and Wilkins Company; Rheumatoid Arthritis and its therapy, pp: 579-595.

16. Kelly V, Genovese M. (2013) Novel small molecule therapeutics in rheumatoid arthritis. Rheumatology 52(7): 1155-1162.

17. Shinde UA, Phadake AS, Nair AM, Mungantiwar AA, Dishit VJ, et al. (1999) Studies on the anti-inflammatory and analgesic activity of Cedru deodara (Roxb) Loud. Wood oil. J Ethnopharmacol 65(1): 21-28.

Copyright© Dar MA, et al.