CVJ CLUJ VETERINARY JOURNAL

Article

Antiviral Activity of *Lagenaria breviflora* Roberts Fruit Against *Canine Parvovirus* in Embryonated Chicken Egg

Blessing Ayeni [1], Tolulope Olakojo* [1] , Oluwasanmi Aina[2], Olawale Ola[3], Olusegun Fagbohun[4], and Olayinka Oridupa[1]

[1] Department of Veterinary Pharmacology and Toxicology, University of Ibadan
[2] Department of Veterinary Anatomy, University of Ibadan
[3] Department of Veterinary Pathology, University of Ibadan
[4] Department of Veterinary Microbiology, University of Ibadan
* Correspondence: mailintolulope@gmail.com; Tel.: (+234 8078495289)

Abstract: *Lagenaria breviflora* has been traditionally utilized as a natural remedy for various diseases including measles, smallpox, human chickenpox and Newcastle disease in poultry, as well as parasitic infections caused by *Eimeria*s pp and *Ascaridia galli.* This study investigated the antiviral potential of *L. breviflora* fruit methanol extract against Canine Parvovirus using experimentally infected 10-day old embryonated chicken eggs. The eggs were apportioned to 11 groups (n=5) with Group 1 serving as control, while Group 2 remained inoculated with the virus only. Group 3 and 4 received only *L. breviflora* extract (25mg/ml and 50mg/ml), while Groups 5-11 were inoculated with the virus and graded concentrations of *L. breviflora* extract (1.5625mg/ml to 100mg/ml) respectively. Gross and histological changes were assessed 24h post-inoculation. The results revealed significant pathologies such as congealed mass of embryo tissue with disruption of membrane and neuronal layer arrangement, haemorrhage, distorted membranes and necrosis in the untreated infected embryos consistent with Canine Parvoviral infection. Embryos treated with the extract, particularly at concentrations of 3.125-12.5mg/ml, exhibited significantly reduced pathognomonic signs of Canine Parvo Enteritis, presented as slight haemorrhage and blood vessel congestion. Eggs inoculated with higher concentrations (25-100mg/ml) showed signs of toxicity reflected as severe congestion, degeneration and necrosis. This study therefore concluded that the methanol extract of *L. breviflora* fruit at low concentrations demonstrated antiviral activity against Canine Parvovirus, inhibiting virus growth and degenerative pathologies in embryonated chicken eggs. Concentrations >12.5mg/ml was embryotoxic.

Keywords: Canine Parvovirus, Embryonated Chicken Eggs, Inoculation, *Lagenaria breviflora*.

Received: 13.12.2024
Accepted: 14.04.2025
Published: 15.07.2025

DOI:10.52331/v30i2728

Copyright: © 2025 by the authors. Submitted for possible open access publication under the terms and conditions of the Creative Commons Attribution (CC BY) license (http://creativecommons.org/licenses/by/4.0/).

1. Introduction

Canine Parvovirus (CPV) remains a significant enteric virus infecting domesticated and feral breeds of dogs globally. It is a fatal virus that spreads rapidly, causing severe morbidity and high mortality in Canines [1]. Early presentation and treatment are significant determinants of the survival rates, which may be up to 95% if treated early and as low as about 9% when presented late or not treated [2]. Usually, unvaccinated dogs, especially puppies and those with low maternal immunity or poor management conditions, are more susceptible to the infection [3]. Most dog owners are well-informed about the vaccination protocols against this virus, and affordability has not been challenging.

The virus species is classified within *Parvoviridae*, subfamily *Parvovirinae*, and genus *Protoparvovirus,* a virus family known for its high pathogenicity [4,5]. Despite the knowledge of the circulation of canine parvovirus subtypes in Nigeria and routine vaccination of dogs, some vaccinated dogs still come down with Canine Parvoviral Enteritis (CPE). The polyvalent vaccine DHLPP (Distemper Hepatitis Leptospirosis

Parvovirus Parainfluenza) for dog vaccination against CPV in Nigeria is mainly adopted. The CPV subtype in most vaccines is either the wild-type CPV or CPV-2b [6].

These may cause the outbreak of the disease in vaccinated dogs since vaccination of puppies with heterologous subtypes of the virus has been shown to yield a lower antibody titer than the homologous virus [7]. As such, some commercial CPV vaccines that contain only one or two subtypes or wild-type CPV do not confer significant immunity against CPV. Moreover, CPV-2a, the most prevalent serotype of CPV in Nigeria, has been reported as preponderant, despite the surge in the CPV-2c serotypes recorded lately [2].

Vaccine break or low immunity leads to full-blown CPE, which clinically presents with hemorrhagic diarrhoea and vomiting. Severe intestinal crypt cell damage, erosion of enteric blood vessels and massive haemorrhage in the gastrointestinal tract are sequels of the viral invasion of cells [2]. Host cells undergo cell cycle arrest, apoptosis and necrosis of intestinal crypt cells [8]. Supportive care is the primary therapeutic protocol adopted, focusing on mitigating diarrhoea and vomiting. Lost electrolytes are restored via fluid therapy, and antibiotics are administered to treat opportunistic secondary bacterial infections. Other supportive care is given based on clinical signs observed [9]. However, the economic implication of therapy is usually very high with extensive days of treatment [10,11].

From the foregoing, developing alternative therapies from affordable and available sources within the environment is pertinent. Due to viral resistance, viral latency, and contradictory efficacy in recurrent infection of susceptible populations, developing antiviral medicines, mainly, has been challenging [12]. The outbreaks of viral diseases have been on a rampage within animal populations globally, with incidences of emerging and re-emerging virulent virus strains [13]. Therefore, it is vital to prioritize discovering new antiviral agents, especially those that can ameliorate the cytopathic effects of the virus.

Medicinal plants are potential sources for discovering remedies for various disease pathogens, including viruses. One such plant is *Lagenaria breviflora* Roberts (Family Cucurbitaceae), a plant reported to have demonstrated antiviral activities against Newcastle disease and measles viruses [14,15]. It is a perennial climber that grows in the wild in tropical Africa, mounting up the forest canopy and occupying the regions from Senegal to West Cameroons. The fruits have been reportedly used in folkloric medicine for prophylaxis and viral infection therapy, including measles, smallpox, human chickenpox, and Newcastle disease in poultry [5,16]. Previous reports have also documented its anti-ulcerogenic [17], haematinic and immunostimulatory [18], antidiarrhoiec and intestinal smooth muscle relaxant effects [19].

Therefore, in the quest to discover alternative therapies for CPE, this study investigated the antiviral potential of *L. breviflora* Roberts' whole fruit against CPV in embryonated chicken eggs.

2. Materials and Methods

2.1. Preparation of viral inoculum

The viral inoculum was prepared from a diarrheic faecal sample collected from a dog diagnosed with canine parvovirus (CPV) infection at the Veterinary Teaching Hospital, University of Ibadan. The sample was stored at −80°C until processing immediately. Viral presence was confirmed using an immunochromatographic test kit (BioNote, Inc., Gyeonggi, Republic of Korea; Catalog No. VCHECK® CPV Ag), following the manufacturer's instructions. A sterile viral transfer medium (VTM) was prepared by combining 500 mL glycerol (Sigma-Aldrich, St. Louis, MO, USA; Catalog No. G5516), 600 mg penicillin (Sigma-Aldrich; Catalog No. P3032), 5 g streptomycin (Sigma-Aldrich; Catalog No. S9137), 280 mg gentamycin (Sigma-Aldrich; Catalog No. G1272), and 100 mg amphotericin B (Sigma-Aldrich; Catalog No. A2942) in a 500 mL sterile bottle. The pH was adjusted to 7.2 using 1M NaOH (Sigma-Aldrich; Catalog No. S8045) and verified with a calibrated pH meter (Hanna Instruments, HI2211).

For sample processing, 1 g of faecal sample was suspended in 500 μL of VTM and vortexed (Scientific Industries Vortex Genie 2) for 2 min at maximum speed. The suspension was centrifuged at 6,000 × g for 15 min at 4°C (Eppendorf Centrifuge 5810R, rotor F-45-30-11). The supernatant was filtered through a 0.22 μm pore-size syringe filter (Millex®-GP, Millipore, Bedford, MA, USA; Catalog No. SLGP033RB)

under laminar flow to remove bacterial contaminants. The labelled CPV inoculum filtrate was aliquoted into 1.5 mL sterile microcentrifuge tubes (Eppendorf) and stored at −20°C until use.

2.2. Quantification of viral inoculum using spectrometry

Concentration of viral particle was estimated as described by Maizel *et al.* (1968) with a slight modification [20], and optical density of 1.00 AU (1cm pathlength) at 260nm, matching 1.1 x 10^{12} viral particles/mL was considered appropriate. Absorbance unit at 260nm and 320nm were determined from the spectrometric measurement using a NanoDrop™ 2000 spectrophotometer (Thermo Fisher Scientific). Corrected values of A260 absorbance were computed by subtracting the obtained values (A260 – A320) and then, the virus concentration for each of the inoculation hours was calculated using the expression:

Virus concentration [vir/mL] = corrected A260 × 1.1×10^{12}

-A260 represent the optical density at 260nm.

-A320 represent the optical density (background and scatter correction) and

-1.1×10^{12} is the number of virus particles per mL per 1 AU at 260nm.

2.3. Preparation of Lagenaria breviflora Extract

Fresh fruits of *L. breviflora* (40–50 balls) were harvested from the Teaching and Research Farm, University of Ibadan, Nigeria. A taxonomist confirmed Botanical identification, and a voucher specimen (Voucher No. LB-2023-001) was deposited at the Herbarium, Department of Botany, University of Ibadan. The fruits were washed with distilled water, sliced into small cubes measuring approximately 1 cm × 1 cm × 1 cm (1 cm^3), and air-dried at 25°C for 48 h.

About extraction, 500 g of dried material was soaked in 2 L of 96% methanol (Sigma-Aldrich; Catalog No. 322415) in a glass amber bottle for 72 h at 25°C with occasional shaking. The mixture was filtered through Whatman No. 1 filter paper (GE Healthcare), and the filtrate was concentrated under reduced pressure at 40°C using a rotary evaporator (BUCHI R-300, Switzerland; water bath set at 40°C, vacuum pressure: 175 mbar). Residual methanol was removed by placing the extract in an oven (Memmert UN110) at 40°C for 24 h. The extract was neutralized to pH 7.0 by adding 0.2 mL of 1M NaOH per 10 mL of extract, then sterilized by filtration through a 0.45 µm microbial filter (Millipore) and stored in sterile amber bottles at 4°C.

The extract was reconstituted with an antibiotic solution containing Penicillin, Streptomycin, Gentamycin, and Amphotericin B (PSGA), and solutions were refrigerated for 1h at 4°C. Stock solution of 1000 mg/ml of the fruit extracts was diluted in PSGA to a working concentration of 250 mg/ml and further diluted to 200 mg/ml in PSGA. Further, 1:2 dilutions were made to achieve final extract concentrations of 100, 50, 25, 12.5, 6.25, 3.125, and 1.5625mg/ml. The extract was reconstituted with the virus inoculum (1:1) and cooled at 40C for 4 hours before introduction into embryonated eggs [19].

2.4. Experimental Design

Fertilized specific-pathogen-free (SPF) eggs were purchased from a commercial breeder (Amo Farm Sieberer, Ibadan, Oyo State). The eggs were disinfected with 70% ethanol, arranged in an egg crate, and subjected to incubation within a humidified incubator (G.Q.F Manufacturing Incubator) at 370C with the air sac facing upwards with 60% relative humidity.

On the eighth day of incubation, the eggs were candled to assess fertility. An egg was deemed fertile if a thin blood vessel leading to a bean-shaped embryo with visible eyes was observed while infertile eggs were sorted out and discarded.

On day 10, the eggs were randomly allocated into 11 groups (n = 5 eggs/group). Group 1 served as the uninoculated control (0.2 mL sterile PBS), while Group 2 received CPV inoculum only (0.2 mL). Groups 3 and 4 were inoculated with *L. breviflora* extract at 25 or 50 mg/mL, respectively. Groups 5, 6, 7, 8, 9, 10 and 11 were embryonated eggs inoculated with the virus-extract suspension containing graded concentrations of the extract, respectively: 100, 50, 25, 12.5, 6.25, 3.125, and 1.5625mg/ml to establish the antiviral effect of this plant extract. The eggs were drilled at the air sac, ending using a sterile 23-G needle for inoculation. Each egg received a volume of 0.2 ml of virus-extracted inoculum via the drilled hole into the chorioallantoic cavity. This was, afterwards, sealed with sterile paraffin wax.

The eggs were incubated for 24 h at 37°C and then chilled at 4°C to constrict chorioallantoic membrane (CAM) blood vessels. Post-chilling, the eggshells were cracked open, and the embryo with CAM was harvested aseptically. The gross pathologies were photographed and eventually fixed in 10% formalin for histopathology for 48 h [21].

Histopathology

The (CAM) tissue and embryo were fixed in formalin for 48 h, dissected and placed in labelled cassettes. These tissues underwent dehydration in increasing ethanol concentrations (70%, 90%, 100%), followed by xylene clearing to remove alcohol. They were then infiltrated with molten paraffin wax at 56°C, moulded, and solidified for microtome sectioning (Leica RM2235) at 5 μm thickness. Thin wax sections were stained with hematoxylin and eosin (H & E).

The staining process involved dewaxing in xylene, rehydration in decreasing alcohol concentrations, washing, staining, dehydration, and mounting in DPX. Finally, the slides were air-dried and examined microscopically with a microscope (Olympus BX53) at 100x and 400x magnification [22].

3. Results

3.1. Morphology and Gross Pathology

No visible lesions were observed in the uninoculated untreated embryos, the yolk sac, and albumin, while the inoculated untreated embryos presented as a congealed hemorrhagic mass. Embryos inoculated with CPV, treated with 1.562mg/ml and 3.125mg/ml of L. breviflora (LB) extract, showed whitish and cloudy albumin, respectively. A slight haemorrhage and congestion were equally observed at both concentrations. The group inoculated and treated with 6.25mg/ml of LB extract presented with slight congestion in some membranous vessels on the embryo, while inoculated embryos treated with 12.5mg/ml of LB extract showed a rounded embryo with severely congested membranous vessels and slightly cloudy albumin. Inoculated embryos treated with 25mg/ml and 50mg/ml showed haemorrhage and an edematous appearance within the embryo and membrane, mixed with a gelatinous yolk sac and albumin. There was severe congestion around the yolk sac and mild ecchymosis on the surface of embryos treated with 25mg/ml. The albumin of embryos treated with 50mg/ml of LB extract was clear with mild haemorrhage. Inoculated embryos treated with 100mg/ml of LB extract lost embryonic comma shape; the yolk sac and albumin had merged, with a yellow tinge of the yolk sac (Figure 3.1).

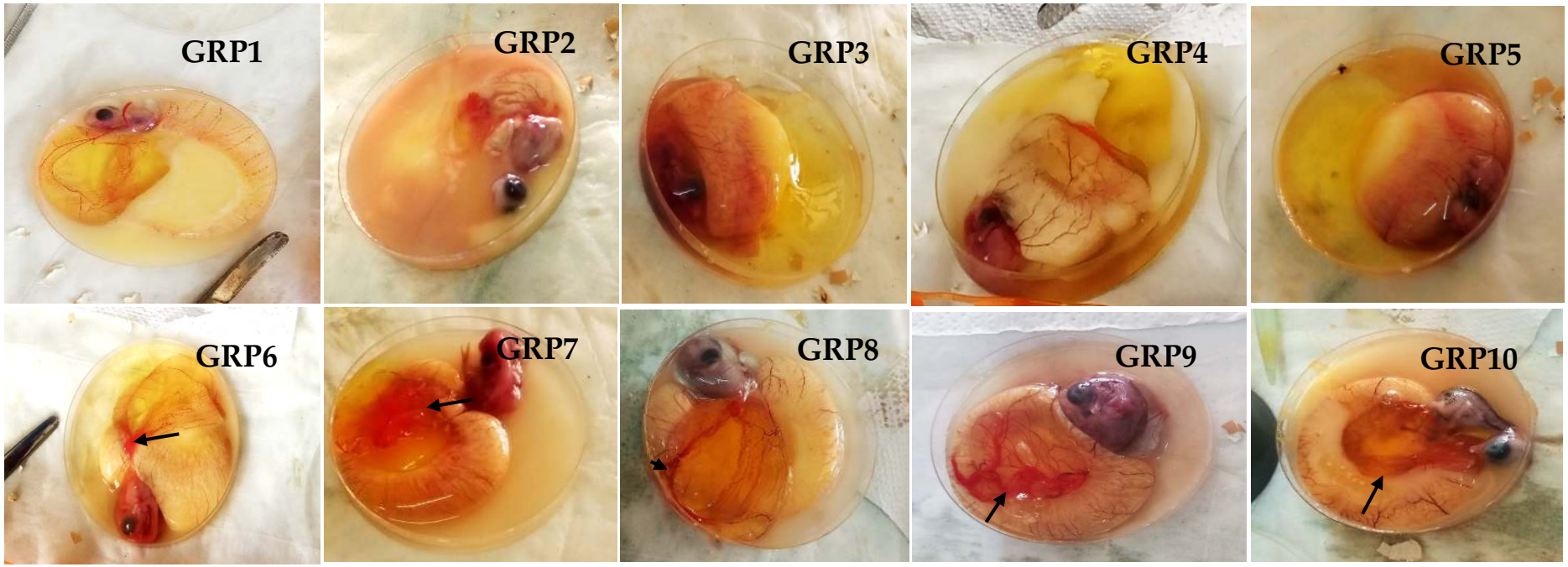

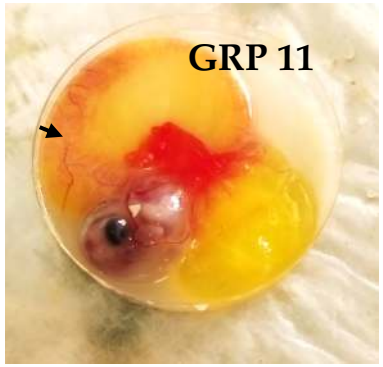

GRP1 (Uninoculated untreated):-Normal embryo, yolk sac and albumin. No visible lesion

GRP 2 (Inoculated untreated):-Congealed mass showing hemorrhage (black arrow) in the embryo

GRP3 (LB extract (25mg/ml): -Hemorrhage and oedematous appearance within the embryo and membrane in a gelatinous mix of yolk sac and albumin

GRP4 (LB extract (50mg/ml):-Embryo and membrane in a gelatinous mix of yolk sac and albumin

GRP 5 (Inoculated –LB extract (100mg/ml):- Embryo has lost its comma shape, yolk sac and albumin has merged yolk sac has a tinge of yellow

GRP 6 (Inoculated – LB extract (50mg/ml):-Albumin is clear, mild hemorrhage (Black Arrow)

GRP 7 (Inoculated – LB extract (25mg/ml)-Severe congestion around yolk sac (Black Arrow), Mild ecchymosis on the surface

GRP 8 (Inoculated – LB extract (12.5mg/ml): -Severe congestion around yolk sac, Mild ecchymosis on the surface (Arrow Head)

GRP 9 (Inoculated – LB extract (6.25mg/ml):-Slight congestion on some membranous vessels

GRP 10 (Inoculated – LB extract (3.125mg/ml): -Albumin is cloudy, slight congestion

GRP 11 (Inoculated – LB extract (1.5625mg/ml)-slight hemorrhage (Arrow head), Albumin is whitish

Figure 3.1: Gross pathology of chicken embryonated eggs inoculated with CPV and treated with L. breviflora whole fruit extract (X100)

3.2. Histopathology of Embryo Head

The membrane of the uninoculated-untreated embryo head was intact with normal integrity of parenchymatous cells. In contrast, the inoculated-untreated group showed a distorted membrane and disruption of neuronal layer arrangement. Embryos were inoculated but treated with 1.5625mg/ml of LB extract, which showed neuronal layer disruption and areas of spongiosis. Compared, extended cavernous spaces containing bloody spots were observed for inoculated-treated embryos at 3.125mg/ml. Inoculated-treated embryos with 6.25mg/ml of LB extract showed areas of mild blood accumulation. However, a relatively normal and parenchymatous cell membrane integrity was observed at 12.5mg/ml LB extract of inoculated-treated embryos. Inoculated embryos treated with 25mg/ml of LB extract presented as membrane-bound accumulation of blood and areas of spongiosis.

In contrast, the inoculated-treated group at 50mg/ml of LB extract maintained normal parenchymatous cell integrity. In addition, embryos treated with LB extract at 25mg/ml had focal points of severe necrosis in the parenchyma, while the group treated with 50mg/ml showed neuronal layer arrangement disruption. Finally, embryos inoculated and treated with 100mg/ml of LB extract revealed disruption of neuronal layer arrangement and a mild area of spongiosis (Figure 3.2).

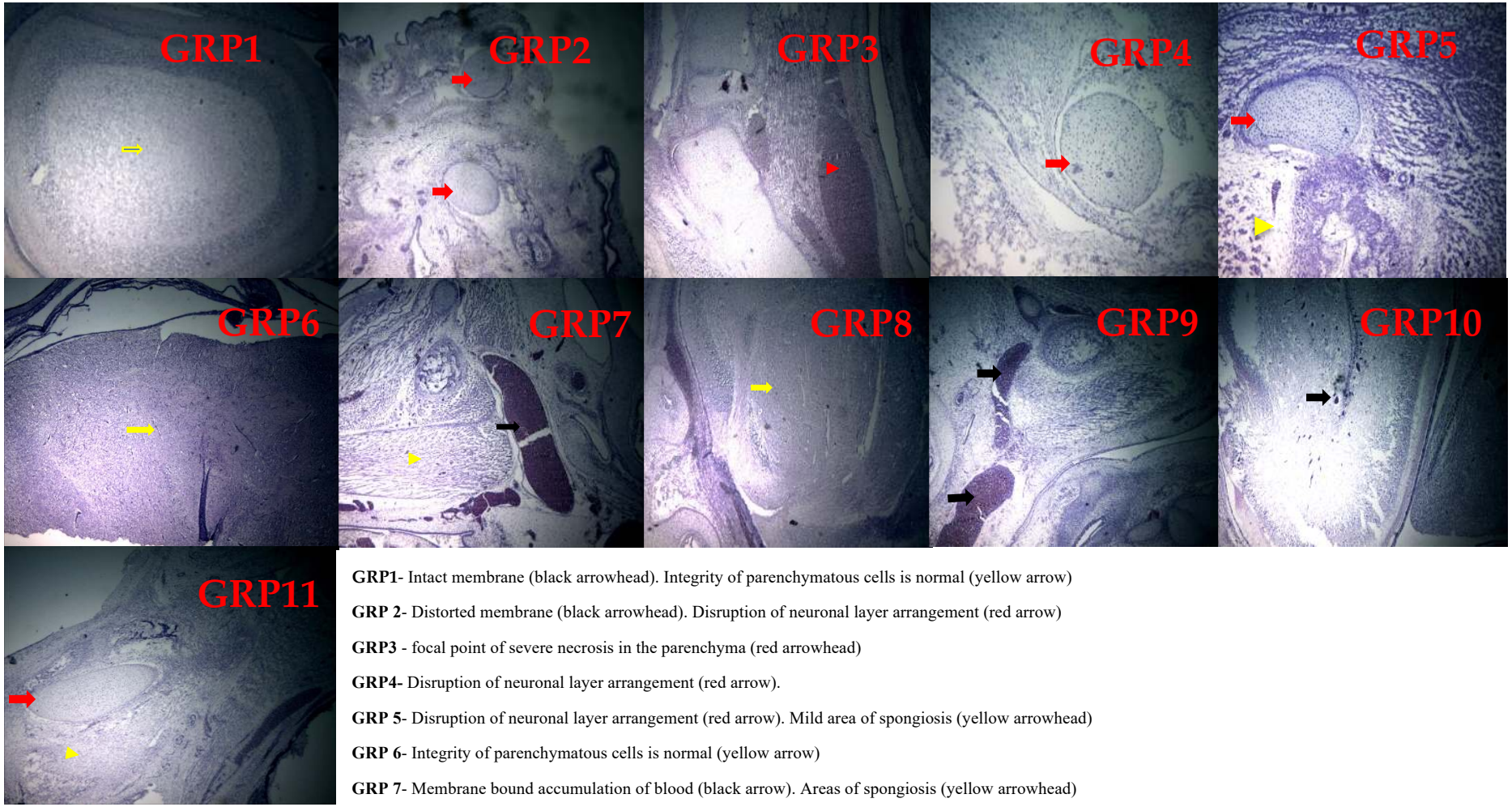

GRP1- Intact membrane (black arrowhead). Integrity of parenchymatous cells is normal (yellow arrow)

GRP 2- Distorted membrane (black arrowhead). Disruption of neuronal layer arrangement (red arrow)

GRP3 - focal point of severe necrosis in the parenchyma (red arrowhead)

GRP4- Disruption of neuronal layer arrangement (red arrow).

GRP 5- Disruption of neuronal layer arrangement (red arrow). Mild area of spongiosis (yellow arrowhead)

GRP 6- Integrity of parenchymatous cells is normal (yellow arrow)

GRP 7- Membrane bound accumulation of blood (black arrow). Areas of spongiosis (yellow arrowhead)

GRP 8 - Fairly normal membrane (black arrowhead). Integrity of parenchymatous cells is normal (yellow arrow)

GRP 9- Areas of mild accumulation of blood (black arrows)

GRP 10- Mildly extended cavernous spaces containing bloody spots (black arrows)

GRP 11- Disruption of neuronal layer arrangement (red arrow). Areas of spongiosis (yellow arrowhead)

Figure 3.2: Histopathology of the head of chicken embryos inoculated with Parvovirus and treated with Lagenaria breviflora whole fruit extract (H&E, X100)

3.3. Histopathology of Embryo Body

The integrity of parenchymatous cells of the embryo body in the uninoculated, untreated embryos was observed to be expected, as shown by prominent cavernous areas filled with embryonic blood. However, the inoculated-untreated embryos showed severe necrosis of parenchymatous cells and prominent cavernous areas filled with embryonic blood. Inoculated and treated embryos with 1.5625mg/ml of LB extract showed mild degeneration of parenchymatous cells. In contrast, prominent cavernous areas filled with embryonic blood and mild degeneration of parenchymatous cells were observed for embryos treated with 3.125 and 6.25 mg/mL, respectively. Nonetheless, the integrity of parenchymatous cells was expected, with a prominent cavernous area filled with embryonic blood in the group inoculated and treated with 12.5mg/ml LB extract. The embryos inoculated and treated with 25 mg/mL LB extract presented mild necrosis of parenchymatous cells and moderate cavernous areas filled with embryonic blood. In addition, embryonic-treated groups with 25 and 50mg/ml LB extract had mild disruption of parenchymatous arrangement and some cell necrosis. Likewise, inoculated and treated embryos with 50mg/ml LB extract showed severe necrosis of parenchymatous cells and prominent cavernous areas filled with embryonic blood. Finally, parenchymatous cell integrity was expected in the group inoculated and treated with 100mg/ml of LB extract (Figure 3.3).

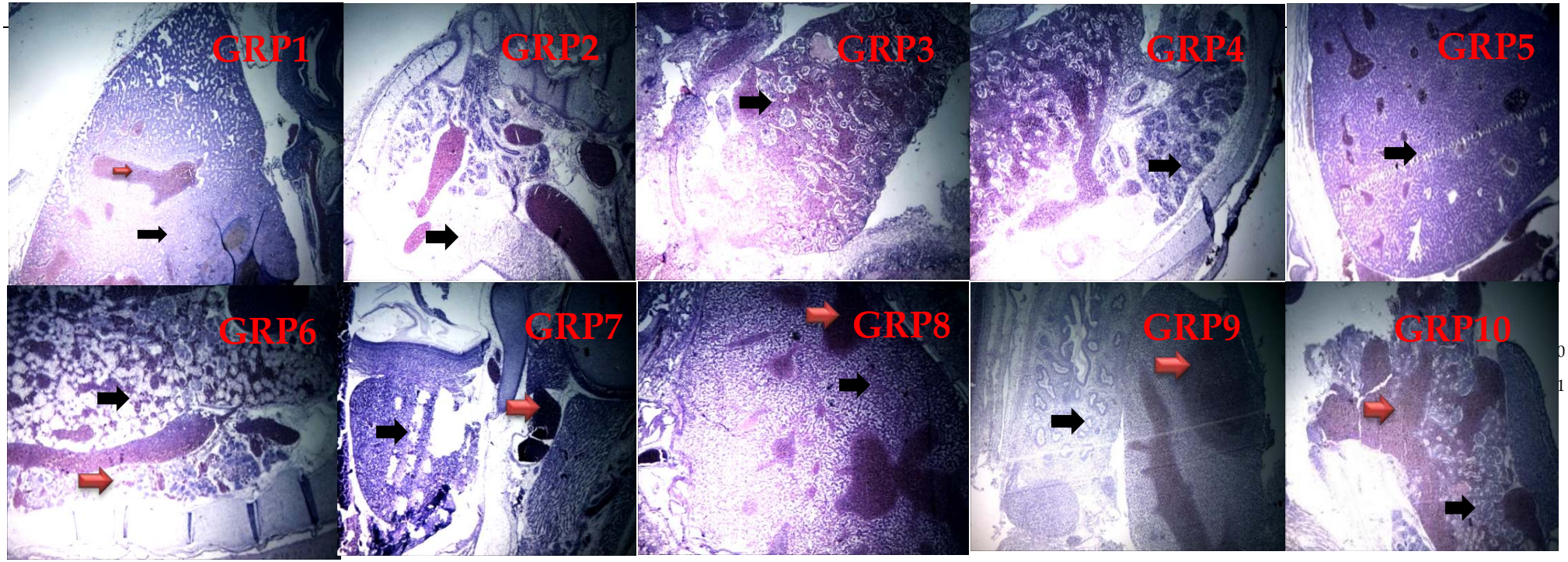

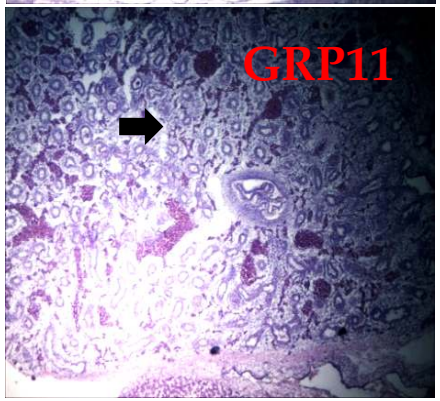

GRP1- Integrity of parenchymatous cells is normal (black arrow). Prominent cavernous areas filled with embryonic blood (red arrow).

GRP 2- Prominent cavernous areas filled with embryonic blood (red arrow). severe necrosis of parenchymatous cells (black arrow)

GRP3 - Mild disruption of parenchymatous arrangement and there is also cell necrosis

GRP4- Mild disruption of parenchymatous arrangement and there is also cell necrosis

GRP 5- Integrity of parenchymatous cells is normal

GRP 6- severe necrosis of parenchymatous cells (black arrow). Prominent cavernous areas filled with embryonic blood (red arrow).

GRP7- mild necrosis of parenchymatous cells (black arrow). Moderate cavernous area filled with embryonic blood (red arrow)

GRP 8 - Integrity of parenchymatous cells is normal (black arrow). Prominent cavernous area filled with embryonic blood (red arow)

GRP 9 -prominent cavernous area filled with embryonic blood (red arrow). mild degeneration of the parenchymatous cells (black arrow)

GRP 10- prominent cavernous area filled with embryonic blood (red arrow), mild degeneration of the parenchymatous cells (black arrow)

GRP 11- mild degeneration of the parenchymatous cells (black arrow)

Figure 3.3: Histopathology of the body of chicken embryos inoculated with Parvovirus and treated with Lagenaria breviflora whole fruit extract (H&E, X100)

3.4. Histopathology of Chorioallantoic Membrane

The uninoculated untreated CAM presented with normal blood vessels connecting the embryo to the yolk. On the other hand, the inoculated untreated embryos showed a copious presence of proteinaceous materials within the membranous spaces. Inoculated embryos treated with 1.5625mg/ml of LB extract revealed a severely necrotic membrane, while inoculated embryos treated with 3.125mg/ml of LB extract showed a degenerated fetal membrane with remnants of clots. There was severe fetal membrane necrosis at 6.25mg/ml and 12.5mg/ml LB in the inoculated-treated embryos. The fetal membrane appeared thickened in the group inoculated and treated with 25mg/ml of LB extract. Embryos inoculated and treated with 50mg/ml of LB extract presented with an intact membrane, a mild presence of proteinaceous materials within the membranous spaces, and mild congestion of blood vessels. However, embryos inoculated with 25mg/ml of LB extract showed thickened fetal membranes and prominent blood vessels, which were congested, while severe necrosis with blood accumulation was observed with 50mg/ml of LB extract. Finally, inoculated embryos treated with 100mg/ml of LB extract showed an intact membrane and mild congestion of blood vessels (Figure 3.4).

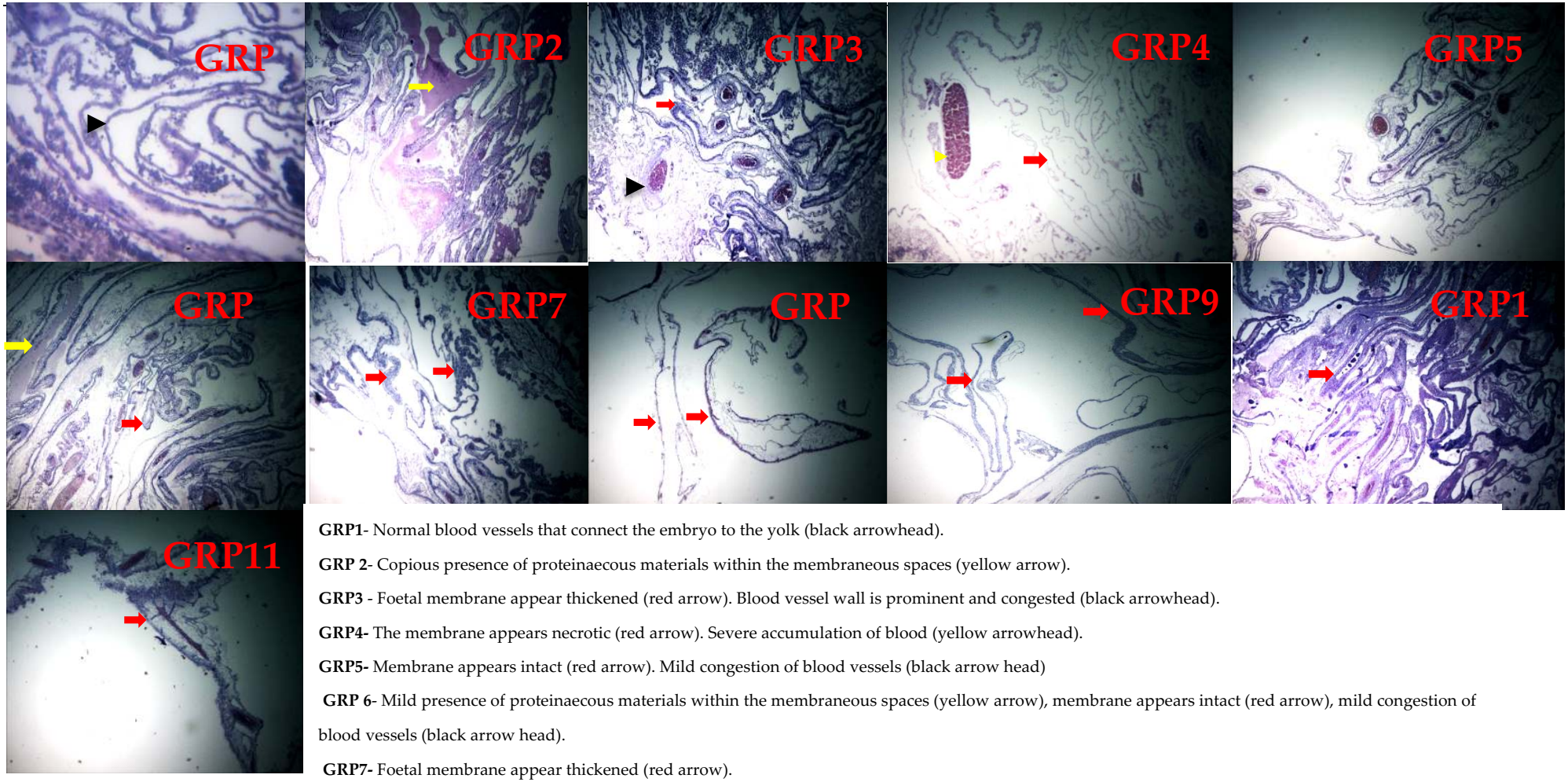

GRP1- Normal blood vessels that connect the embryo to the yolk (black arrowhead).

GRP 2- Copious presence of proteinaecous materials within the membraneous spaces (yellow arrow).

GRP3 - Foetal membrane appear thickened (red arrow). Blood vessel wall is prominent and congested (black arrowhead).

GRP4- The membrane appears necrotic (red arrow). Severe accumulation of blood (yellow arrowhead).

GRP5- Membrane appears intact (red arrow). Mild congestion of blood vessels (black arrow head)

GRP 6- Mild presence of proteinaecous materials within the membraneous spaces (yellow arrow), membrane appears intact (red arrow), mild congestion of blood vessels (black arrow head).

GRP7- Foetal membrane appear thickened (red arrow).

GRP 8 - Foetal membrane appears severely necrotic (red arrow).

GRP 9 - Foetal membrane appears severely necrotic (red arrow).

GRP 10- Foetal membrane appears degenerated with fossils of clots. (red arrow).

GRP 11-): Foetal membrane appears severely necrotic (red arrow).

Figure 3.4: Histopathology of the chorionallantoic membrane of chicken embryos inoculated with *Parvovirus* and treated with *Lagenaria breviflora* whole fruit extract (H&E x100)

4. Discussion

In this study, the methanol extract of *L. breviflora* whole fruit exhibited significant antiviral properties against CPV in embryonated chicken eggs. Notably, the extract inhibited the growth of the virus, leading to reduced cytopathic changes and increased survival rates in treated embryos compared to the untreated infected embryos. These findings indicated the antiviral potential of *L. breviflora* extract, particularly against CPV, which is in agreement with its folkloric antiviral claim [23]. This study further corroborates a previous report of the antiviral activity of the extract demonstrated against Newcastle disease [15].

Canine Parvovirus is recognized for its high contagion and mortality rates in dogs. It causes severe disease characterized by replication in rapidly dividing cells such as bone marrow, lymphoid tissues, and intestinal crypts (24, 25). Typical pathological manifestations of CPE include congestion, haemorrhage, and oedema in infected tissues [26]. This study is in tandem with reported pathological features of CPE, as seen in the untreated infected embryos, which presented with significant lesions and mortality.

However, the observed virus-induced pathologies were prevented in the extract-treated embryos in a dose-dependent manner, aligning with the study by Oridupa *et al.* [15], which demonstrated the antiviral efficacy of ethanol extracts of *L. breviflora* fruit against Newcastle Disease Virus. The lower concentrations inhibited CPV growth and maintained embryo viability, suggesting an optimal therapeutic window for the extract's antiviral activity (3.125-12.5 mg/ml). While the antiviral benefits of *L. breviflora* extract were apparent at lower concentrations, higher concentrations (25-100 mg/ml) introduced toxicity. Embryos exposed to these concentrations showed mild haemorrhage, severe congestion, and significant histopathological changes such as spongiosis, necrosis, and severe neuronal and parenchymatous cell arrangement disruption. These findings are consistent with previous reports by Oridupa *et al.* [15], which highlighted the embryotoxic potentials of various parts of the *Lagenaria breviflora* fruit (100mg/ml). Thus, while the extract is effective at lower doses, its application must be carefully managed to avoid toxic effects.

The gross pathology results in this study indicated that embryos treated with 3.125-12.5 mg/ml of the extract exhibited no haemorrhage and only slight congestion, contrasting sharply with the severe lesions seen in untreated infected embryos. Histopathology of treated embryos showed relatively normal membranes and mildly degenerated parenchymatous cells, further substantiating the protective effect of the extract at these concentrations. Conversely, higher doses (25-100 mg/ml) resulted in moderate to severe virus-induced damage, reinforcing the necessity for dose optimization.

This study demonstrates a notable antiviral activity of *L. breviflora* whole fruit methanol extract against CPV, particularly at concentrations of 3.125, 6.25 and 12.5 mg/ml, effectively inhibited viral growth and mitigated virus-induced damage in embryonated chicken eggs infected with canine parvovirus. This aligns with previous findings on its efficacy against other viral pathogens. The potential of the extract as an antiviral agent is evident, provided that its application is carefully regulated to mitigate associated toxicities.

5. Conclusions

The findings of this study suggest that *L. breviflora* extract holds promise as an antiviral agent against canine parvovirus and for the treatment of enteritis, with significant efficacy observed at lower concentrations. However, the observed toxicity at higher doses necessitates further investigation for the safe therapeutic range and mechanisms underlying both the antiviral and toxic effects. Future research should also explore the specific active compounds within the extract responsible for these effects, potentially leading to more refined antiviral therapies..

Author Contributions: Conceptualization, Olayinka Oridupa and Olusegun Fagbogun; methodology, Blessing Ayeni and Olusegun Fagbohun; software and Imaging, Oluwasanmi Aina.; validation, Olawale Olawumi Ola, Oluwasanimi Aina and Olusegun Fagbohun; investigation, Blessing Ayeni, Olawale Ola.; resources, Tolulope Olakojo; writing—original draft preparation, Tolulope Olakojo.; writing—review and editing, Tolulope Olakojo , Olayinka Oridupa, Oluwasanmi Aina and Olusegun Fagbohun.; visualization, Oluwasanmi Aina, Olawale Ola.; supervision, Olayinka Oridupa; project administration, Blessing Ayeni.

All authors have read and agreed to the published version of the manuscript.

Funding: This research received no external funding

Institutional Review Board Statement: Not applicable.

Acknowledgments: We acknowledge the support of the entire members of technical staff of the Virology Laboratory of the Department of Veterinary Microbiology, Histology unit of Veterinary Anatomy Laboratory and Histopathology unit of Veterinary Pathology, University of Ibadan for their support all through this research.

Conflicts of Interest: The authors declare no conflict of interest.

References

1. Qi, S.; Zhao, J.; Guo, D.; Sun, D. A mini-review on the epidemiology of canine parvovirus in China. Front Vet Sci. **2020**, 7, 5.
2. Ogbu, K.I.; Chukwudi, I.C.; Mira, F.; Eze, U.U.; Di Bella, S.; Olaolu, O.S.; Tion, M.T.; Purpari, G.; Cannella, V.; Nwosuh, I.C.; Guercio, A.; Anene, B.M. Current status and risk factors of canine parvovirus type 2 in North Central Nigeria. Comp Immunol Microbiol Infect Dis. **2021**, 74.
3. Sykes, J.E. Immunization. In: Greene's Infectious Diseases of the Dog and Cat. Elsevier, **2021**; pp. 238–55.
4. Cotmore, S.F.; Tattersall, P. Parvoviruses: small does not mean simple. Annu Rev Virol. **2014**, 1, 517–37.
5. Pénzes, J.J.; Söderlund-Venermo, M.; Canuti, M.; Eis-Hübinger, A.M.; Hughes, J.; Cotmore, S.F.; Harrach, B. Reorganizing the family Parvoviridae: a revised taxonomy independent of the canonical approach based on host association. Arch Virol. **2020**, 165, 2133–46.
6. Fagbohun, O.A.; Omobowale, T.O. Sequence and phylogenetic analysis of canine parvovirus-2 isolates in dogs revealed circulation of three subtypes in Nigeria. Virusdisease. **2018**, 29, 411–5.
7. Larson, L.J.; Schultz, R.D. Canine and feline vaccinations and immunology. Infectious disease management in animal shelters. **2021**, 191–220.
8. Afumba, R.; Liu, J.T.; Dong, H. Apoptosis mechanisms induced by parvovirus infections. Acta Virologica **2022**, 66(2), 101-109
9. Mazzaferro, E.M. Update on canine parvoviral enteritis. Veterinary Clinics: Small Animal Practice. **2020**, 50(6), 1307–25.
10. Kelman, M.; Ward, M.P.; Barrs, V.R.; Norris, J.M. The geographic distribution and financial impact of canine parvovirus in Australia. Transbound Emerg Dis. **2019**, 66(1), 299–311.
11. Kelman, M.; Barrs, V.R, Norris, J.M.; Ward, M.P. Canine parvovirus prevention and prevalence: Veterinarian perceptions and behaviors. Prev Vet Med. **2020,** 174, 104817.
12. Pandit, M.; Latha, N. In silico studies reveal potential antiviral activity of phytochemicals from medicinal plants for the treatment of COVID-19 infection. PREPRINT (Version 1) available at Research Square [https://doi.org/10.21203/rs.3.rs-22687/v1] (14 April 2020)

13. Adamson, C.S.; Chibale, K.; Goss, R.J.M.; Jaspars, M.; Newman, D.J.; Dorrington, R.A. Antiviral drug discovery: preparing for the next pandemic. Chem Soc Rev. **2021**, 50(6), 3647–55.
14. Renner, S.S.; Schaefer, H. Phylogeny and evolution of the Cucurbitaceae. Genetics and genomics of Cucurbitaceae. **2017**, 13–23.
15. Oridupa, O.A.; Saba, A.B.; Sulaiman, L.K. Preliminary report on the antiviral activity of the ethanolic fruit extract of Lagenaria breviflora Roberts on Newcastle disease virus. Tropical Vet. **2011**, 29(1), 22–33.
16. Adedapo, A.A.; Adewuyi, T.; Sofidiya M. Phytochemistry, anti-inflammatory and analgesic activities of the aqueous leaf extract of Lagenaria breviflora (Cucurbitaceae) in laboratory animals. Rev Biol Trop. **2013**, 61(1), 281–90.
17. Onasanwo., SA.; Singh, N.; Saba, A.B.; Oyagbemi, A.A.; Oridupa, O.A.; Palit, G. Anti-ulcerogenic and in vitro antioxidant activities of Lagenaria breviflora (LB) whole fruit ethanolic extract in laboratory animals. Pharmacognosy Res. **2011**, 3(1), 2-8
18. Ekunseitan, D.A.; Ayoola, A.A.; Jimoh, S.A.; Adegoke, T.O.; Adeniran, K.A. Resposta das aves à administração aquosa de extrato de abóbora manchada. Archivos de zootecnia. **2019**, 68(262), 214–9.
19. Oridupa, O.; Saba, A. Relaxant effect of *Lagenaria breviflora* Roberty fruit pulp and seeds on isolated rabbit ileum. Sokoto Journal of Veterinary Sciences. **2013**, 11(2), 21-27
20. Sobotka, P.; Przychodzki, M.; Uściło, K.; Woliński, T.R.; Staniszewska, M. Effect of ultraviolet light C (UV-C) radiation generated by semiconductor light sources on human beta-coronaviruses' inactivation. Materials. **2022**, 15(6), 2302.
21. Ribatti, D. The chick embryo chorioallantoic membrane (CAM) assay. Reproductive toxicology. **2017**, 70, 97–101.
22. Jedelska, J.; Strehlow, B.; Bakowsky, U.; Aigner, A.; Hoebel, S.; Bette, M.; Roessler, M.; Franke, N.; Teymoortash, A.; Werner, J.A.; Eivazi, B.; Mandic, R. The chorioallantoic membrane assay is a promising ex vivo model system for the study of vascular anomalies. In Vivo (Brooklyn). **2013**, 27(6), 701–5.
23. Saba, A.B.; Oridupa, O.A.; Oyagbemi, A.A.; Alao, E.O. Serum biochemical changes accompanying prolonged administration of ethanolic extract of whole fruit of Lagenaria breviflora (Benth) Roberty in Wistar rats. Afr J Biotechnol. **2010**, 9(42), 7128–33.
24. Parrish, C.R.; Sykes, J.E. Canine parvovirus infections and other viral enteritides. In: Greene's Infectious Diseases of the Dog and Cat. Elsevier: 2021; pp. 341–351.
25. Tuteja, D.; Banu, K.; Mondal, B. Canine parvovirology–A brief updated review on structural biology, occurrence, pathogenesis, clinical diagnosis, treatment and prevention. Comp Immunol Microbiol Infect Dis. **2022**, 82, 101765.
26. Fagbohun, O.A.; Jarikre, T.A.; Alaka, O.O.; Adesina, R.D.; Ola, O.O.; Afolabi, M.; Oridupa, O.A.; Omobowale, T.O.; Emikpe, B.O. Pathology and molecular diagnosis of canine parvoviral enteritis in Nigeria: case report. Comp Clin Path**.** **2020**, 29, 887–93.